



Case report

A giant adenomatoid odontogenic tumor of the mandible: A case report and literature review

Nguyen Quang Duc^a, Vu Ngoc Lam^{a,*}, Nguyen Phuong Tien^a, Ngo Thi Minh Hanh^b,
Vu Dang Hai Dang^a

^aCenter for Craniofacial and Plastic Surgery, 108 Military Central Hospital, No 1 Tran Hung Dao street, Ha Noi, Viet Nam

^bDepartment of Pathology, 108 Military Central Hospital, No 1 Tran Hung Dao street, Ha Noi, Viet Nam

ARTICLE INFO

Keywords:

Adenomatoid odontogenic tumor
Mandibular
Fibula flap
Case report

ABSTRACT

Introduction and importance: An adenomatoid odontogenic tumor is a rare medical condition. Large tumor (or several) often appears in the maxillae. In a minority of cases, the tumor(s) appear in the mandible.

Case presentation: We report on a case of a 24-year-old female diagnosed with a mandibular adenomatoid odontogenic tumor, a giant tumor measuring approximately 22 × 25 × 17 cm. The tumor was located on the side of the mandible, causing facial deformity, malnutrition, and hemorrhaging. We assessed the patient's overall condition, carried out a resection of the tumor and mandible from the right condyle to the left mandibular angle, and reconstructed the mandibular defect with a fibula free flap. After the treatment, the patient was followed up for 1 year, with no recurrence detected over this period.

Clinical discussion: Because adenomatoid odontogenic tumors are benign odontogenic lesions, which are painless and slow-growing, most are surgically removed or treated conservatively. However, the above treatment measures cannot be applied in the case of a giant tumor that causes facial deformity, destroys the entire jawbone, and has complications such as hemorrhaging and malnutrition. After the tumor resection, the defect is still significant. Accordingly, reconstruction using a microsurgical bone flap is an effective method instead.

Conclusion: Large adenomatoid odontogenic tumors in the mandible are rare, and treatment cannot follow conventional methods. Accordingly, defect reconstruction after tumor resection is essential.

1. Introduction

Adenomatoid odontogenic tumors (AOT) were first described by Harbitz more than 100 years ago as “cystic adamantinoma.” It was then given various names until 1969 when the World Health Organization (WHO) accepted the term “Adenomatoid Odontogenic Tumor” as proposed by Philipsen and Birn [1]. The WHO defines it as a tumor composed of dentin-forming epithelium with various tissue architecture patterns located within a mature connective tissue stroma. The tumor is also characterized as slow-growing [2].

The AOT is the fourth most common odontogenic tumor, accounting for 2–7 % of cases [3,4]. It is also known as a ‘two-thirds tumor’ because the tumor in the maxillae accounts for two-thirds of cases, the tumor occurs in young women in about two-thirds of cases, two-thirds of cases are related to the canines, and up to two-thirds of cases impact the teeth [5].

An AOT is usually small, with a diameter of 1–3 cm [6], and tumors

are treated by surgical resection. In 2015, the author Munandar reported a case of an AOT in the mandible sized 14 × 10 × 10 cm, which was the largest tumor we found in the literature [7]. The tumor was surgically removed and monitored for recurrence, without reconstruction of the defected bone. The authors suggested that with the small tumor size and the slow-growing and benign nature of an AOT, surgical treatment is often simple and can be conservative. We report on a rare case where the AOT in the mandible was enormous and so was surgically resected, with the mandible successfully reconstructed.

This case report has been reported in line with the SCARE 2020 Criteria [8].

2. Presentation of case

A 24-year-old Asian patient (Fig. 1) was referred to the Central for Craniofacial and Plastic Surgery - 108 Central Military Hospital presenting an enormous tumor in the low third of the right face. The patient

* Corresponding author.

E-mail address: vungoclamb8@gmail.com (V.N. Lam).

<https://doi.org/10.1016/j.ijscr.2022.107295>

Received 11 May 2022; Received in revised form 31 May 2022; Accepted 7 June 2022

Available online 10 June 2022

2210-2612/© 2022 The Authors. Published by Elsevier Ltd on behalf of IJS Publishing Group Ltd. This is an open access article under the CC BY-NC-ND license (<http://creativecommons.org/licenses/by-nc-nd/4.0/>).

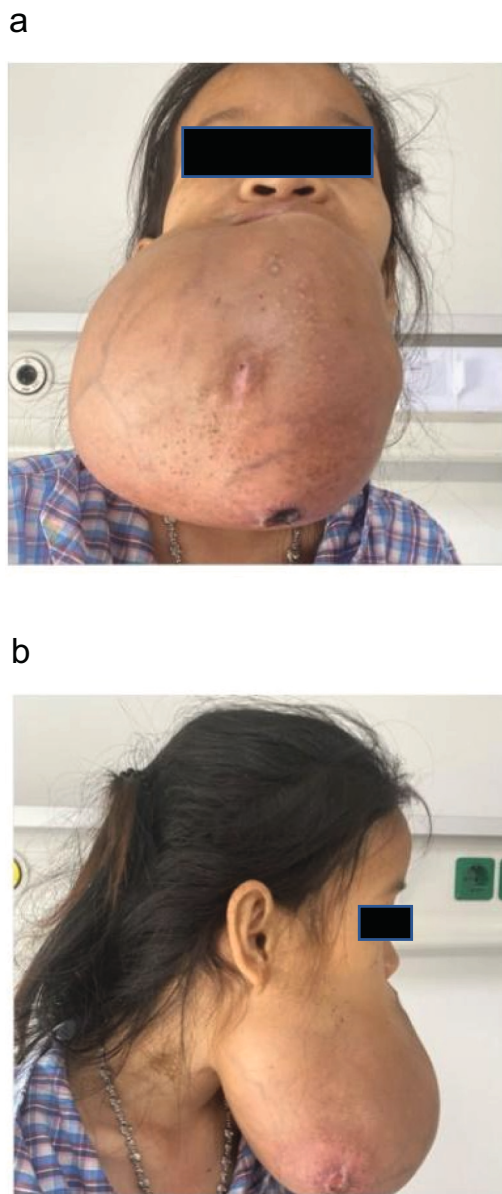

Fig. 1. The patient pre-op (a) anterior, (b) lateral.

and family members have no previous medical records. The tumor gradually enlarged over five years, affecting the patient's daily activities, though it was painless. Recently, fistulas developed in the oral mucosa and the covering skin, with thin black discharge. The overall condition of the patient was weak and malnourished. Clinical examination showed no palpable cervical lymph nodes; the tumor measured approximately 22 × 25 × 17 cm, progressively growing outside the skin and inside the oral mucosa and malocclusion. On palpation, the skin surface was thin and tight, and the tumor shell soft and concave when pressed.

The tumor was so large that a panoramic film could not be taken. On

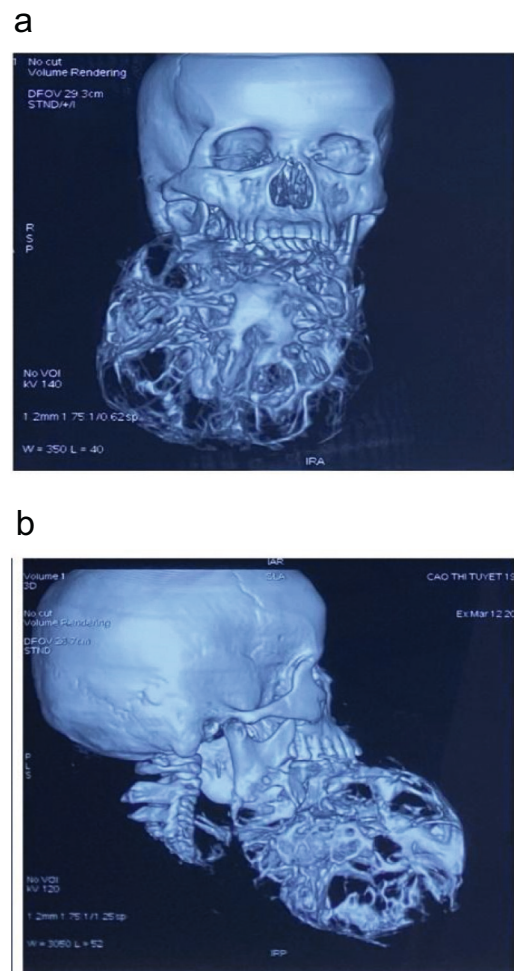


Fig. 2. CT-Scan pre-op (a) anterior, (b) lateral.

the CT-Scanner (Fig. 2), the tumor started from the right side of the sigma fossa to the left mandible angle. It looked like a spherical root ball, divided into many compartments and the mandible's boundary was indistinguishable. The teeth were crooked, causing malocclusion. Pre-operation histology indicated an adenomatoid odontogenic tumor. The patient's malnourished condition meant surgery was not safe, so their diet was adjusted accordingly. We performed surgical resection of the entire tumor and mandible from the right condyle to the left mandible angle when the overall condition made this allowable. Reconstructive surgery was performed immediately using the free fibula skin flap.

Nasal endotracheal anesthesia was also performed, using a soft endoscope to place the intubation tube through the nostrils. There were two surgical teams operating in parallel. Team 1 (head and neck surgeons) removed the tumor and prepared the receiving vessel. The external incision was parallel to the inferior border of the mandible, and the intraoral incision cut the damaged mucosa from the right cheek to the left mandibular vestibular recess. Resection of the entire tumor (Fig. 3), periosteum and mandibular bone to the posterior of tooth 3.8 was carried out. Dissection revealed the right facial vein and the right

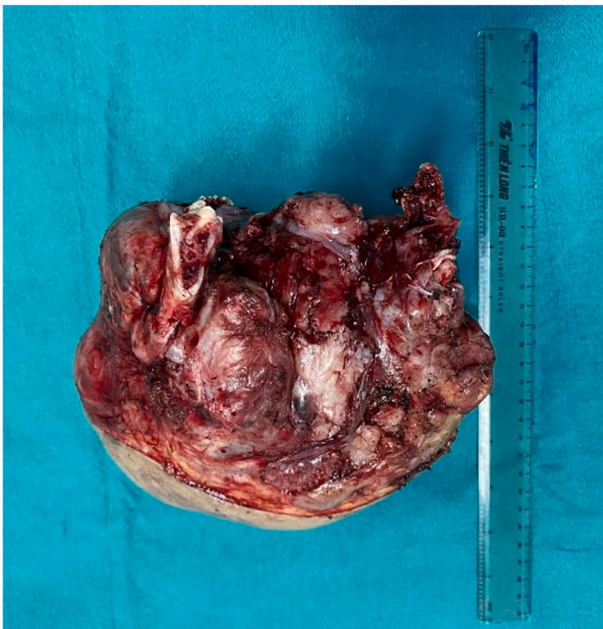

Fig. 3. The tumor 22 × 25 × 17 cm.

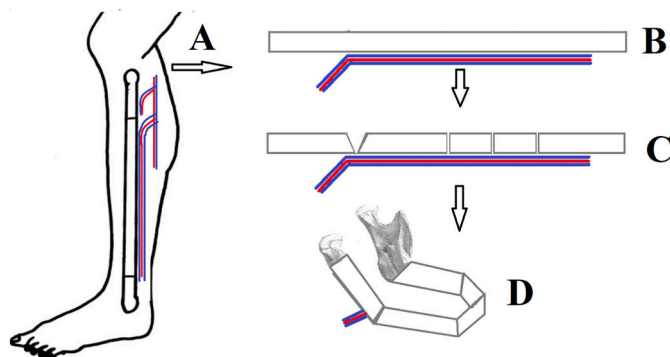


Fig. 4. The reconstruction of the mandibular with the fibula flap. A: The donor site of the fibula free flap on the left leg. B: Fibula free flap and peroneal artery and vein. C: Fibula free flap after cut into 5 segments. D: The mandibular after being reconstructed.

external jugular vein. Team 2 (plastic surgeons) dissected the fibula skin-free flap and reconstructed the mandible. The bone flap was divided into five segments (Fig. 4): right ascending branch, right transverse branch, right mental region, left mental region and left transverse branch. The secondary defect was sutured directly to ensure negative pressure. The fibula skin-free flap was used to recreate the mandible defect with the mandibular reconstruction plate. We anastomosis the flap artery to the right facial artery, and two flap veins with the facial veins and the external jugular. The skin flap was sutured outwards to use as a monitor flap. The surgery lasted for 7 h.

The patient had the histology of an adenomatoid odontogenic tumor (Fig. 5).

Macroscopically: The upper pole of the tumor is attached to the whole mandible with related teeth, and has large areas of bone resorption. The contralateral side of the tumor is covered with skin but does not infiltrate the subcutaneous tissue. Cut through, the tumor has many cystic cavities containing dilute blood and mucus. The cystic walls have different thicknesses that show pinkish-gray areas, light yellow areas, and many hard areas like bones.

Microscopically: Histopathological examination revealed predominant duct-like structures with intercalated strands of epithelium forming trabecular anastomosing lamina-like cords in a plexiform pattern and basophilic cells with fusiform nuclei and forming whorled nodules. Duct-like structures were lined with cuboidal odontogenic epithelial cells and small, fine oval nuclei, and rare mitosis. In some other areas, calcified material included areas showing a nodular of eosinophilic epithelial that were presented like well-bordered squamous cells in an enamel matrix. An immunohistochemistry stain showed odontogenic epithelial cells were positive with CKAE1/AE3 and CK19 both in adenomatoid, nodular areas and negative Bcl-2, p53. The Ki67 proliferative index was about 2 % in the hot spot area.

Post-operation, the fibula skin-free flap was in great condition, and the patient was discharged from the hospital after 11 days of treatment. After follow-up for 1 year (Figs. 6-7), the face was still balanced, and the tumor had no recurrence. We are planning to remove the fixator plate and restore the teeth with implants.

3. Discussion

An AOT is a rare benign odontogenic lesion, which is slow-growing and non-invasive. It is referred to as a ‘two-thirds tumor’ since the occurrence in the maxillae is usually high and mostly in young women (about two-thirds of cases). Our patient is a young female with a large tumor located in the mandible. Giant tumors in the mandible are extremely rare [9].

An AOT has three clinicopathological variants with different X-ray images: Follicular; Extrafollicular; Peripheral (Fig. 8). Our case was an enormous tumor, which the X-ray image could not characterize due to its size and the destruction of the mandible. The patient’s radiographic images could not be identified as an AOT or ameloblastoma. However, despite being such a large tumor with so much destruction, the indications for surgical resection of the tumor and mandible were reasonable for all histopathological diagnoses.

As a characteristic of the tumor is that it is usually small, progresses slowly, and rarely recurs or becomes malignant, surgical treatment is often favorable. The main method is surgical enucleation or curettage. However, with large tumors, after surgical treatment, it is important to ensure the stability of the mandible to avoid complications of secondary fractures or face deformities and to facilitate dental restoration. Reviewing the literature (Table 1), we found reports of mandibular AOT that showed the largest size to be 14x10x10cm [7]; this patient was diagnosed with the disease 4 years before going to treatment. After the tumor resection, the author used a 12-hole Titan brace and three screws to fix it to the mandible to enhance stability. After a 1-year follow-up, no recurrence was detected, and the Titan brace was removed. Our patient discovered the tumor 5 years ago before going to treatment, and the tumor was so large that the entire mandible was nearly destroyed, the function of the lower teeth was lost, and the mandible could no longer be preserved. We suggested that the mandibular segment containing the tumor be resected and reconstructed immediately with a free flap. Large tumors are often formed at advanced stages due to delays in treatment

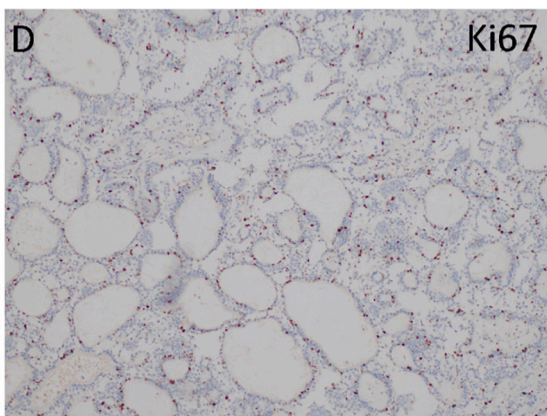
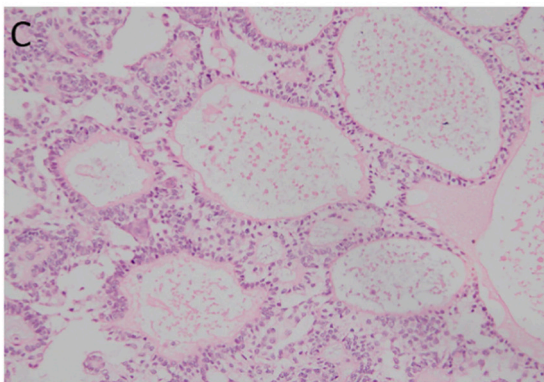
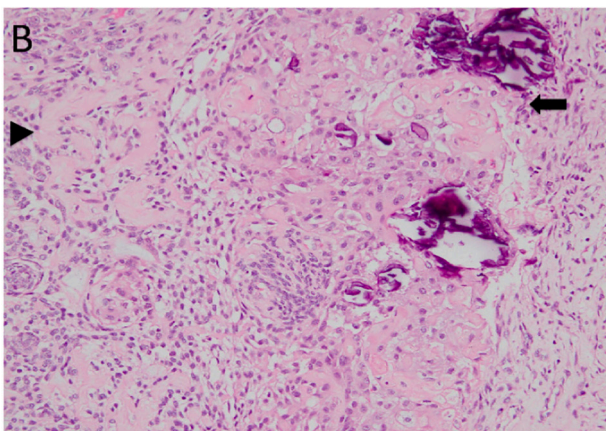
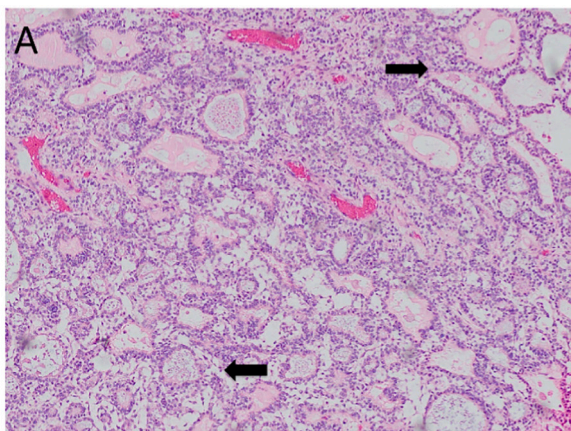


Fig. 5. Histological and immunohistochemistry images. Hematoxylin-Eosin stain. a. Tumor structure mainly includes duct-like patterns of the odontogenic epithelial cell (arrow) (100×). b. In other places, amorphous calcifications, dentinoid-like material (arrow); strands of epithelial cells intercalated with deposition of eosinophilic material resembling tumor amyloid (head arrow) (200×); c. Duct-like structure lined odontogenic epithelial cell with cuboidal shape and small, fine oval nuclei (200×); d. Immunohistochemistry image, odontogenic epithelial cells proliferate, showing about 2 % positive with Ki67 in the hot spot area (100×).

[10]. Our patient was homeless and without a stable job, so there were no opportunities for early treatment. It was only when the tumor was too large, severely affecting the quality of life and causing physical weakness, that social organizations were able to help the patient to be treated.

3.1. Histology

An AOT belongs to the group of odontogenic tumors that are benign [17]. The tumor was formerly known as adenomeblastoma. Tumors are often differentiated from dentinogenesis cysts and odontogenic cysts, which are usually small in size. In terms of histological characteristics, an AOT has its own characteristics that rarely need to be distinguished from ameloblastoma. The WHO has described the distinct histopathological characteristics of such tumors as showing duct-like structures. Our case markedly presents this pattern. Calcium dystrophy in varying amounts and forms is commonly seen in most AOTs. Atypical epithelial cells and mitotic activity are not expressed. The Ki67 proliferation index is low. Because the tumor has an epithelium origin, most of the adenoid epithelial cells are positive for epithelial antibodies such as CK, CKAE1/AE3, CK5, CK14, and CK19 [18].

3.2. Reconstruction of the mandibular

Although the tumor was large, causing deformation of the mandibular, it was growing into the oral cavity, which made anesthesia a challenge. We used a soft endoscope to guide the intubation tube. The patient was in an intensive care unit for 1 day and had the intubation tube removed successfully. As the tumor had been completely removed, there was no longer need for insertion into the trachea, and swelling of the oral floor was sufficiently limited that the patient could breathe on her own early on.

Reconstruction of lesions in patients with large tumors is a major challenge, and only using a free bone flap can provide enough volume of reconstructive material. The fibula free flap is chosen in mandibular reconstruction because of its advantages over other free bone flaps such as the iliac crest, shoulder blade, rib, etc. The fibula free flap can obtain a large amount of bone, and the fibula can be divided into segments to suit different shapes without affecting nutrition, as the flap can be taken as a combination of bone-skin or musculoskeletal-skin to recreate complex defects. [19–21]. Currently, the fibula free flap is the first choice in reconstructing large mandibular defects. We used the fibula free flap to reconstruct the mandible for the patient. However, due to the very wide mandibular defect from below the right condyle to the front of the 3.8 tooth, the fibula flap was not long enough to perform the double barrel technique.

After a follow-up of 1 year, the patient’s face is still balanced, and there has been no recurrence of the tumor. The mobility of the patient’s mandibular is normal, but the ability to speak, swallow and chew has not been restored due to difficulties in dental restoration. The patient has no restrictions on leg mobility at the donor site.

4. Conclusion

Although an AOT can be seen in the mandible, this is a very rare case of an enormous AOT, and the treatment was not conducted according to the usual methods. In this case, immediate reconstruction of the bone

(caption on next column)

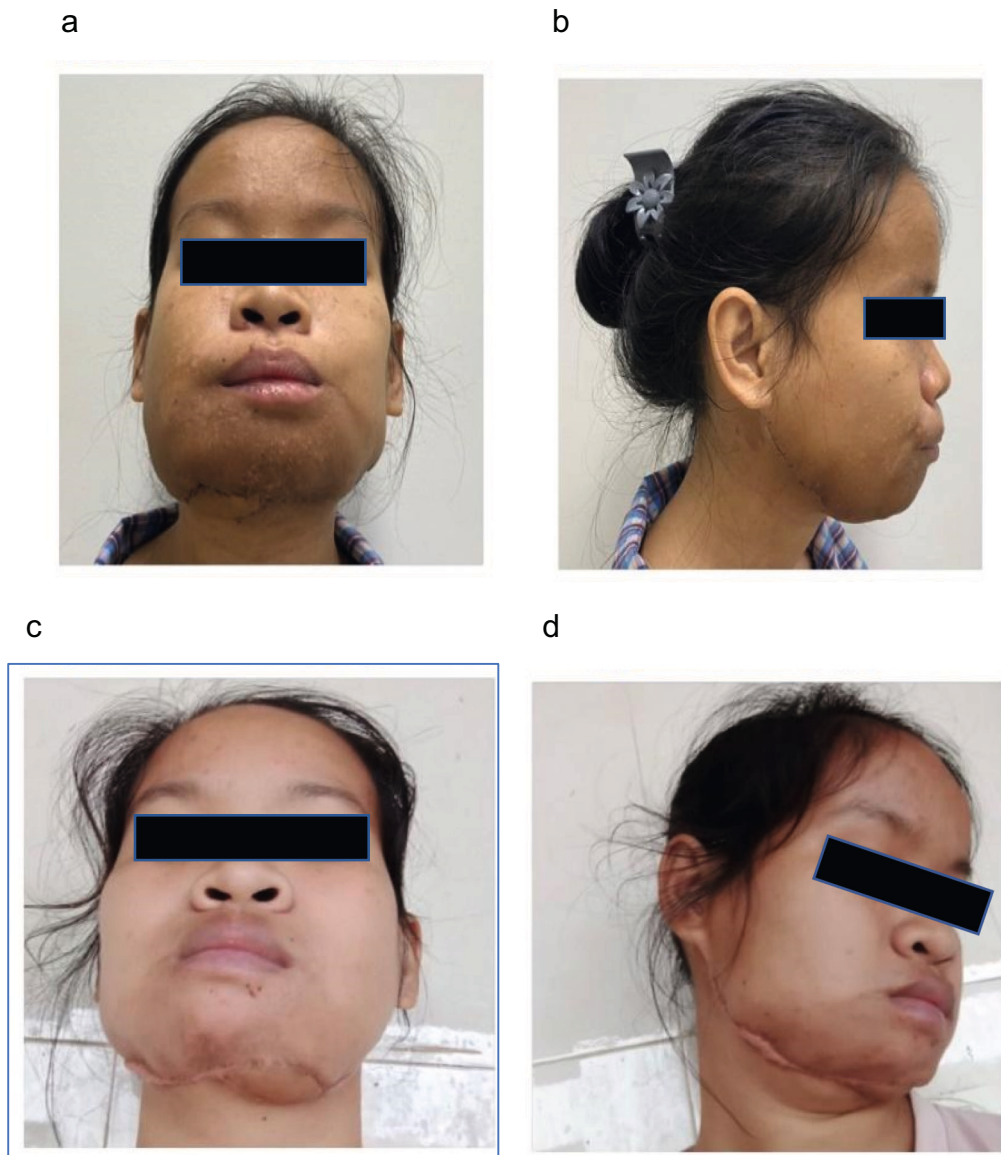

Fig. 6. Pictures of patient post-op 1 week (a) anterior, (b) lateral; post-op 10 months (c) anterior, (d) lateral.

defect was required after excision.

Summary table

- This report shows the case of an enormous adenomatoid odontogenic tumor in the mandible.
- A different approach with mandibular amputation and reconstruction using the fibula free flap was successful.

Provenance and peer review

Not commissioned, externally peer-reviewed.

Sources of funding

This research received no specific grant from any funding agency in public, commercial or non-profit sectors.

Ethical approval

Ethical Approval was obtained from institutional review board of local faculty and the participating hospital.

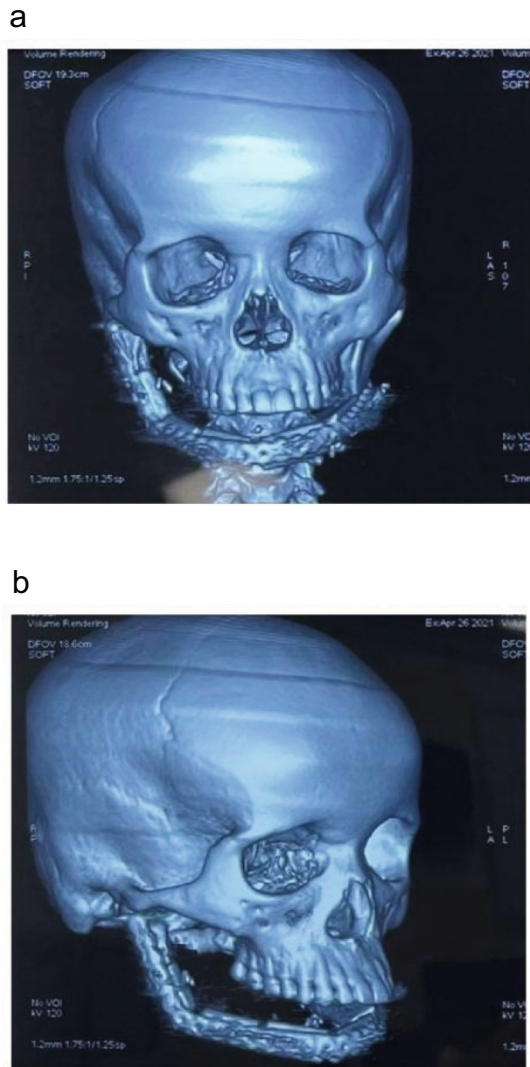


Fig. 7. CT-scan post-op (a) anterior, (b) lateral.

Consent

Written informed consent was obtained from the patient for publication of this case report and accompanying images. A copy of the written consent is available for review by the Editor-in-Chief of this journal on request.

Author contribution

Nguyen Quang Duc, Ph.D, M.D.: Study concept, data collection, data analysis and write the paper.
 Vu Ngoc Lam, Ph.D, M.D.: Study concept, data collection, data analysis and write the paper.
 Nguyen Phuong Tien, M.D.: Study concepts and write the paper.
 Ngo Thi Minh Hanh Ph.D, M.D.: Study concepts and write the paper.

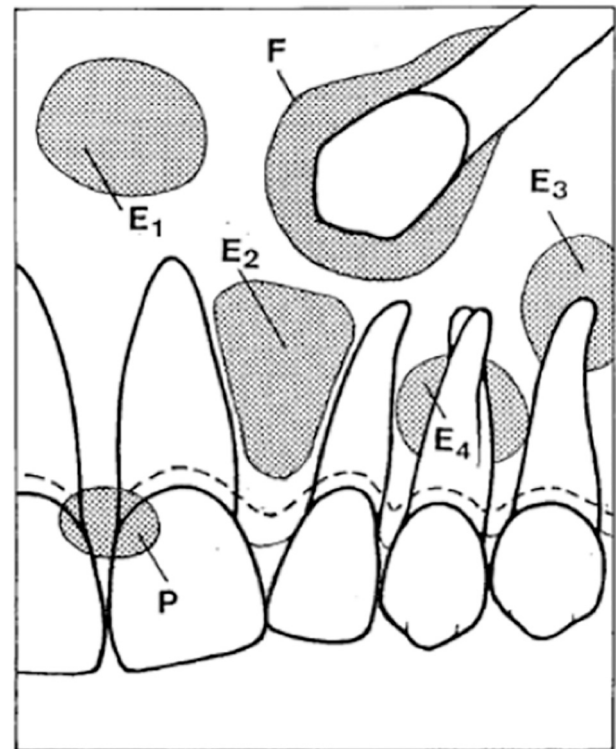


Fig. 8. Radiographic appearance of AOT variants. F, Follicular type; the tumor is located around the crown and often, as shown here, including part of the root of an unerupted tooth (envelopental). E1-E4, extrafollicular types: E1, without relation to tooth structures either erupted or unerupted; E2, interdicular; adjacent roots diverge apically as a result of tumor expansion (mimicking a “globulo-maxillary” cyst); E3, superimposed on root at apex level (mimicking a radicular cyst); E4, superimposed at midroot level. P, peripheral or epulis type (with slight erosion or “saucerization” of bone crest).

Vu Dang Hai Dang, M.D.: Study concepts and write the paper.

Research registration

UIN: researchregistry7952.
<https://www.researchregistry.com/browse-the-registry#home/registrationdetails/628f131925f3c1001ea45f59/>.

Guarantor

Nguyen Quang Duc, Ph.D, M.D.
 Vu Ngoc Lam, Ph.D, M.D., Assoc. Prof.

Declaration of competing interest

All authors declare no conflict of interest.

Table 1

Adenomatoïd odontogenic tumors of the mandible as reported in the literature.

Author	Year	Age	Sex	Course	Tumor size	Treatment; reconstruction
Nomura et al. [11]	1992	64	Male	2 years	5 × 3.5 cm	En bloc resection
Khot et al. [12]	2011	17	Female	2 years	7x15cm	Surgical curettage
Narayan et al. [13]	2013	17	Female	6 months	7x5cm	Surgical enucleation
Saluja et al. [14]	2013	17	Male	1 year	2x3cm	Surgical enucleation
Munadar et al. [7]	2015	15	Female	4 years	14x10x10cm	Surgical enucleation titanium plate
Shaikh, et al. [15]	2018	24	Female	1 month	6.5 × 3.5 cm	Surgical enucleation
Fujita et al. [16]	2021	31	Male		3.7 × 2.7 × 1.8 cm	Surgical enucleation
Duc et al.	2022	24	Female	5 years	22 × 25 × 17 cm	Mandibular amputation fibula free flap

References

- [1] H.P. Philipsen, P. Khongkhunthiang, P.A. Reichart, The adenomatoïd odontogenic tumour: an update of selected issues, *J. Oral Pathol. Med.* 45 (6) (2016 Jul) 394–398.
- [2] L. Barnes, J. Eveson, P. Reichart, D. Sidransky, World Health Organization Classification of Tumours: Pathology and Genetics of Head and Neck Tumours [Internet]. 3rd ed. Vol. 9. World Health Organization Classification of Tumours; Available from: <https://screening.iarc.fr/doc/BB9.pdf>.
- [3] H. Suzuki, K. Hashimoto, Adenomatoïd odontogenic tumour of the maxilla: immunohistochemical study, *Asian J. Oral. Maxillofac. Surg.* 17 (4) (2005 Dec 1) 267–271.
- [4] B. Sangalette, T. Emidio, M. Capelari, C. Pastori, G. Toledo, Surgical therapy for removal of adenomatoïd odontogenic tumor, *Hum. Pathol. Case Rep.* 1 (20) (2020 Jun), 200366.
- [5] H.P. Philipsen, P.A. Reichart, Adenomatoïd odontogenic tumour: facts and figures, *Oral Oncol.* 35 (2) (1999 Mar) 125–131.
- [6] J.B. John, R.R. John, Adenomatoïd odontogenic tumor associated with dentigerous cyst in posterior maxilla: a case report and review of literature, *J. Oral Maxillofac. Pathol.* 14 (2) (2010) 59–62.
- [7] A. Munandar, E. Syamsudin, M. Sylviana, K.A. Rizki, A rare case of massif adenomatoïd odontogenic tumor in the anterior region of mandible: Mimicking as dentigerous cyst | Munandar, Available from, *Padjadjaran Journal of Dentistry* (2022 Apr 15), <http://jurnal.unpad.ac.id/pjd/article/view/13561>.
- [8] R.A. Agha, T. Franchi, C. Sohrabi, G. Mathew, for the SCARE Group, The SCARE 2020 guideline: updating consensus Surgical Case Report (SCARE) Guidelines, *Int J Surg.* 84 (2020 Dec 1) 226–230.
- [9] K. Takahashi, T. Yoshino, S. Hashimoto, Unusually large cystic adenomatoïd odontogenic tumour of the maxilla: case report, *Int. J. Oral Maxillofac. Surg.* 30 (2) (2001 Apr) 173–175.
- [10] A. Mohamed, A.S. Singh, E.J. Raubenheimer, M.M.R. Bouckaert, Adenomatoïd odontogenic tumour: review of the literature and an analysis of 33 cases from South Africa, *Int. J. Oral Maxillofac. Surg.* 39 (9) (2010 Sep) 843–846.
- [11] M. Nomura, K. Tanimoto, T. Takata, T. Shimosato, Mandibular adenomatoïd odontogenic tumor with unusual clinicopathologic features, *J. Oral Maxillofac. Surg.* 50 (3) (1992 Mar) 282–285.
- [12] K. Khot, P.A. Vibhakar, Vibhakar “Case report: mural adenomatoïd odontogenic tumor in the mandible—a rare case, *Int. J. Oral. Maxillofac. Pathol.* (2011) 35–39.
- [13] V.S. Narayanan, G. Naidu, R. Ragavendra, S. Mhaske-Jedhe, M. Haldar, Adenomatoïd odontogenic tumor of the mandible with unusual radiographic features: a case report, *Imaging Sci. Dent.* 43 (2) (2013 Jun) 111–115.
- [14] R. Saluja, G. Kaur, P. Singh, Aggressive adenomatoïd odontogenic tumor of mandible showing root resorption: a histological case report, *Dent. Res. J.* 10 (2) (2013 Mar) 279–282.
- [15] S. Shaikh, S. Bansal, R.S. Desai, I. Ahmad, Aggressive adenomatoïd odontogenic tumor of the mandible: a rare case report and review of the literature, *J. Oral Maxillofac. Pathol.* 22 (Suppl 1) (2018 Jan) S11–S15.
- [16] A. Fujita, Y. Ueyama, H. Nagatsuka, H. Kawamata, A case of large adenomatoïd odontogenic tumor in the posterior region of the mandible showing root resorption, *J. Oral Med. Oral. Surg.* 27 (2) (2021) 19.
- [17] J.E. Leon, G.M. Mata, E.R. Fregnani, R. Carlos-Bregni, O.P. de Almeida, A. Mosqueda-Taylor, P.A. Vargas, Clinicopathological and immunohistochemical study of 39 cases of adenomatoïd odontogenic tumour: a multicentric study, *Oral Oncol.* 41 (8) (2005 Sep) 835–842.
- [18] Sempere FJV, Martinez MJA, BV Sirera JB, Marco n.d. Follicular adenomatoïd odontogenic tumor: immunohistochemical study. *Med. Oral Patol. Oral Cir. Bucal* :4.
- [19] F.C. Wei, C.S. Seah, Y.C. Tsai, S.J. Liu, M.S. Tsai, Fibula osteoseptocutaneous flap for reconstruction of composite mandibular defects, *Plast. Reconstr. Surg.* 93 (2) (1994 Feb) 294–304, discussion 305–306.
- [20] D.A. Hidalgo, Fibula free flap: a new method of mandible reconstruction, *Plast. Reconstr. Surg.* 84 (1) (1989 Jul) 71–79.
- [21] S. Mardini, F. Wei, C.H. Lin, S.F. Jeng, Mandible reconstruction with vascularized fibula, *Semin. Plast. Surg.* 1 (17) (2003 Jan) 373–382.