


## CASE REPORT

## Live-attenuated vaccines in a cryopyrin-associated periodic syndrome patient receiving canakinumab treatment during infancy

Misa Watanabe<sup>1</sup> , Ryuta Nishikomori<sup>2</sup>, Yuki Fujimaki<sup>1</sup>, Toshio Heike<sup>2</sup>, Akira Ohara<sup>1</sup> & Tsutomu Saji<sup>3</sup>

<sup>1</sup>Department of Pediatrics, Toho University School of Medicine, Ota-ku, Tokyo, Japan

<sup>2</sup>Department of Pediatrics, Graduate School of Medicine, Kyoto University, Kyoto, Japan

<sup>3</sup>Advanced and Integrated Cardiovascular Research Course in the Young and Adolescence, Tokyo, Japan

### Correspondence

Misa Watanabe, Department of Pediatrics, Toho University School of Medicine, 6-11-1, Omori-Nishi, Ota-ku, Tokyo 143-8541, Japan. Tel: 703-3762-4151; Fax: 703-3298-8217; E-mail: misa-watanabe@med.toho-u.ac.jp

### Funding Information

No sources of funding were declared for this study.

Received: 30 April 2017; Revised: 29 July 2017; Accepted: 5 August 2017

*Clinical Case Reports* 2017; 5(11): 1750–1755

doi: 10.1002/ccr3.1149

## Introduction

Cryopyrin-associated periodic syndrome (CAPS) is a periodic fever syndrome classified as an autoinflammatory disease [1–3]. CAPS is caused by abnormalities in the NLRP3 protein in which a genetic mutation in the NACHT domain causes continuous overproduction of interleukin (IL)-1 $\beta$ , resulting in chronic inflammation and progressive tissue damage [4–7]. Canakinumab is a fully humanized anti-IL-1 $\beta$  monoclonal antibody that has been successfully used to manage CAPS [8–10]. However, clinical trials of canakinumab have been carried out in patients aged 2 years or older [11]. Furthermore, while the efficacy and safety of canakinumab have been recently reported [8–15], few reports have described administration of this drug in infants [16, 17]. Despite the lack of studies, data have highlighted the importance of beginning early treatment in infancy to prevent irreversible organ damage and life-long disabilities in patients with CAPS.

Inoculation of live-attenuated vaccines is contraindicated in patients treated with biologic agents. Therefore,

### Key Clinical Message

We successfully immunized the neonatal-onset multisystem inflammatory disease (NOMID) patient with live-attenuated vaccines for measles, rubella, varicella, and mumps and achieved sufficient antibody titer under canakinumab therapy without complications.

### Keywords

Canakinumab, cryopyrin-associated periodic syndrome, infant, live-attenuated vaccine, neonatal-onset multisystem inflammatory disease.

live-attenuated vaccines should be administered before initiating the treatment. However, neither live-attenuated vaccines nor biologics are recommended in early infancy.

Herein, we present the case of a 4-month-old girl with CAPS who exhibited neonatal-onset multisystem inflammatory disease/chronic infantile neurologic, cutaneous, and articular (NOMID/CINCA) syndrome. In this case, we successfully treated the patient with canakinumab starting at 6 months of age and immunized the patient with live-attenuated vaccines for measles, rubella, varicella, and mumps, without the occurrence of adverse events.

## Case Presentation

We acquired approval for this case study from the ethics committee of Toho University Hospital (no. 25-1, 26-148, and 27-137). Written informed consent was obtained from the guardians of the patient for publication of this case report and any accompanying images.

The 4-month-old girl was admitted to our hospital because of a generalized urticarial rash. She was born via

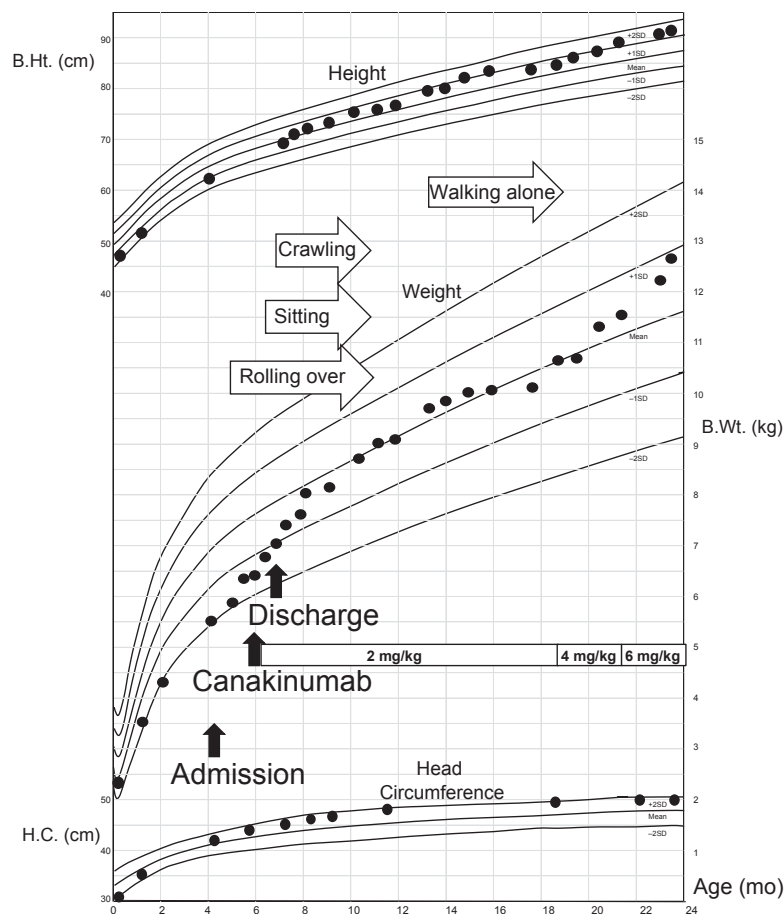
spontaneous vaginal delivery at 38 weeks of gestation to a healthy 39-year-old mother after an uncomplicated pregnancy. At birth, her weight was 2340 g ( $-1.5$  SD) and her length was 46 cm ( $-1.1$  SD). The rash appeared immediately after birth and worsened 4 months later; thus, the patient was referred to our hospital.

On the first visit to our outpatient clinic, the patient showed a high inflammatory response upon laboratory blood examination, although she was afebrile. One day before admission for further examination, the patient's temperature rose to  $38^{\circ}\text{C}$  and a daily fever recurred thereafter. There was no family history of skin rash, periodic fever, or other autoinflammatory diseases.

Physical examination showed an urticarial rash measuring 10–20 mm in diameter surrounded by erythema generally distributed over the skin. Audiography assessments did not show any abnormalities, with no joint swelling; however, hematological and serum biochemical examinations revealed a white blood cell count of  $17,300/\mu\text{L}$ , with

a differential profile of 5.5% band neutrophils, 30.5% segmented neutrophils, and 61% lymphocytes; C-reactive protein (CRP) was 59 mg/L; erythrocyte sedimentation rate (ESR) was 38 mm/h; serum amyloid A (SAA) was  $251 \mu\text{g/mL}$  (control  $\leq 8$ ); serum IL-6 was  $67.6 \text{ pg/mL}$  (control  $\leq 4$ ); serum immunoglobulin (Ig) G was  $1.127 \text{ mg/dL}$ ; IgA was  $25 \text{ mg/dL}$ ; and IgM was  $126 \text{ mg/dL}$ . Tests for autoantibodies were negative. A virological test showed a positive cytomegalovirus (CMV) IgM titer of 3.82 (control  $< 0.8$ ) and a positive CMV IgG titer of 30.9 (control  $< 2.0$ ), whereas CMV-C7HRP and CMV antigenemia were negative; these data indicated a recent CMV infection. The skin biopsy for histopathological examination showed no eosinophilic infiltration, with mild perivascular neutrophil infiltration.

After hospitalization, periodic fevers, aseptic meningitis, and a skin biopsy provided strong indicators of an autoinflammatory disease. An informed consent was obtained from her parents, and we performed genetic



**Figure 1.** Growth and development of the patient. The patient exhibited normal growth and development after the initiation of canakinumab treatment, with no signs of mental retardation. Mean and standard deviations of height, weight, and head circumference are shown for 0–27 months of age. B.Ht., B.Wt., and H.C. indicate body height, body weight, and head circumference, respectively.

testing, which showed a de novo heterozygous mutation in the *NLRP3* gene (c.2263G > A, p.Gly755Arg heterozygous); this mutation has been reported as a CAPS disease-causing mutation [18].

Accordingly, we started the patient on canakinumab at 6 months old after acquiring approval from the institutional ethics committee (no. 25-1) of our hospital. A positive clinical response was noted, with complete disappearance of the skin rash and periodic fevers 8.5 h after the first injection (2 mg/kg). The patient met the clinical and serological remission criteria used in the Japanese clinical studies [11], and canakinumab was administered as a single 2 mg/kg dose once every 8 weeks via subcutaneous injection.

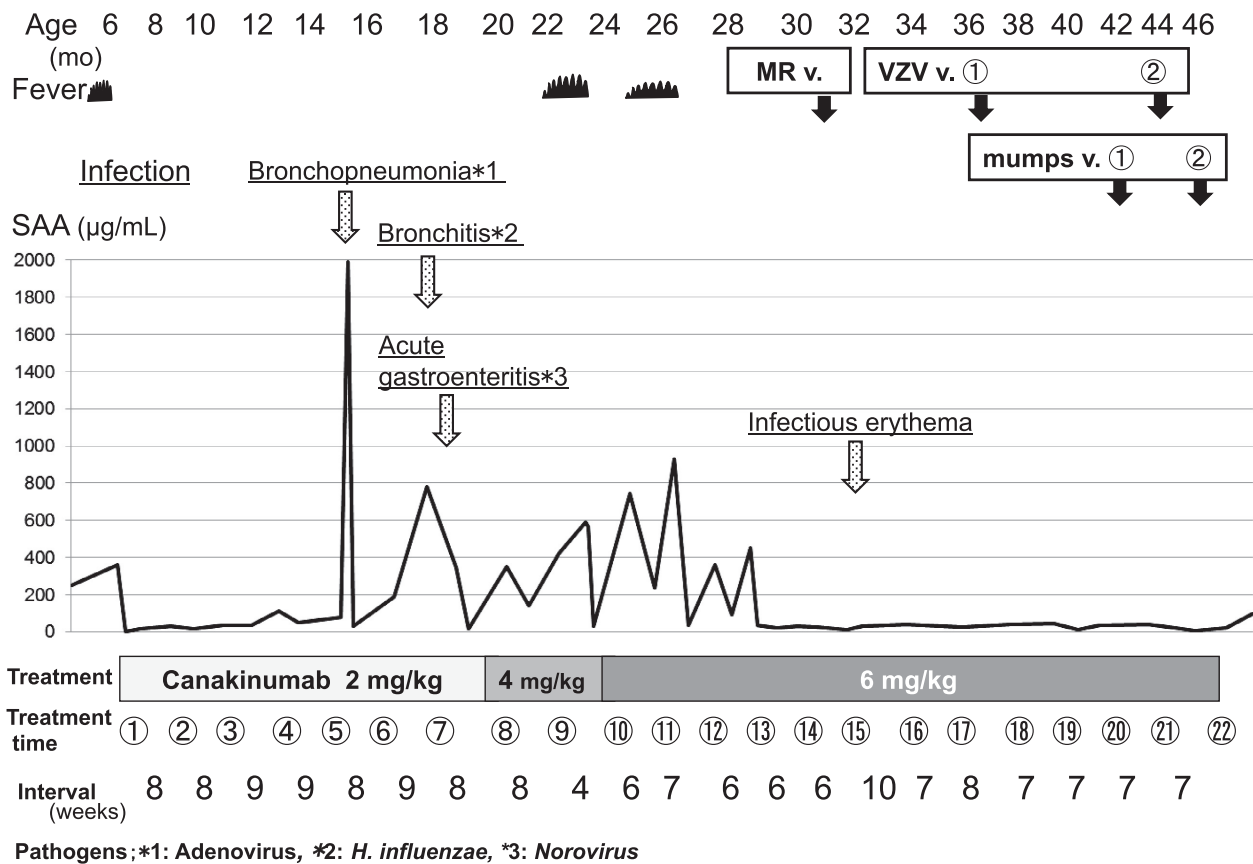
### Outcome and Follow-Up

Thereafter, the patient's body weight rapidly increased and motor development progressed normally (Fig. 1). She

began to walk at 15 months old and demonstrated normal psychomotor development.

We detected the presence of *Streptococcus pneumoniae* and *Branhamella catarrhalis* at 13 months old and *Haemophilus influenzae type B* at 15 months old using a suction sputum culture. These pathogens occasionally cause acute bronchopneumonia and acute bronchitis; however, they did not cause severe infection in this patient. In contrast, adenovirus-induced acute bronchopneumonia and norovirus-induced gastroenteritis resulted in the patient requiring intravenous treatment for several days (Fig. 2).

Nevertheless, the patient experienced periodic fevers without rash starting at 20 months old, with an elevated CRP of 32 mg/L and SAA of 349 µg/mL. After diagnosing her relapse, we increased the therapeutic dose of canakinumab in a stepwise manner to 6 mg/kg within 6–7 weeks (Fig. 2). The patient is now 47 months old and in clinical and serological remission.



**Figure 2.** Clinical course and laboratory findings after the initiation of canakinumab therapy. The figure shows the serum amyloid A (SAA) profile during the canakinumab treatment period. The disease-causing pathogens and diseases are underlined. Inoculation with live-attenuated vaccines (MR v., VZV v., and mumps v. are measles–rubella vaccine, varicella zoster vaccine, and mumps vaccine, respectively) are indicated by solid arrows.

Because viral infections may have triggered or exacerbated the CAPS symptoms, we implemented a normal vaccine schedule; the patient was vaccinated with *Bacillus Calmette–Guérin* (BCG), *Haemophilus influenzae* type B (Hib), 13-pneumococcal polysaccharide vaccine (PCV13), and diphtheria–pertussis–tetanus-inactivated polio vaccine (DPT-IPV) before initiating treatment (Table 1). Additionally, we administered the seasonal influenza vaccine and palivizumab for respiratory syncytial virus (RSV) infection. We then proposed a clinical research project to immunize the patient with live-attenuated vaccines while under canakinumab treatment, which was approved by the ethics committee of our hospital (no. 26-148, 27-137). Thus, the patient received the measles–rubella (MR) vaccine, primary/booster varicella zoster virus (VZV) vaccines, and mumps vaccine 3–4 weeks after the last injection and 4 weeks before the next injection of canakinumab at 31–46 months of age. She had no vaccine-related adverse effects and achieved sufficient antibody titers (measles IgG titer of  $\geq 128$  [control < 2.0]; rubella IgG titer of 31.5 [control < 2.0]; varicella zoster IgG titer of 6.0 [primary], 26.6 [booster; control < 2.0]; and mumps IgG titer of 7.8 [primary], 48.0 [booster; control < 2.0]; Table 1).

## Discussion

NOMID/CINCA syndrome is the most severe CAPS phenotype [12], exhibiting major symptoms such as chronic aseptic meningitis, developmental delays, mental retardation, osteoarthropathy, sensorineural hearing loss, and optic neuritis with loss of vision if left untreated [13]. We herein report a case of NOMID syndrome that was effectively and safely treated with canakinumab starting at 6 months of age without severe complications. In

addition, we successfully immunized the patient with live-attenuated vaccines.

Because canakinumab is not approved for use in infants younger than 2 years, we initiated treatment after acquiring approval from the institutional ethical committee of our hospital and the patient's parents. We also found three reports of infants treated with canakinumab; however, these cases had not been described in the literature at the initial presentation of our case [13, 16, 17]. Although the treatment in these three cases appeared to be effective with no particular or severe adverse effects, higher dosages of canakinumab were needed to control the disease [9, 10, 12]. Moreover, these reports highlighted the importance of beginning treatment early in infancy to prevent irreversible organ damage and lifelong disability. A minimum dose of canakinumab was maintained for remission in the present case until 20 months of age. The treatment was entirely effective and safe.

Treatment of genetic disorders, such as CAPS, at infancy may result in complications with vaccinations. However, nonlive vaccines are generally safe and effective in pediatric patients with autoimmune and rheumatic diseases receiving corticosteroids, immunosuppressants, and biologics [19–22]. Recently, the safety and efficacy of live-attenuated vaccines in rheumatic and autoimmune diseases have also been reported [23–26]. However, these findings are not sufficient to support the safety and immunogenicity of live-attenuated vaccines in pediatric patients with autoimmune and rheumatic diseases. Thus, live-attenuated vaccines should be administered to these patients only after acquiring approval from the appropriate institutional review board.

Autoinflammatory diseases are rare, making it difficult to perform studies with large numbers of patients. To

**Table 1.** Immunization records and antibody titers after vaccinations.

Before treatment				After treatment			
Age (months)	Vaccine	Frequency	Antibody titer	Age (months)	Vaccine	Frequency	Antibody titer
2–4	Hib	3		12	Hib	1	
2–4	PCV13	3		12	PCV13	1	
3–4	DPT-IPV	3	Pertussis FHA 27	17	DPT-IPV	1	Pertussis FHA 29
4	<b>BCG</b>	1		31	<b>MR</b>	1	Measles $\geq 128$ Rubella 31.5
				37	<b>VZV</b> ①	1	VZV 6
				44	<b>VZV</b> ②	Booster	VZV 26.6
				42	<b>Mumps</b> ①	1	Mumps 7.8
				46	<b>Mumps</b> ②	Booster	Mumps 48.0
				12–37	Flu	6	

Hib, *Haemophilus influenzae* type B; PCV13, pneumococcus; DPT-IPV, diphtheria–pertussis–tetanus-inactivated polio vaccine; FHA, filamentous hemagglutinin; MR, measles–rubella; VZV, varicella zoster virus; BCG, *Bacillus Calmette–Guérin*.

IgG antibody titers of measles, rubella, and varicella viruses were measured by enzyme-linked immunosorbent assay (ELISA) (Control < 2.0).

Filamentous hemagglutinin (FHA) in *Bordetella pertussis* IgG antibody titers was measured by ELISA (Control < 10.0 EU/mL).

The names in bold type indicate live vaccines.

date, only seven patients have been described as receiving live-attenuated vaccines along with antitumor necrosis factor alpha (TNF- $\alpha$ ) treatment; no reports have described the use of live-attenuated vaccines in patients administered anakinra and rilonacept. Five patients received the measles–mumps–rubella (MMR) vaccine, and two patients received the VZV vaccine without severe adverse events. Moreover, very few cases of patients receiving canakinumab therapy and the MMR vaccine have been reported to date; indeed, only one case in which vaccines were accidentally administered is currently described in the literature [9].

Vaccine schedules are different for each country. In Japan, an MR booster and varicella vaccine were included in the national vaccine program in 2006 and 2014, respectively. However, as the mumps vaccine is still optional, it is possible that our patient will be exposed to chickenpox and mumps while in school. Further, it is likely that viral infections exacerbated the initial CAPS symptoms, resulting in delayed treatment. In addition, our hospital is near an international airport. Thus, the patient was at risk of contact with individuals having infectious diseases acquired abroad; several measles outbreaks have occurred in recent years. Considering the risk of contracting vaccine-preventable diseases and the report of successful MMR immunization of a CAPS patient on canakinumab [9], we successfully immunized our patient with live-attenuated MR, varicella, and mumps vaccines without any side effects. Subsequently, we administered VZV and mumps booster vaccines and obtained sufficient titers.

As described above, canakinumab appears to be effective and safe in infants with NOMID/CINCA syndrome. In the present case, we started treatment early to avoid irreversible sequelae. Moreover, we successfully immunized the patient with live-attenuated vaccines concomitantly with canakinumab treatment. Thus, a normal vaccination schedule may be possible in these patients to avoid acquiring vaccine-preventable diseases. Accordingly, further studies of live-attenuated vaccines in these patients are urgently needed to improve their quality of life.

## Acknowledgments

We thank Ms. Yuki Takaoka at the Department of Pediatrics, Graduate School of Medicine, Kyoto University, for her assistance with genetic testing.

## Authorship

MW: cared for the patient and drafted most of the manuscript. RN: helped with the diagnosis, advised on therapy, and was involved in drafting and revising the manuscript.

YF: cared for the patient. TH: helped with the diagnosis and advised on therapy. AO and TS: were the senior physicians responsible for the care of the patient and revision of the manuscript.

## Conflict of Interest

All authors have no conflict of interests to disclose.

## References

- Hassink, S. G., and D. P. Goldsmith. 1983. Neonatal onset multisystem inflammatory disease. *Arthritis Rheum.* 26:668–673.
- Prieur, A. M., C. Griscelli, F. Lampert, H. Truckenbrodt, M. A. Guggenheim, D. J. Lovell, et al. 1987. A chronic, infantile, neurological, cutaneous and articular (CINCA) syndrome: a specific entity analysed in 30 patients. *Scand. J. Rheumatol.* 66(Suppl):57–68.
- Hull, K. M., N. Shoham, J. J. Chae, I. Aksentijevich, and D. L. Kastner. 2003. The expanding spectrum of systemic autoinflammatory disorders and their rheumatic manifestations. *Curr. Opin. Rheumatol.* 15:61–69.
- Neven, B., I. Callebaut, A. M. Prieur, J. Feldmann, C. Bodemer, L. Lepore, et al. 2004. Molecular basis of the spectral expression of CIAS1 mutations associated with phagocytic cell-mediated autoinflammatory disorders CINCA/NOMID, MWS, and FCU. *Blood* 103:2809–2815.
- Stojanov, S., and D. L. Kastner. 2005. Familial autoinflammatory diseases: genetics, pathogenesis and treatment. *Curr. Opin. Rheumatol.* 17:586–599.
- Dinareello, C. A. 2007. Mutations in cryopyrin: bypassing roadblocks in the caspase 1 inflammasome for interleukin-1 $\beta$  secretion and disease activity. *Arthritis Rheum.* 56:2817–2822.
- Gattorno, M., S. Tassi, S. Carta, L. Delfino, F. Ferlito, M. A. Pelagatti, et al. 2007. Pattern of interleukin-1 $\beta$  secretion in response to lipopolysaccharide and ATP before and after interleukin-1 blockade in patients with CIAS1 mutations. *Arthritis Rheum.* 56:3138–3148.
- Lachmann, H. J., I. Kone-Paut, J. B. Kuemmerle-Deschner, K. S. Leslie, E. Hachulla, P. Quartier, et al. 2009. Use of canakinumab in the cryopyrin-associated periodic syndrome. *N. Engl. J. Med.* 360:2416–2425.
- Kuemmerle-Deschner, J. B., E. Hachulla, R. Cartwright, P. N. Hawkins, T. A. Tran, B. Bader-Meunier, et al. 2011. Two-year results from an open-label, multicentre, phase III study evaluating the safety and efficacy of canakinumab in patients with cryopyrin-associated periodic syndrome across different severity phenotypes. *Ann. Rheum. Dis.* 70:2095–2102.
- Kuemmerle-Deschner, J. B., and I. Haug. 2013. Canakinumab in patients with cryopyrin-associated

- periodic syndrome: an update for clinicians. *Ther. Adv. Musculoskelet Dis.* 5:315–329.
11. Yokota, S., R. Nishikomori, H. Takada, M. Kikuchi, T. Nozawa, T. Kanetaka, et al. 2013. Guidance on the use of canakinumab in patients with cryopyrin-associated periodic syndrome in Japan. *Mod. Rheumatol.* 23:425–429.
  12. Imagawa, T., R. Nishikomori, H. Takada, S. Takeshita, N. Patel, D. Kim, et al. 2013. Safety and efficacy of canakinumab in Japanese patients with phenotypes of cryopyrin-associated periodic syndrome as established in the first open-label, phase-3 pivotal study (24-week results). *Clin. Exp. Rheumatol.* 31:302–309.
  13. Kuemmerle-Deschner, J. B., E. Ramos, N. Blank, J. Roesler, S. D. Felix, T. Jung, et al. 2011. Canakinumab (ACZ885, a fully human IgG1 anti-IL-1 $\beta$  mAb) induces sustained remission in pediatric patients with cryopyrin-associated periodic syndrome (CAPS). *Arthritis Res. Ther.* 13:R34.
  14. Russo, R. A., S. Melo-Gomes, H. J. Lachmann, K. Wynne, K. Rajput, D. Eleftheriou, et al. 2014. Efficacy and safety of canakinumab therapy in paediatric patients with cryopyrin-associated periodic syndrome: a single-centre, real-world experience. *Rheumatology (Oxford)* 53:665–670.
  15. Sibley, C. H., A. Chioato, S. Felix, L. Colin, A. Chakraborty, N. Plass, et al. 2015. A 24-month open-label study of canakinumab in neonatal-onset multisystem inflammatory disease. *Ann. Rheum. Dis.* 74:1714–1719.
  16. Kanariou, M., S. Tantou, I. Varela, M. Raptaki, C. Petropoulou, I. Nikas, et al. 2014. Successful management of cryopyrin-associated periodic syndrome with canakinumab in infancy. *Pediatrics* 134:e1468–e1473.
  17. Paccaud, Y., G. Berthet, A. Von Scheven-Gête, B. Vaudaux, Y. Mivelaz, M. Hofert, et al. 2014. Neonatal treatment of CINCA syndrome. *Pediatr. Rheumatol. Online J.* 12:52.
  18. Tanaka, N., K. Izawa, M. K. Saito, M. Sakuma, K. Oshima, O. Ohara, et al. 2011. High incidence of NLRP3 somatic mosaicism in patients with chronic infantile neurologic, cutaneous, articular syndrome: results of an International Multicenter Collaborative Study. *Arthritis Rheum.* 63:3625–3632.
  19. Kobayashi, I., M. Mori, K. Yamaguchi, S. Ito, N. Iwata, K. Masunaga, et al. 2015. Pediatric Rheumatology Association of Japan recommendation for vaccination in pediatric rheumatic diseases. *Mod. Rheumatol.* 25:335–343.
  20. van Assen, S., M. Bijl. 2012. Immunization of patients with autoimmune inflammatory rheumatic diseases (the EULAR recommendations). *Lupus* 21:162–167.
  21. Heijstek, M. W., L. M. Ott de Bruin, R. Borrow, F. van der Klis, I. Koné-Paut, A. Fasth, et al. 2011. Vaccination in paediatric patients with auto-immune rheumatic diseases: a systemic literature review for the European League against Rheumatism evidence-based recommendations. *Autoimmun. Rev.* 11:112–122.
  22. Heijstek, M. W., L. M. Ott de Bruin, M. Bijl, R. Borrow, F. van der Klis, I. Koné-Paut, et al. 2011. EULAR recommendations for vaccination in paediatric patients with rheumatic diseases. *Ann. Rheum. Dis.* 70:1704–1712.
  23. Ranjan, P., A. Chakrawarty, A. Kumari, and J. Kumar. 2015. Immunization in patients with rheumatic diseases: a practical guide for general practitioners. *J. Clin. Diagn. Res.* 9:OE01–OE014.
  24. Heijstek, M. W., G. C. Pileggi, E. Zonneveld-Huijssoon, W. Armbrust, E. P. Hoppenreijns, C. S. Uiterwaal, et al. 2007. Safety of measles, mumps and rubella vaccination in juvenile idiopathic arthritis. *Ann. Rheum. Dis.* 66:1384–1387.
  25. Borte, S., U. G. Liebert, M. Borte, and U. Sack. 2009. Efficacy of measles, mumps and rubella revaccination in children with juvenile idiopathic arthritis treated with methotrexate and etanercept. *Rheumatology (Oxford)* 48:144–148.
  26. Heijstek, M. W., P. G. van Gageldonk, G. A. Berbers, and N. M. Wulffraat. 2012. Differences in persistence of measles, mumps, rubella, diphtheria and tetanus antibodies between children with rheumatic disease and healthy controls: a retrospective cross-sectional study. *Ann. Rheum. Dis.* 71:948–954.