

Localized Pigmented Villonodular Synovitis of the Knee Co-existing with Extra-articular Nodular Synovitis of the Popliteus Tendon Sheath: A Case Report

Abstract

Pigmented villonodular synovitis (PVNS) is a rare proliferative disorder affecting the synovial membranes of joints, bursae, and tendons. The knee joint is one of the most common locations for an intra-articular type of PVNS and this is usually of the diffuse type of PVNS or diffuse pigmented villonodular synovitis (DPVNS). DPVNS tends to be more associated with affection of contiguous structures. We report a case of a localized form of the disease affecting the knee joint coexisting with an extra-articular lesion of the same nature involving the popliteus tendon sheath of the same knee. The clinical condition was managed with a combined surgical approach of arthroscopic marginal excision for the intra-articular lesion and excision biopsy for the extra-articular lesion.

Keywords: *Extra-articular, intra-articular, nodular synovitis*

Introduction

Pigmented villonodular synovitis (PVNS) is an infrequent proliferative disorder of synovial joints, tendon sheath, and bursa. The name PVNS was first used to describe the disorder by Jaffe *et al.*^[1] Subsequently, Granowitz and Mankin^[2] described the existence of a localized pigmented villonodular synovitis (LPVNS) and diffuse pigmented villonodular synovitis (DPVNS). Both forms of the disease have been noted to be similar in appearance with features of an inflamed synovial membrane laden with hemosiderin deposits at histology.^[3] However, in more recent times, the terms giant cell tumor and PVNS have been described by the World Health Organization to be equivalent terms.^[4] *The age group most affected has been noted to be those in the third and fourth decade of life.*^[5] *DPVNS is said to be the most common presentation involving intra-articular tissues. It may extend further into extra-articular structures, as part of a chronic process. On the contrary, LPVNS is characterized by discrete nodular lesions.*^[6,7] The anterior knee compartment is said to be the most common location of PVNS when it does affect the knee with the common site of involvement in the knee being the synovium in the anterior horn region of the medial meniscus. DPVNS

has also been noted to have the capacity to extensively invade local structures such as muscle, tendon, and skin.^[8] LPVNS is said to be the more common and is usually extra-articular. On the contrary, the DPVNS tend to be intra-articular. Intra-articular LPVNS is said to represent 6% of all cases of PVNS.^[9,10] We report a case of LPVNS coexisting with a lesion in the popliteus tendon sheath in a patient who presented to our facility.

Case Report

We report A.T., a 35-year-old female school teacher, who presented with a 2-month history of a worsening, right knee pain with difficulty using the right lower limb necessitating the use of a walking aid. The knee pain was preceded by a fall at home while walking across the room. There was also a history of mild right knee swelling, but no feeling of catching, locking, giving way, or instability in the right knee.

The findings on physical examination revealed a patient with a right antalgic gait and a positive medial joint line tenderness in the right knee. The range of motion was full and neurovascular status was normal. Plain radiograph of the knee revealed no bony abnormalities. However, magnetic resonance imaging revealed a well-defined,

**Qladimeji Ranti Babalola¹,
Bright Igbinoba¹,
S. Uwale Eyesan²,
Kolawole Olanrewaju Aramide³,
Malomo Oluwabusayomi Oghenerume¹,
Adedamola D. Onobinoje¹**

¹Department of Orthopaedics and Trauma Surgery, National Orthopaedic Hospital, Igbobi-Lagos, ²Department of Orthopaedics and Trauma, Bowen University Teaching Hospital, Ogbomoso, Oyo State, ³Department of Pathology, National Orthopaedic Hospital, Igbobi-Lagos, Nigeria

Received: 21-Jan-2022
Accepted: 16-Feb-2022
Published: 04-May-2022

Address for correspondence:
Dr. Qladimeji Ranti Babalola,
Department of Orthopaedics
and Trauma Surgery, National
Orthopaedic Hospital,
Igbobi-Lagos, Nigeria.
E-mail: ladibabalola28@gmail.
com

Access this article online

Website:

www.jwacs-jcoac.org

DOI: 10.4103/jwas.jwas_20_22

Quick Response Code:



How to cite this article: Babalola QR, Igbinoba B, Eyesan SU, Aramide KO, Oghenerume MO, Onobinoje AD. Localized pigmented villonodular synovitis of the knee co-existing with extra-articular nodular synovitis of the popliteus tendon sheath: A case report. *J West Afr Coll Surg* 2020;10:45-8.

This is an open access journal, and articles are distributed under the terms of the Creative Commons Attribution-NonCommercial-ShareAlike 4.0 License, which allows others to remix, tweak, and build upon the work non-commercially, as long as appropriate credit is given and the new creations are licensed under the identical terms.

For reprints contact: reprints@medknow.com

hyperintense, intracapsular lesion in the posterior aspect of the right knee joint, suspected to be focal PVNS and a focal area of hyperintensity in the anterior compartment of the knee.

She subsequently had diagnostic arthroscopy and arthroscopic biopsy of the lesion in the anterior joint compartment [Figure 1]. Diagnostic arthroscopy revealed focal areas of synovial hypertrophy involving the infrapatellar fat pad and anteromedial portion of the synovium with villous-like projections capped with black, hyperpigmented tissues [Figure 2].

Histology result of the biopsy of the lesion of the anterior knee compartment was in keeping with PVNS of the knee. She was subsequently planned for an arthroscopic synovectomy of the lesions in the anterior compartment of the knee and open excisional biopsy of the nodule in the posterior knee compartment. She eventually had an arthroscopic synovectomy of the lesion in the anterior knee compartment and open excision

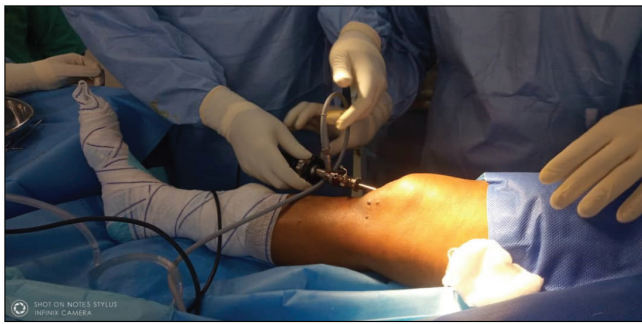

Figure 1: Arthroscopic approach to the anterior aspect of the knee joint

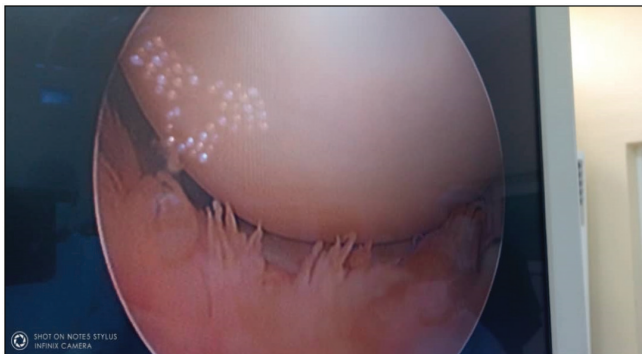


Figure 2: Arthroscopic view of the villous projections of the synovium

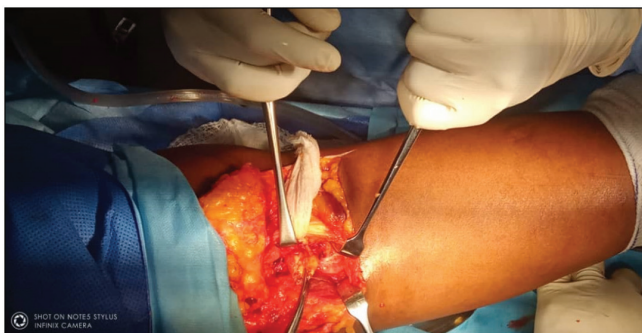


Figure 3: Open approach to the posterior aspect of the knee to the attached giant cell tumor of popliteus tendon sheath

biopsy of the posterior lesion using a posterior approach to the knee [Figure 3]. The histology report of excised nodule in the posterior knee compartment [Figure 4] and excised localized tissue in the anterior knee compartment revealed sections of intra-articular mass with nodular architecture composed of mononuclear stroma cells admixed osteoclast-like giant cells and chronic inflammation cells, multifocal areas of stromal hyalinization and hemosiderin was also noted with few normal mitotic figures. Features were in keeping with giant cell tumor of synovium [Figure 5].

Discussion

When PVNS does affect a joint, it tends to be more commonly a mono-articular than the poly-articular disease. It tends to affect the knee joint in most cases of articular involvement. DPVNS tends to be more widespread with the involvement of contiguous structures and may run an aggressive course. Our patient presented with a localized mono-articular disease affecting the right knee joint with a concomitant extra-articular lesion involving the popliteus tendon sheath of the same knee.

The cause of PVNS lesions remains uncertain. However, possible etiological factors that have been adduced to the occurrence of PVNS include Trauma and subsequent bleeding into the affected joint; a possible neoplastic process; chromosome 7 trisomy and clonal rearrangements.^[5,6,11] The

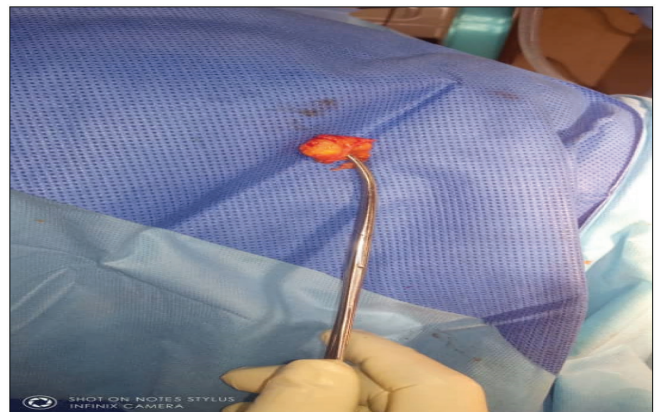


Figure 4: Excised giant cell tumor of the popliteus tendon sheath

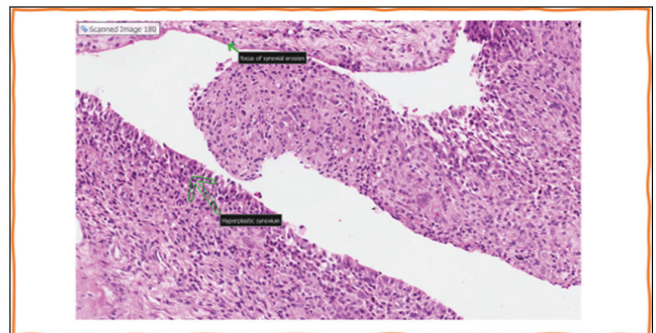


Figure 5: Hyperplastic synovium with papillary projections composed of foamy histiocytes and hemosiderin containing macrophages, large clefts, pseudo-glandular, or alveolar spaces lined by synovial cells, osteoclast-like multinucleated (10–70 nuclei) giant cells, and epithelioid cells

only identifiable possible etiology in our case was the history of trauma. PVNS is said to generally affect individuals in the third and fourth decades of life.^[5,6] However, it has been diagnosed in children in individuals between the ages 3–19.^[12] No gender predilection is seen in intra-articular disease, but a slight female preponderance has been noted with extra-articular disease. Our case report of a young woman in her mid-thirties with an LPVNS involving the tendon sheath easily feeds into findings from previous studies. However, the concomitant existence of a PVNS lesion in the ipsilateral knee joint is more in keeping with a DPVNS as previous studies have noted that DPVNS when it does involve a joint tends to be widespread and because it tends to involve every compartment of the joint it more easily spreads to contiguous structures such as the popliteus tendon sheath in the index case.^[13] The existence of an extra-articular lesion and an LPVNS as in our index case would tend to suggest a sort of “synchronous lesion” coexisting in the same region. Also, when LPVNS does occur in the knee it’s been said to be more frequently observed in the anterior compartment which is in keeping with our observation in the index case. The key findings at histology [Figure 5] are in keeping with the presence of lipid-laden macrophages, giant cells with multiple nuclei, hemosiderin deposits, proliferating fibroblasts cells.^[14]

Current treatment options available in the management of PVNS include surgery and radiotherapy. However, surgery remains the first choice of care.^[15] The goal of surgery is to excise all the lesion to reduce the risk of recurrence. The approach to surgery may be open or arthroscopic, whereas excision may be marginal for LPVNS or total in the case of DPVNS. Arthroscopic surgical excision is particularly indicated in LPVNS as the usual location in the anterior compartment of the knee makes for ease of access. Where arthroscopy has to be used for DPVNS complementary portals in addition to the use of 30° and 70° arthroscopes have been advised.^[16,17] Otherwise, an open approach may be adopted for the excision of the posterior compartment lesion, whereas an arthroscopic approach is used for the anterior compartment. In the case being reported, arthroscopy was used for the marginal excision of the LPVNS in the anterior compartment. However, arthroscopic access to the lesion in the popliteus tendon sheath was not possible hence an exclusively arthroscopic approach to excision was not possible in this case. An open technique had to be used to excise the lesion in the popliteus tendon. Our approach represented a combination approach of arthroscopy and open technique. Arthroscopic technique has been observed to have a low recurrence rate, complication rate, and better functional outcome scores when compared to the open technique.^[18] Arthroscopy is not without potential complications which include some risk of recurrence, joint tumor dispersion, portal contamination, extensive joint involvement, and extra-articular dissemination.^[19] Open excision is generally advised for DPVNS of the knee and for lesions in arthroscopically inaccessible areas. Potential complications of the open technique that have described include longer rehabilitation period and postoperative knee

stiffness. Adjuvant radiation therapy of the involved region has been described in the treatment of DPVNS but with some conflicting outcome.^[16] Radiation is also not without its attendant complications such as skin reactions and possible neoplastic transformation.^[17] We used no form of radiation therapy in the care of the case presented.

Conclusion

Our case report raises the possibility of the coexistence of an LPVNS with an extra-articular lesion of the same histology as against the regular understanding that DPVNS is more likely to be associated involvement of extra-articular structures from a contiguous spread. The place of combined surgical approach with the use of arthroscopy and open surgical technique also reduces the morbidity that may attend an anterior arthrotomy for the excision of the LPVNS along with the open procedure for the extra-articular mass.

Financial support and sponsorship

Nil.

Conflicts of interest

There are no conflicts of interest.

References

- Jaffe HL, Lichtenstein I, Sutro CJ. Pigmented villonodular synovitis, bursitis and tenosynovitis. *Arch Pathol* 1941;31:731-65.
- Granowitz SP, Mankin HJ. Localized pigmented villonodular synovitis of the knee: Report of five cases. *J Bone Joint Surg Am* 1967;49:122-8.
- Oehler S, Fassbender HG, Neureiter D, Meyer-Scholten C, Kirchner T, Aigner T. Cell populations involved in pigmented villonodular synovitis of the knee. *J Rheumatol* 2000;27:463-70.
- Jendrissek KA, Hotfiel T, Swoboda B, Söder S, Janka R. Pigmented villonodular synovitis: A rare differential diagnosis of synovial joint swelling. *Z Rheumatol* 2016;75:157-65.
- Flandry F, Hughston JC, McCann SB, Kurtz DM. Diagnostic features of diffuse pigmented villonodular synovitis of the knee. *Clin Orthop Relat Res* 1994;298:212-20.
- de Visser E, Veth RP, Pruszczynski M, Wobbes T, Van de Putte LB. Diffuse and localized pigmented villonodular synovitis: Evaluation of treatment of 38 patients. *Arch Orthop Trauma Surg* 1999;119:401-4.
- Bouguennec N, Meyer A, Graveleau N. Localized form of pigmented villonodular synovitis of the knee: The meniscal mime. *Orthop Traumatol Surg Res* 2014;100:251-4.
- Ray RA, Morton CC, Lipinski KK, Corson JM, Fletcher JA. Cytogenetic evidence of clonality in a case of pigmented villonodular synovitis. *Cancer* 1991;67:121-5.
- Kransdorf MJ, Murphey MD, editors. Synovial tumors. In: *Imaging of Soft Tissue Tumors*. Philadelphia, PA: Lippincott Williams & Wilkins; 2006. p. 381-436.
- Murphey MD, Rhee JH, Lewis RB, Fanburg-Smith JC, Flemming DJ, Walker EA. Pigmented villonodular synovitis: Radiologic-pathologic correlation. *Radiographics* 2008;28:1493-518.
- Perka C, Labs K, Zippel H, Buttgerit F. Localized pigmented villonodular synovitis of the knee joint: Neoplasm or reactive granuloma? A review of 18 cases. *Rheumatology (Oxford)* 2000;39:172-8.

12. Baroni E, Russo BD, Masquijo JJ, Bassini O, Miscione H. Pigmented villonodular synovitis of the knee in skeletally immature patients. *J Child Orthop* 2010;4:123-7.
13. Chin KR, Barr SJ, Winalski C, Zurakowski D, Brick GW. Treatment of advanced primary and recurrent diffuse pigmented villonodular synovitis of the knee. *J Bone Joint Surg Am* 2002;84:2192-202.
14. Temponi EF, Barros AAG, Paganini VO, Barbosa VAK, Badet R, Carvalho Júnior LH. Diffuse pigmented villonodular synovitis in knee joint: Diagnosis and treatment. *Rev Bras Ortop* 2017;52:450-7.
15. Mollon B, Griffin AM, Ferguson PC, Wunder JS, Theodoropoulos J. Combined arthroscopic and open synovectomy for diffuse pigmented villonodular synovitis of the knee. *Knee Surg sports Traumatol Arthrosc* 2016;24:260-6.
16. Nassar WAM, Bassiony AA, Elghazaly HA. Treatment of diffuse pigmented villonodular synovitis of the knee with combined surgical and radiosynovectomy. *HSS J* 2009;5:23-9.
17. Rodriguez C, Leon HO, Guthrie TB. Combined partial arthroscopic synovectomy and radiation therapy for diffuse pigmented villonodular synovitis of the knee. *Arthroscopy* 2001;17:527-35.
18. Aurégan JC, Klouche S, Bohu Y, Lefèvre N, Herman S, Hardy P. Treatment of pigmented villonodular synovitis of the knee. *Arthroscopy* 2014;30:1327-134.
19. Mollon B, Lee A, Busse JW, Griffin AM, Ferguson PC, Wunder JS, *et al.* The effect of surgical synovectomy and radiotherapy on the rate of recurrence of pigmented villonodular synovitis of the knee: An individual patient meta-analysis. *Bone Joint J* 2015;97-B:550-7.