



Since January 2020 Elsevier has created a COVID-19 resource centre with free information in English and Mandarin on the novel coronavirus COVID-19. The COVID-19 resource centre is hosted on Elsevier Connect, the company's public news and information website.

Elsevier hereby grants permission to make all its COVID-19-related research that is available on the COVID-19 resource centre - including this research content - immediately available in PubMed Central and other publicly funded repositories, such as the WHO COVID database with rights for unrestricted research re-use and analyses in any form or by any means with acknowledgement of the original source. These permissions are granted for free by Elsevier for as long as the COVID-19 resource centre remains active.



Case report

Locked-In with COVID-19

Akshay Avula^{a,*}, Arshpal Gill^b, Ra'ed Nassar^b, Krishna Nalleballe^c, Suman Siddamreddy^d, Michel Chalhoub^a

^a Department of Pulmonary Critical Care Medicine, Northwell Health – Staten Island University Hospital, NY, USA

^b Department of Medicine, Northwell Health – Staten Island University Hospital, NY, USA

^c Department of Neurology, University of Arkansas for Medical Sciences, AR, USA

^d Department of Internal Medicine, Baptist Health/University of Arkansas for Medical Sciences, USA



ARTICLE INFO

Article history:

Received 13 May 2020

Accepted 5 July 2020

Keywords:

COVID-19

Locked in Syndrome

Stroke

Hypercoagulability

ABSTRACT

Coronavirus Disease 2019 (COVID-19) can be associated with various neurological manifestations including acute strokes. Hyper acute diagnosis and treatment are key factors which decrease mortality and morbidity in stroke patients. The COVID-19 pandemic has introduced a great strain on the healthcare system, and as a result clinicians are facing several barriers in diagnosing and treating strokes. Delayed presentation of strokes is a problem as some in the general population defer the decision to seek immediate medical attention fearing contracting the virus. Also playing a role is the paucity of healthcare professionals available during a pandemic. Recent literature demonstrates the association of acute strokes in young patients with COVID-19. Lack of clear pathophysiology of the neurological manifestations from COVID-19 intensifies the problem. A thorough examination of the intensive care unit patient has always been a challenge owing to several factors including use of sedatives, sepsis, uremia, and encephalopathy secondary to medications. Locked-In Syndrome (LIS) secondary to stroke is much more challenging to diagnose as patients are unable to communicate or elicit any motor functions apart from certain ocular movements. We present the case of a 25 year old patient with no known history of coagulopathy, but had developed COVID-19 cytokine storm which culminated in LIS secondary to pontine strokes.

© 2020 Elsevier Ltd. All rights reserved.

1. Introduction

Coronavirus Disease-19 (COVID-19) is viral illness caused by the novel severe acute respiratory syndrome coronavirus 2 (SARS CoV-2) [1]. The virus was initially reported in a patient in Wuhan, China in December 2019, and it rapidly progressed into a pandemic currently affecting around 180 countries affecting more than four million patients and causing 200,000 deaths [2]. The majority of the patients presented with constitutional symptoms including fevers, myalgias, respiratory symptoms, and gastrointestinal symptoms. Neurological symptoms are less reported, but a recent study identified around 36.7% of hospitalized patients had neurological symptoms during the course of illness [3]. There are numerous reports of acute strokes in patients with COVID-19 [4,5]. To our knowledge, at present time, there is no reported case of Locked-In Syndrome associated COVID-19. Here we present a patient who developed LIS as a result of severe SARS CoV-2 infection.

2. Case description

A 25-year old female with past medical history of insulin dependent diabetes mellitus, and obesity presented to the hospital with several day history of cough, shortness of breath, fever and malaise. She had stopped taking her insulin secondary to poor appetite. Multiple family members were hospitalized for COVID-19 illness. Vital signs on presentation were significant for fever of 102°F, heart rate of 103 beats per minute, and oxygen saturation of 91% on 6L nasal cannula. Initial exam was significant for tachypnea with no respiratory distress. Initial labs were pertinent for leukocytosis with lymphopenia, elevated ferritin, elevated blood sugar, and elevated anion gap. Erythrocyte sedimentation rate (ESR) and C-reactive protein (CRP) were elevated as well. Chest X-ray revealed bilateral interstitial and alveolar opacities. The patient was diagnosed with Diabetic keto-acidosis and admitted to medicine service. SARS-CoV-2 was detected on the nasal swab specimen. The patient was transferred to the intensive care unit (ICU) where she had a prolonged course.

The patient's respiratory status declined the next day requiring endotracheal intubation with mechanical ventilation. The patient was initially sedated with Propofol and Morphine, and later

* Corresponding author at: 344 Marshall Dr S., Apt 1 D, Brooklyn, NY 11209, USA.
E-mail address: aavula@northwell.edu (A. Avula).

required midazolam to attain appropriate levels of sedation. She required neuromuscular blocking agents for ventilator dyssynchrony initially as a continuous infusion followed by intermittent doses. A five day course of hydroxychloroquine 400 mg daily, seven day corticosteroids course and a single dose of Tocilizumab 400 mg were given. Despite this, the cytokine storm persisted and the patient deteriorated quickly leading to multi-organ dysfunction requiring renal replacement therapy.

The patient failed spontaneous awakening trials initially due to tachypnea, tachycardia and ventilator dyssynchrony. As her respiratory status improved requiring minimal ventilator support, patient was eventually weaned off all sedation and placed on intermittent sedation. On hospital day-13 a more detailed neurological exam revealed that patient was able to follow commands through eye blinking and horizontal eye movement, but was unable to exhibit any other motor functions. Babinski sign was positive bilaterally. National Institute of Health Stroke Scale was calculated to be 27.

Computerized Tomography (CT) of the head did reveal any acute findings. Electroencephalogram and lumbar puncture (Table 1) failed to identify an etiology for the patient’s neurological state. Lumbar puncture sample did not detect SARS CoV-2. A Mag-

netic Resonance Imaging (MRI) of the head revealed multiple foci of restricted diffusion within the pons, correlating with FLAIR signal abnormality (Figs. 1, 2) consistent with acute pontine ischemic infarcts. Magnetic Resonance Angiography (MRA) of head and neck showed decreased flow in distal right vertebral artery but a patent basilar artery (Fig. 3). Based on clinical findings and neuroimaging, the patient was diagnosed with Locked-In Syndrome (LIS). Neuro-endovascular intervention was deferred as there was no acute thrombus on the angiography; and heparin therapy was initiated

Table 1
CSF studies.

CSF Laboratory value	Results
Total nucleated cell count	3
Appearance	Clear
RBC count	600
LDH	18
Protein	23
Glucose	149
COVID-19	Not detected
NMDA-R Ab	Negative
CASPR2-IgG	Negative
GAD65 Ab	Negative
GABA-B-R Ab	Negative
Anti-Neuronal Nuclear Ab	Negative
Anti-Glial Nuclear Ab	Negative
Purkinje Cell Cytoplasmic Ab	Negative
Amphiphysin Ab	Negative
DPPX Ab	Negative

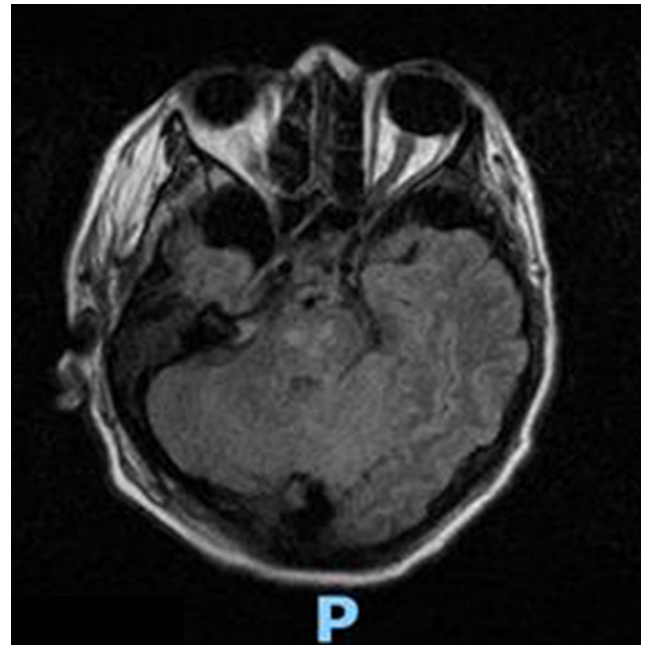


Fig. 2. MRI brain-T2 Flair showing pontine hyper intensities.

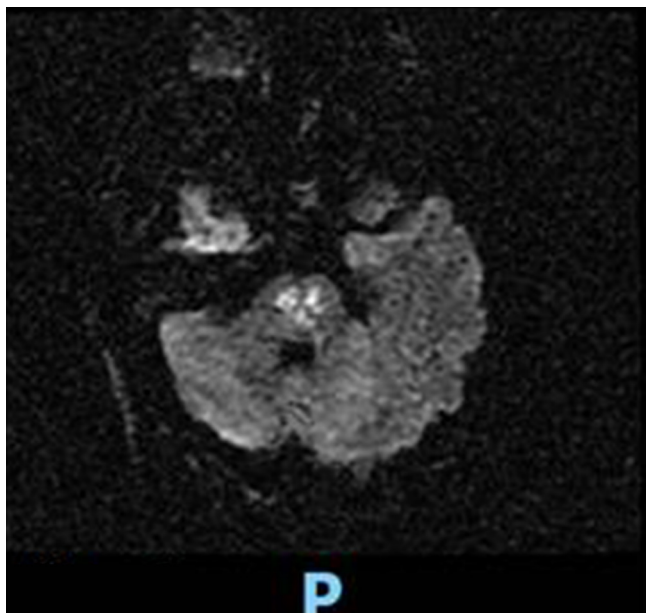


Fig. 1. MRI brain-DWI sequences showing acute bilateral pontine strokes.

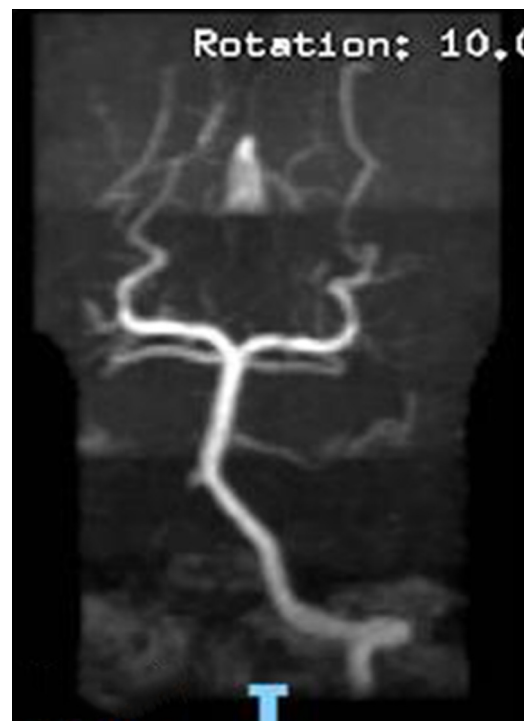

Fig. 3. MRA head showing decreased flow in distal right vertebral artery but patent basilar artery.

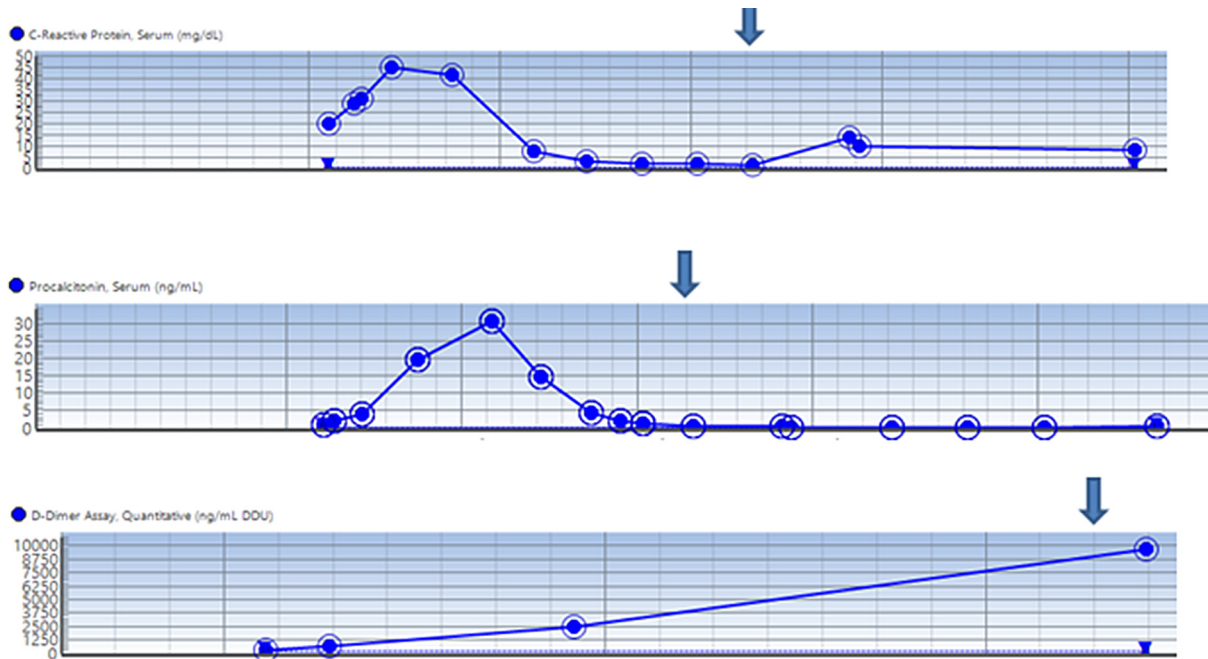


Fig. 4. Trend of inflammatory markers and D-Dimer. Arrow represents the day of stroke diagnosis. The inflammatory markers trended while the D-dimer was trending up close to the stroke.

for anticoagulation. The patient did not have a history of coagulopathy, and given her young age it was believed the etiology of her stroke was secondary to COVID-19. The trend of inflammatory markers and D-Dimer in the patient is shown in Fig. 4.

3. Discussion

Locked in Syndrome (LIS) is a rare but devastating condition caused by damage to bilateral corticospinal, corticobulbar and corticopontine tracts of ventral brain stem. Characteristically these patients are quadriplegic, often with aphasia and dysphagia despite being fully conscious and cognitive [6,7]. The majority of patients retain the ability to move the eyes and the ability to blink, while others are able to retain minimal voluntary movements of face, tongue and limbs. The most common etiology of LIS is acute ischemic or hemorrhagic strokes of the brain stem [8].

4. Pathophysiology of LIS in COVID-19

Multiple reports have demonstrated that patients with COVID-19 disease may develop acute strokes [3–5]. An observational study from Netherlands showed that almost 31% of ICU patients with COVID-19 had thrombotic complications, among which 3.7% had developed acute strokes [9]. Several reports of pulmonary embolism and acute myocardial infarction from COVID-19 are reported as well [10–12]. There are multiple reports of numerous infarcts and detection of antiphospholipid antibodies in patients with COVID-19 [13,14]. While the natural history of COVID-19 disease varies, patients with severe COVID-19 are more likely to have elevated D-dimer levels and thrombocytopenia compared to patients who developed a more mild course of COVID-19 [15,16]. Shorter clot formation times and higher maximum clot firmness reflecting hypercoagulable thromboelastographic profiles have been noted in patients alongside increased fibrinogen and D-dimer [17]. This suggests that fibrin formation and polymerization may be implicated in vascular thrombosis processes related to COVID-19 [18].

Angiotensin Converting Enzyme 2 (ACE2) receptors that are present in various organs including vascular endothelium is the main site of entry for the virus into human body [19,20]. This endothelial cell injury mediates inflammatory cell recruitment and lead to dysregulated release of inflammatory mediators. The interaction between endothelial cells, macrophages, platelets, lymphocytes after viral binding to endothelial cells play an important role in activating clotting cascade and hypercoagulability [21]. Apoptosis, endothelial cell damage and necrosis have been seen in brain tissue on autopsy of patients with the original SARS - CoV virus [22].

Virchow's triad that was first described by Dr. Rudolph Virchow in 18th century, consists of three contributing factors for thrombus formation: endothelial injury, stasis and hypercoagulability [23]. Severe COVID-19 disease as described above satisfies two of the three factors predisposing to thrombus formation. The vast majority of critically ill patients with COVID-19 disease are immobile for prolonged duration causing blood stasis. This suggests hypercoagulability and thrombi formation to be the most plausible mechanism of ischemic strokes in COVID-19.

5. Diagnostic challenges

Early diagnosis is the key in stroke management given the time sensitive nature of management. The COVID-19 pandemic makes this difficult as there is presently a significant burden on health-care systems globally. Beyond adequate resources, LIS is a diagnostic challenge as patients are aphasic and cannot follow motor commands except for eye movements. In the critical care setting, the challenge intensifies as the patients are usually intubated and sedated. If a thorough awakening trial and neurological exam is not conducted, LIS can be easily misdiagnosed as delirium, encephalopathy, coma or even vegetative state [24]. A detailed neurological examination is the most important factor for diagnosis. In critically ill patients on mechanical ventilation, society of critical care medicine guidelines suggests targeting light sedation or daily interruption of sedation (DSI) [25]. DSI facilitates detailed assessment of underlying neurological status. DSI is not always tol-

erated secondary to agitation, discomfort, ventilator dyssynchrony or encephalopathy as was the case in our patient. MRI is an important diagnostic modality for diagnosis of LIS due to strokes.

6. Treatment

LIS is associated with the very high morbidity. Supportive care, respiratory hygiene, nutritional support, physical and occupational therapy are the main stay of treatment in LIS [24]. Speech pathology consultation, eye tracking devices and alphabet boards might be helpful with communication. In patients with LIS secondary to acute stroke, treatment aimed at stroke with anticoagulation and/or antiplatelet agents, cholesterol lowering medications for primary and secondary prevention should be considered. Full anticoagulation is a matter of debate in patients with COVID-19. A recent study demonstrated mortality benefit from anticoagulation in patients on mechanical ventilation [26]. In general, full intensity anticoagulation is not recommended unless other specific indication for anticoagulation exists [27]. All patients should be on prophylactic anticoagulation if there are no contraindications [27]. Large studies are needed to understand and develop anticoagulation guidelines in COVID-19.

7. Psychosocial and ethical implications

LIS is a tragic disease as patients usually do not have cognitive deficits and are thus aware of their clinical condition. Severe disability along with intact cognition leads to poor quality of life. Communicating with a LIS patient is a challenge, and patience should be practiced when analyzing these patients. Although, studies have noted satisfactory quality of life in LIS survivors; assumptions regarding poor quality of life in LIS could affect management as clinicians may be biased into less aggressive management [24,28]. Careful decisions should be made about tracheostomies and feeding tube placements after communicating with the patient and their surrogates.

8. Conclusion

The COVID-19 pandemic is a disease with a wide array of presentations. It has the ability to damage several organ systems, including the nervous system. The development of otherwise rare strokes, especially in young patients with no coagulopathy history is likely secondary to the hypercoagulable and hyper-inflammatory state seen in COVID-19. Patients on mechanical ventilation pose a challenge for a detailed neurological examination given other causes of mental status changes such as the use of sedatives, ICU delirium, along with other confounding factors like uremia, encephalopathy etc. We recommend daily sedation interruption trials along with a detailed neurological assessment. Large studies to establish guidelines regarding anticoagulation in COVID-19 patients are desperately needed.

Conflict of interest

No conflict of interest to be declared for either of the authors.

References

- [1] Lipsitch M, Swerdlow DL, Finelli L. Defining the epidemiology of Covid-19 – studies needed. *N Engl J Med* 2020;382(13):1194–6.
- [2] COVID-19 CORONAVIRUS PANDEMIC. <https://www.worldometers.info/coronavirus/>. Accessed.
- [3] Mao L, Jin H, Wang M, et al. Neurologic manifestations of hospitalized patients with coronavirus disease 2019 in Wuhan, China. *JAMA Neurol* 2020.
- [4] Avula A, Nalleballe K, Narula N, et al. COVID-19 presenting as stroke. *Brain Behav Immun* 2020.
- [5] Oxley TJ, Mocco J, Majidi S, et al. Large-vessel stroke as a presenting feature of Covid-19 in the young. *N Engl J Med* 2020.
- [6] Kenneth Maiese M. Locked-in Syndrome. Merck Manual Professional Version. <http://www.merckmanuals.com/professional/neurologic-disorders/coma-and-impaired-consciousness/locked-in-syndrome>. Accessed.
- [7] Love BB, Biller J. Chapter 22 – Neurovascular system. In: Goetz CG, editor. *Textbook of clinical neurology* (third edition). Philadelphia: W.B. Saunders; 2007. p. 405–34.
- [8] Khanna K, Verma A, Richard B. “The locked-in syndrome”: can it be unlocked?. *J Clin Gerontol Geriatrics* 2011;2(4):96–9.
- [9] Kloka FA, Kruijb MJHA, van der Meer NJM, Arbousd MS. Incidence of thrombotic complications in critically ill ICU patients with COVID-19. *Thromb Res* 2020.
- [10] Siddamreddy S, Thotakura R, Dandu V, Kanuru S, Meegada S. Corona Virus Disease 2019 (COVID-19) presenting as acute ST elevation myocardial infarction. *Cureus* 2020;12(4):e7782.
- [11] Danzi GB, Loffi M, Galeazzi G, Gherbesi E. Acute pulmonary embolism and COVID-19 pneumonia: a random association?. *Eur Heart J* 2020.
- [12] Cui S, Chen S, Li X, Liu S, Wang F. Prevalence of venous thromboembolism in patients with severe novel coronavirus pneumonia. *J Thromb Haemost* 2020.
- [13] Connell NT, Battinelli EM, Connors JM. Coagulopathy of COVID-19 and antiphospholipid antibodies. *J Thromb Haemost* 2020.
- [14] Zhang Y, Xiao M, Zhang S, et al. Coagulopathy and antiphospholipid antibodies in patients with Covid-19. *N Engl J Med* 2020;382(17):e38.
- [15] Chen R, Liang W, Jiang M, et al. Risk factors of fatal outcome in hospitalized subjects with coronavirus disease 2019 from a nationwide analysis in China. *Chest* 2020.
- [16] Guan WJ, Ni ZY, Hu Y, et al. Clinical characteristics of coronavirus disease 2019 in China. *N Engl J Med* 2020;382(18):1708–20.
- [17] Tan CW, Low JGH, Wong WH, Chua YY, Goh SL, Ng HJ. Critically ill COVID-19 infected patients exhibit increased clot waveform analysis parameters consistent with hypercoagulability. *Am J Hematol* 2020.
- [18] Spiezia L, Boscolo A, Poletto F, et al. COVID-19-related severe hypercoagulability in patients admitted to intensive care unit for acute respiratory failure. *Thromb Haemost* 2020.
- [19] Hoffmann M, Kleine-Weber H, Schroeder S, et al. SARS-CoV-2 cell entry depends on ACE2 and TMPRSS2 and is blocked by a clinically proven protease inhibitor. *Cell* 2020.
- [20] Huang C, Wang Y, Li X, et al. Clinical features of patients infected with 2019 novel coronavirus in Wuhan, China. *Lancet* 2020;395(10223):497–506.
- [21] Neumann FJ, Marx N, Gawaz M, et al. Induction of cytokine expression in leukocytes by binding of thrombin-stimulated platelets. *Circulation* 1997;95(10):2387–94.
- [22] Xiang-Hua Y, Le-Min W, Ai-Bin L, et al. Severe acute respiratory syndrome and venous thromboembolism in multiple organs. *Am J Respir Crit Care Med* 2010;182(3):436–7.
- [23] Bagot CN, Arya R. Virchow and his triad: a question of attribution. *Br J Haematol* 2008;143(2):180–90.
- [24] Laureys S, Pellas F, Van Eeckhout P, et al. The locked-in syndrome: what is it like to be conscious but paralyzed and voiceless?. *Prog Brain Res* 2005;150:495–511.
- [25] Devlin JW, Skrobik Y, Gélinas C, et al. Executive summary: clinical practice guidelines for the prevention and management of pain, agitation/sedation, delirium, immobility, and sleep disruption in adult patients in the ICU. *Crit Care Med* 2018;46(9):1532–48.
- [26] Paranjpe I, Fuster V, Lala A, et al. Association of treatment dose anticoagulation with in-hospital survival among hospitalized patients with COVID-19. *J Am Coll Cardiol* 2020.
- [27] Connors JM, Levy JH. COVID-19 and its implications for thrombosis and anticoagulation. *Blood* 2020.
- [28] Rousseau MC, Baumstarck K, Alessandrini M, Blandin V, Billette de Villemeur T, Auquier P. Quality of life in patients with locked-in syndrome: evolution over a 6-year period. *Orphanet J Rare Dis* 2015;10:88.