

Received: 2018.03.13  
Accepted: 2018.06.18  
Published: 2018.09.03

e-ISSN 1941-5923  
© Am J Case Rep, 2018; 19: 1053-1056  
DOI: 10.12659/AJCR.909956

## Agranulocytosis Induced by Vancomycin. Case Report and Literature Review

Authors' Contribution:  
Study Design A  
Data Collection B  
Statistical Analysis C  
Data Interpretation D  
Manuscript Preparation E  
Literature Search F  
Funds Collection G

ABCDEFG **Horacio di Fonzo**  
BDF **Melina Villegas Gutsh**  
BF **Augusto Castroagudin**  
BF **María Victoria Cabrera**  
ADF **Mariano E. Mazzei**  
ABDEF **Darío Rueda**

Department of Internal Medicine, Hospital de Clínicas "José de San Martín",  
University of Buenos Aires, Buenos Aires, Argentina

**Corresponding Author:** Horacio di Fonzo, e-mail: [horaciodef@gmail.com](mailto:horaciodef@gmail.com)  
**Conflict of interest:** None declared

**Patient:** Male, 38  
**Final Diagnosis:** Agranulocytosis induced by Vancomycin  
**Symptoms:** Fever • pain  
**Medication:** Vancomycin  
**Clinical Procedure:** Antibiotic treatment  
**Specialty:** Hematology

**Objective:** Unusual or unexpected effect of treatment

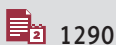
**Background:** Vancomycin has been used for decades to treat infections by Gram-positive bacteria, particularly those caused by methicillin-resistant staphylococci. Agranulocytosis is an infrequent complication of this antibiotic, postulated in its genesis a mechanism immune-mediated by antineutrophil antibodies and antineutrophil cytoplasmic antibodies (ANCA). Treatment includes discontinuing vancomycin, and granulocyte colony-stimulating factor administration.

**Case Report:** We present the case of a patient who developed agranulocytosis secondary to vancomycin during the treatment of an infectious endocarditis, which was reversed when the antibiotic was stopped. Concomitantly to neutropenia, he had ANCA positivity, which subsequently became negative.

**Conclusions:** Agranulocytosis induced by vancomycin is infrequent and generally occurs after day 12 of treatment. In most cases, like in our case, it is caused by an immune-mediated mechanism. More studies are needed to determine the pathogenic mechanism and the ANCA role in this adverse effect.

**MeSH Keywords:** Agranulocytosis • Antibodies, Antineutrophil Cytoplasmic • Vancomycin

**Full-text PDF:** <https://www.amjcaserep.com/abstract/index/idArt/909956>



1290



1



1



22



## Background

Agranulocytosis means the absence of granulocytes, although this term is often used to indicate severe degrees of neutropenia [1,2]. It can be linked to several causes and drug-induced agranulocytosis is a serious adverse event [2]. Among non-cytostatic drugs, some antibiotics can cause agranulocytosis, with a mortality of 5–10% [1,3].

Vancomycin was isolated from *Streptomyces orientalis* on the island of Borneo by Kornfield. In 1958, in the absence of an effective alternative, vancomycin was immediately approved for clinical use [4]. Vancomycin has been used for decades to treat infections by Gram-positive bacteria, particularly those caused by methicillin-resistant *Staphylococcus aureus* (MRSA) [5,6].

The first 2 reports of vancomycin-induced agranulocytosis were published by Dangerfield and colleagues in 1960, shortly after the introduction of vancomycin into clinical practice [3,7]. The pathogenesis of this complication has not been elucidated. The available data support the hypothesis of a peripheral mechanism mediated by antibodies and direct toxicity to the bone marrow [3,8,9].

We present the case of a patient with a diagnosis of infective endocarditis treated with vancomycin who developed agranulocytosis, with positivity of antineutrophil cytoplasm antibodies (ANCA) simultaneous to neutropenia.

## Case Report

A 38-year-old male patient, with a history of diabetes mellitus type 2 without treatment, was admitted for an abscess in the right kidney. The abscess was drained, and a culture of the surgical material was obtained, and a blood culture growth identified MRSA with a minimum inhibitory concentration (MIC) to vancomycin of 1 µg/mL. Intravenous vancomycin was started.

At admission the patient's serum glycemia was 135 mg/dL, glycosylated hemoglobin 7%, and serum sodium, potassium, creatinine, and urea were normal.

A transesophageal echocardiogram showed a mobile homogeneous mass with regular edges of 10×7 mm compatible with vegetation on the posterior leaflet of the mitral valve. With the diagnosis of infective endocarditis on a native mitral valve, he continued with vancomycin. Measurements of plasmatic vancomycin levels were: 20 µg/mL, 15 mcg/mL and 15 mcg/mL, with 4.5 grams and 4 grams per day of vancomycin, respectively.

The evolution was favorable, without cardiovascular complications and the control blood cultures were negative on the third day of antibiotics. On day 28 of treatment, a decrease in neutrophil count was detected. Neutropenia was progressive and accentuated on days 30 and 31 up to a value of 60 neutrophils per mm<sup>3</sup> and no changes in the monocyte count was observed (Table 1). The medications used in the patient were vancomycin, prophylactic sodium heparin, omeprazole, insulin, and paracetamol.

Due to the possibility of neutropenia induced by drugs, the Naranjo algorithm was applied, which showed a probable adverse effect (7/10) in favor of vancomycin. The peripheral blood smear showed absence of granulocytes (Figure 1), and the bone marrow examination showed normality of the precursors of the 3 series.

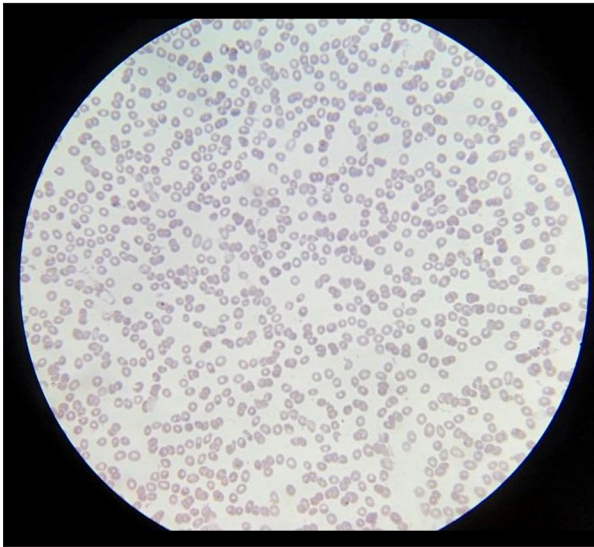
During neutropenic period, atypical positive ANCA (title 1/80) was detected by indirect immunofluorescence. Vancomycin was changed to daptomycin and 2 subcutaneous doses of granulocyte colony-stimulating factor (G-CSF) at 60 MU was indicated. The granulocyte count was normalized on the second day of vancomycin withdrawal. Two months after the event, the ANCA determination was negative.

## Discussion

Drug-induced agranulocytosis is a serious entity that implies an increased risk of infections [3]. Agranulocytosis or severe neutropenia is defined by an absolute neutrophil count <500/mm<sup>3</sup> [1,2]. In Europe, the annual incidence of drug-induced agranulocytosis ranges from 1.6 to 9.2 cases per million population [2]. Mortality rates of agranulocytosis induced

**Table 1.** Leukocyte count evolution.

Cells/mm <sup>3</sup>	Days of treatment							
	Day 1	Day 13	Day 23	Day 26	Day 28	Day 30	Day 31	Day 33
Leucocytes	14.890	10.200	6.310	3.990	4.580	3.790	3.700	8.140
Neutrophils	12.120	7.750	3.670	1.780	620	210	60	4.780
Lymphocytes	1.790	1.520	1830	1.430	3.080	2.370	2.300	2.180
Monocytes	890	880	700	780	850	1.190	1.340	1.180



**Figure 1.** Blood smear (40×). Giemsa. Absence of granulocytes.

by non-chemotherapeutic drugs were reported up to 16% in a retrospective review. In cases of agranulocytosis caused by antibiotics, mortality reported is around 5% [2,3].

Despite an extensive list of medications that cause neutropenia, only propylthiouracil, methimazole, cocaine/levamisole, minocycline, and hydralazine were associated with ANCA and neutropenia [8,10]

Vancomycin is used to treat MRSA infections and patients with penicillin allergy. [5,6,11], several weeks of therapy with this antibiotic are required in infections such as endocarditis and chronic osteomyelitis [9,11]. The adverse reactions to vancomycin include fever, red man syndrome, nephrotoxicity, ototoxicity, and rarely neutropenia. Retrospective analyses in hospitalized patients have estimated that the incidence of vancomycin induced neutropenia is 2% [4,6,12].

In a retrospective study that included 114 patients treated with vancomycin, 3.5% had severe neutropenia, and this was presented on day 26 ( $\pm 15$  days) after the start of treatment. There was no association between the total dose of vancomycin and its serum concentrations with the development of neutropenia [9]. In a review by Black et al. [3] and in a review by Segarra-Newnham and Tagoff [5], vancomycin-induced neutropenia was associated with a therapy lasting more than 7 days, with most cases appearing after day 20 of treatment. The neutrophil count normalizes, usually, in the first week after the suspension of vancomycin [5,13].

The specific mechanisms behind the development of this complication have not been fully elucidated, although the hypotheses include immune-mediated neutropenia and direct toxicity of bone marrow [3,6,10,14]. The development of antineutrophil

antibodies, and more rarely ANCA supports the immune origin of agranulocytosis by drugs [5,9,10,15,16].

However, the direct role of the ANCA in the development of neutropenia is not entirely clear. The migration of cytoplasmic antigens proteinase 3 (PR3), myeloperoxidase (MPO), and cathepsin G to the neutrophil cell surface promoted by endogenous pyrogens, allow exposure to the immune system [8,10]. Other mechanisms possibly involved are suppression of granulocytes production, complement dependent cytotoxicity, and agglutination of neutrophils by antineutrophil antibodies [10,17].

Akamizu et al. performed *in vitro* cytotoxicity tests in serum of a patient with neutropenia and ANCA positive secondary to propylthiouracil, demonstrating that ANCA lysed neutrophils through a complement-dependent mechanism but not by antibody dependent cellular cytotoxicity [8].

Grayson et al. reported a case of vasculitis ANCA-associated autoimmune neutropenia with specificity against PR3 and MPO. They found only 24 cases in the literature of neutropenia associated with ANCA secondary to drugs, none of which was vancomycin [10].

As for the direct bone marrow cytotoxic effect, there are also arguments against it, such as the time it takes to develop neutropenia induced by vancomycin and the lack of a dose dependent effect on the neutrophil count [5,18]. In addition, the rapid recovery of neutrophils after stopping the drug or administering G-CSF suggests that the myeloid bone marrow precursors are intact [14].

In our case, there was no mechanism of bone marrow toxicity due to the presence of normal myeloid precursors in bone marrow examination. We believe that ANCA may have intervened in agranulocytosis, since they were detected during neutropenia and not after vancomycin suspension. The rapid recovery of granulocytes after the suspension of the antibiotic is an element in favor of vancomycin as a causative agent [5,6,13]. The application of a method that considers causality of an adverse drug reaction, such as the Naranjo algorithm, is a useful and simple tool for these cases [19].

As part of the treatment of agranulocytosis, G-CSF can be used since it shortens the duration of neutropenia and implies fewer risks of infections and fatal complications [1,2,11,14,20].

Regarding the antibiotic scheme, European and American guidelines for infective endocarditis recommends daptomycin as an alternative to vancomycin [21,22].

## Conclusions

The agranulocytosis induced by vancomycin is a known but infrequent adverse effect of this drug. Usually it occurs after day 12 of treatment. In our case, like in most reported cases, it is caused by an immune-mediated mechanism and among the possible immune mechanisms involved ANCAs could have a pathogenic role. However, there are few previous reports that link ANCA with vancomycin-induced agranulocytosis. More studies are needed to determine the pathogenic mechanism of agranulocytosis mediated by ANCA.

## References:

1. Andersohn F, Konzen C, Garbe E: Systematic review: Agranulocytosis induced by nonchemotherapy drugs. *Ann Intern Med*, 2007; 146(9): 657–65
2. Andrés E, Mourrot-Cottet R: Non-chemotherapy drug-induced neutropenia – an update. *Expert Opin Drug Saf*, 2017; 16(11): 1235–42
3. Black E, Lau T, Ensom MH: Vancomycin-induced neutropenia: Is it dose- or duration-related? *Ann Pharmacother*, 2011; 45(5): 629–38
4. Levine D: Vancomycin: A history. *Clin Infect Dis*, 2006; 42(Suppl. 1): 5–12
5. Segarra-Newnham M, Tagoff S: Probable vancomycin-induced neutropenia. *Ann Pharmacother*, 2004; 38(11): 1855–59
6. Lopes Rocha J, Kondo W, Domingues Kuchiki Baptista MI et al: Uncommon vancomycin: Induced side effects. *Brazilian J Infect Dis*, 2002; 6(4): 196–200
7. Dangerfield HG, Hewitt WL, Monzon OT et al: Clinical use of vancomycin. In: Grey P (ed.), *Antimicrobial Agents Annual 1960: Proceedings of the Conference on Antimicrobial Agents Held in Washington, D.C. October 26–28, 1960 Under the Chairmanship of Lloyd G. Herman*. New York: Plenum Press, 1960; 428
8. Akamizu T, Ozakis, Hiratani H et al: Drug-induced neutropenia associated with anti-neutrophil cytoplasmic antibodies (ANCA): Possible involvement of complement in granulocyte cytotoxicity. *Clin Exp Immunol*, 2002; 127(1): 92–98
9. Pai MP, Mercier RC, Koster SA: Epidemiology of vancomycin-induced neutropenia in patients receiving home intravenous infusion therapy. *Ann Pharmacother*, 2006; 40(2): 224–28
10. Grayson PC, Sloan JM, Niles JL et al: Antineutrophil cytoplasmic antibodies, autoimmune neutropenia, and vasculitis. *Semin Arthritis Rheum*, 2011; 41(3): 424–33
11. Crozier JA: Vancomycin induced neutropenia: A case report. *J Clin Case Reports*, 2015; 5(1): 1–3
12. Farber BF, Moellering RC Jr.: Retrospective study of the toxicity of preparations of vancomycin from 1974 to 1981. *Antimicrob Agents Chemother*, 1983; 23(1): 138–41
13. Shah AB, Dharmarajan TS: Letter to the Editor: Neutropenia, a dilemma with etiology vancomycin or sepsis? *Infect Dis Clin Pract*, 2007; 15(5): 354
14. Lai KK, Kleinjan J, Belliveau P: Vancomycin-induced neutropenia treated with granulocyte colony-stimulating factor during home intravenous infusion therapy. *Clin Infect Dis*, 1996; 23(4): 844–45
15. Loschi M, Jouen F, Kerleau JM et al: Severe acquired neutropenia associated with anti-proteinase 3 antibodies. *Acta Haematol*, 2011; 126(4): 211–13
16. Coppo P, Ghez D, Fuentes V et al: Antineutrophil cytoplasmic antibody-associated neutropenia. *Eur J Intern Med*, 2004; 15(7): 451–59
17. Weitzman SA, Stossel TP: Drug-induced immunological neutropenia. *Lancet*, 1978; 1(8073): 1068–72
18. Schwartz MD: Vancomycin-induced neutropenia in a patient positive for an antineutrophil antibody. *Pharmacotherapy*, 2002; 22(6): 783–88
19. Naranjo CA, Busto U, Sellers EM et al: A method for estimating the probability of adverse drug reactions. *Clin Pharmacol Ther*, 1981; 30(2): 239–45
20. Van Der Klauw MM, Wilson JHP, Stricker BH: Drug-associated agranulocytosis: 20 years of reporting in The Netherlands (1974–1994). *Am J Hematol*, 1998; 57(3): 206–11
21. Baddour LM, Wilson WR, Bayer AS et al: Infective endocarditis in adults: Diagnosis, antimicrobial therapy, and management of complications: A scientific statement for healthcare professionals from the American Heart Association. *Circulation*, 2015; 132(15): 1435–86
22. Habib G, Lancellotti P, Antunes MJ et al: [Guide of the European Society of Cardiology 2015 on the treatment of infectious endocarditis]. *Rev Española Cardiol*, 2016; 69(1): 1–49 [in Spanish]

The treatment of agranulocytosis by vancomycin involves the suspension of this antibiotic and the administration of an alternative agent, together with G-CSF administration. It is recommended to monitor the hematological parameters at least once a week in patients receiving prolonged intravenous vancomycin therapy.

## Conflict of interest

None.