

Is cemented revision total hip arthroplasty a reasonable treatment option in an elderly population?

Philipp Born,¹ Isabella Manzoni,¹
Thomas Ilchmann,^{1,2} Martin Clauss^{1,3}

¹Clinic for Orthopedic and Trauma Surgery, Kantonsspital Baselland, Liestal; ²Hirslanden Klinik Birshof, Münchenstein; ³Department of Orthopedics and Traumatology, University Hospital Basel, University of Basel, Switzerland

Abstract

Revision THA is increasingly performed especially in the elderly population. The surgeon's challenge is to provide a solution that supports immediate full weight-bearing, despite poor bone quality. Shape-closed revision stems facilitate that by combining cement fixation with additional press-fit anchoring. The design tolerates varying cement mantle thickness and inconsistent cancellous bone lining of the femoral canal. Following that philosophy, we present our mid-term results using a long version of a cemented Charnley-Kerboull type stem. From 2010 to 2017, 38 long Charnley-Kerboull revision stems (Centris[®], Mathys European Orthopaedics, Bettlach, Switzerland) were implanted and followed prospectively. Surgery was performed via a Hardinge approach in supine position with a third generation cementing technique. Patients were mobilized using full-weight bearing as early as possible. Survival was determined for stem revision for aseptic loosening and stem and/or cup revision for any reason. 20 stems had a minimum follow-up (f/u) of 2 years and were included for further radiological analysis. Detailed subsidence analysis as an early predictor for later aseptic loosening was performed using EBRA-FCA software. Further, the presence of osteolysis and cement debonding was evaluated. Mean follow-up was 4 years. No patient was lost to f/u. 18 died of causes unrelated to THA. Stem survival was 100%. Survival for any re-operation was 82.2% (two early infections, one soft-tissue debridement, one cup exchange for recurrent dislocations). None of the cases revised for septic loosening showed signs of persistent infection at final f/u. EBRA-FCA revealed two oligosymptomatic cases of subsidence of 5mm and 6mm over a course of 2 and 12 months,

respectively, with stable implants thereafter. Neither required revision. There was no development of osteolysis or debonding. The stem provides a reliable early full-weight bearing solution for revision THA with excellent mid-term survival in an elderly population. Even in two cases where subsidence was present, mobility was not impaired and re-revision could be avoided.

Introduction

Revision THA is increasingly performed, especially in an elderly population (>75 years). In these cases, the surgeon is challenged to provide a solution that supports immediate full weight bearing, despite poor bone quality. Cemented stems used for primary THA achieve that goal with mechanical failure being negligible in the first decade.^{1,2} In revision scenarios however, cancellous bone for cement interdigitation, especially in the metaphysis, is frequently absent. In these cases additional impaction bone grafting may improve implant stability with excellent long-term results,^{3,4} but is demanding and associated with a high rate of periprosthetic fractures.⁵ Alternatively, cemented revision stems following a shape-closed design, yield excellent long-term results by combining cement fixation with press-fit anchoring (Figure 1).⁶ The initial description of this so-called "French Paradox" by Kerboull,⁷ even advocates the removal of cancellous bone from the medullary canal using a curette, with excellent long-term survival.⁸ Recently a discussion arose whether the French Paradox actually exists concerning cemented stems function despite a thin cement mantle and lack of cancellous bone.^{9,10} Apart from this discussion cemented stem revision is an attractive option in old and frail patients with poor bone stock that would allow immediate full weight bearing.¹¹ Following this philosophy, we have used a long version of the Charnley-Kerboull stem (Centris[®], Mathys European Orthopaedics, Bettlach, Switzerland; Figure 1) for revision THA and failed proximal femoral fracture osteosynthesis in patients with poor bone quality that require immediate full weight-bearing.

Aim of this study was to analyse the mid-term survival of the Centris[®] stem with special emphasis on radiological changes indicative for pending failure and stem subsidence.

Correspondence: Martin Clauss, Clinic for Orthopedics and Trauma Surgery, University Hospital Basel, Spitalstrasse 21, 4031 Basel, Switzerland.

E-mail: martin.clauss@usb.ch

Key words: THA, Revision, cemented, French Paradox, Charnley-Kerboull, elderly patients.

Contributions: the authors contributed equally.

Conflict of interest: the authors declare no potential conflict of interest.

Funding: none.

Received for publication: 31 July 2019.

Accepted for publication: 25 August 2019.

This work is licensed under a Creative Commons Attribution NonCommercial 4.0 License (CC BY-NC 4.0).

©Copyright: the Author(s), 2019

Licensee PAGEPress, Italy

Orthopedic Reviews 2019;11:8263

doi:10.4081/or.2019.8263

Materials and Methods

Patients

The patient data is extracted from our in-house hip registry, which was approved by the local ethics committee (EKNZ 2015-393). Inclusion criteria were usage of the long version of the cemented Centris[®] stem in primary and revision arthroplasties. Excluded were surgeries with another implant, second Centris[®] stem revisions (same hip already included) and no informed consent. From 2010 to 2017, 38 stems were implanted. Patients were followed prospectively at 6 and 12 weeks and at 1, 2, 5 years and every 5 years thereafter. At each follow-up a clinical and radiological examination was performed. Mean age at index surgery was 78 ([74-87], SD 3) years. 16 male and 22 females were included. 18 patients died during follow up, two of which in the immediate postoperative period (one mechanical ileus, one central venous catheter associated endocarditis).

Preoperative femoral bone defects were classified according to Paprosky,¹² using the last radiograph before index surgery.

Periprosthetic joint infections (PJI) after index surgery were recorded as defined elsewhere and in case of index surgery being performed due to PJI compared with previous infection parameters.¹³ We recorded monomicrobial vs. polymicrobial infections, type of microorganism(s), type of PJI (acute vs chronic) and type of treatment

(debridement and implant retention (DAIR), one- or two-stage exchange).¹⁴

Method

Surgery was performed via a Hardinge approach in supine position using third generation cementing technique (distal cement restrictor, Jet-Lavage and pressurizer; Palacos R+G bone cement, Heraeus, Wehrheim, Germany). In cases where the cement restrictor was below the femoral isthmus, it was secured from subsiding by placing a percutaneous Kirschner-wire just below in a bicortical manner. Patients were mobilized using full-weight bearing as early as possible using two crutches.

Radiological assessment

Standardized anterior-posterior (a.p.) views centered on the symphysis showing the entire stem were taken. For analysis, the 12-week postoperative radiograph was compared to the latest follow-up. Radiographs were analyzed according to the Gruen-Zone system. Osteolysis was defined as a progressive, newly developed endosteal bone loss with a diameter greater than 3 mm at the cement-bone-interface.^{15,16} Debonding was defined as a radiolucent line at the prosthesis-cement interface not visible on the first postoperative radiograph.¹⁵ Detailed subsidence analysis was performed with EBRA-FCA software.¹⁷ More than 2 mm were considered abnormal.¹⁵ Stems were rated radiographically loose in case of circumferential osteolysis/radiolucencies in all Gruen zones and/or excessive subsidence (>10mm).^{18,19}

Statistical analysis

Survival analysis was performed using Kaplan-Meier analysis for the following endpoints: i) aseptic loosening of the stem, ii) re-revision of the stem and/or cup (including exchange of the liner) for any reason. Excellent survival rates were defined as >95%-level at 10 years (NICE criteria).

Results

Most cases were operated due to aseptic

loosening of the stem (Table 1). Preoperative femoral bone defects are shown in Table 2. Mean follow-up was 4 years ([2-6], SD 1). No patient was lost to f/u. Stem survival for aseptic loosening was 100%. Survival for any re-operation was 82.2% (95%CI 69.1-95.3%) (Figure 2): During follow-up one cup was revised due to recurrent dislocations three weeks after index surgery with an uneventful course thereafter.

Two periprosthetic fractures occurred 4 and 14 months after index surgery (both Vancouver C). The first after a two-stage exchange for PJI (Figure 3). Open reduction

Table 1. Indications for Centris® stem implantation.

Indication	No.
Aseptic loosening	16
Septic loosening	8 (5 one-stage / 3 two-stage exchanges)
Fractures	9
Osteoarthritis	2
Bone metastasis	2
Recurrent dislocation	1

Table 2. Distribution of femoral defects prior to index surgery according to the Paprosky classification.¹²

Paprosky grade	All stems	f/u > 2 years
I	13	4
II	22	14
IIIa	3	2
IIIb	0	0
IV	0	0

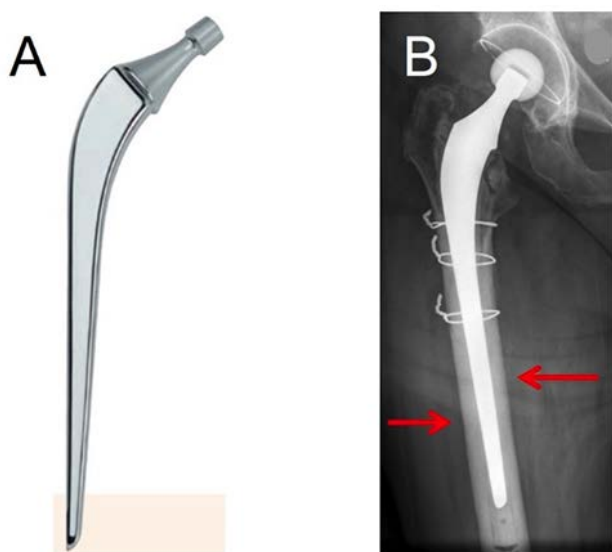


Figure 1. A) Charnley-Kerboull revision stem (Centris®, Mathys, Switzerland). B) Thin cement mantle surrounding the stem with additional press-fit fixation (red arrows).

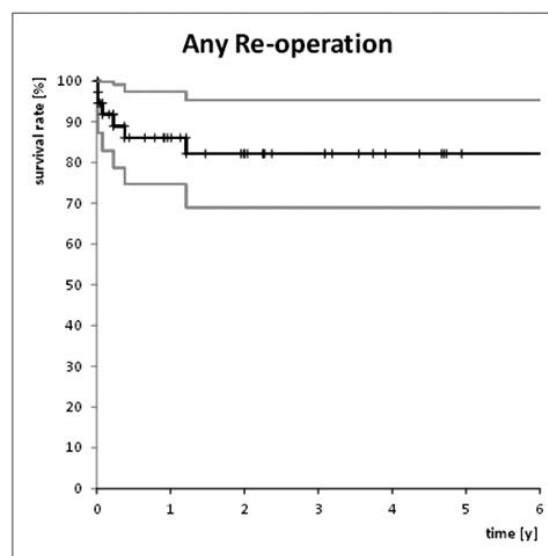


Figure 2. Kaplan-Meier stem survival for any revision: 82.2% at 4 years (95% CI: 69.1-95.3%).

and internal fixation (ORIF) failed at two months, due to plate avulsion of the proximal fragment. Re-revision resulted in uneventful fracture healing. The patient is ambulatory on a walker. Remaining symptoms consist of tolerable pain along the lateral thigh.

The second periprosthetic fracture occurred 14 months postoperatively due to a fall. ORIF resulted into breakage of the plate six months after surgery. Re-revision lead to complete fracture healing. The patient is oligosymptomatic and ambulatory on a walker.

Two PJI occurred and were diagnosed two and three weeks after index surgery (one monomicrobial (*S. epidermidis*), one polymicrobial (*S. epidermidis*, *E. faecalis*)). Both were treated with DAIR as described elsewhere.¹³ There were no signs of persistent infection at the final f/u (inconspicuous soft-tissues, no resting pain, no general symptoms, normal Leukocytes/CRP). Further, one soft-tissue debridement was performed with suspected PJI one week postoperatively due to persistent wound leakage. Intraoperative samples ruled out PJI.

Twenty stems had a minimum f/u of 2 years and were included for further radiological analysis. Radiological analysis showed no development of osteolysis or debonding over the entire f/u. 15 of the 20 hips (75%) with a minimum follow-up of 2 years had at least 4 radiographs and could be analysed with EBRA-FCA (Figure 4). The average subsidence was 2mm (95%CI 0-6mm) after 2 years. Two stems, one implanted primarily for a proximal femoral fracture and the other in a revision case for aseptic loosening, showed a detectable subsidence of 6mm and 5mm respectively over a course of 2 and 12 months with stable implants thereafter (Figure 4). Each case had severe proximal metadiaphyseal bone defects preoperatively, rated 3a according to Paprosky.¹² Both were oligo-symptomatic and did not require re-revision.

Discussion

Our study demonstrates the reliability of a long Charnley-Kerboull stem for revision arthroplasties and failed proximal femoral osteosynthesis. Poor bone stock and immediate full weight bearing did not impair mid-term stem survival (100%). Subsidence >2mm as an early sign for pending failure was scarce and did not correlate with increased pain or a decreased mobility,²⁰ thus re-revision was not performed. Compared to the literature our stem

survival is comparable to standard length Charnley-Kerboull implants in primary and revision THA (>95%).^{8,21-23}

Survival for any revision was 82.2% after mean of 4 years. This appears low, however, our collective consists solely of elderly, multimorbid patients in a revision setting. Despite these risk factors stem survival was not affected. The revisions included two periprosthetic fractures four and 14 months after index surgery (both Vancouver C). The first one was potentially iatrogenic, as the femur broke around a diaphyseal cortical window made for cement removal in a septic two-stage exchange. Literature identifies periprosthetic fractures as quite frequent. They occur in 5.8% of cemented and 18.6% of uncemented implants.²⁴ The other fracture was due to an adequate trauma. Both were treated with implant preserving ORIF. They failed due to insufficient plate fixation in the proximal stem bearing fragment. Literature reports a high complication rate for ORIF with 13% fixation failures and new fractures.²⁵

One cup needed replacement three weeks after index surgery due to recurrent dislocations. No other complications were

observed on the acetabular side which goes in accordance with other published studies.^{21,23}

Further, two cases of PJI (5%) were treated successfully with DAIR.¹³ No signs of persistent infection were observed at the last f/u. One hip with ongoing wound secretion was debrided one week after index surgery due to suspected PJI. No bacterial growth was detected in the cultivated soft-tissue biopsies. Our infection rate is comparable with results of larger studies where PJI after revision THA was between 3.2% and 8%.^{26,27}

Radiological changes (osteolysis and/or debonding) were not detected during follow-up. This is the expected course of a well cemented stem at mid-term follow-up.

Two out of 20 stems showed a subsidence >2mm which was defined as a risk factor for later aseptic loosening.²⁰ Both stems showed an initial subsidence with consecutive stabilisation. The investigated Centris stem, despite following the "French Paradox" philosophy, has a high polished surface finish (e.g. roughness <0.04um), thus during initial subsidence only pitting wear should occur without substantial

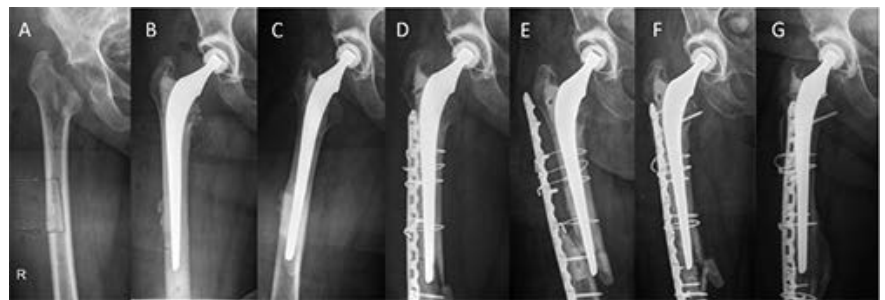

Figure 3. Potentially iatrogenic periprosthetic fracture (C), as the femur broke around a diaphyseal cortical window (A). ORIF failed at two months, due to plate avulsion off the proximal fragment (E). Re-ORIF (F) resulted into uneventful healing (G).

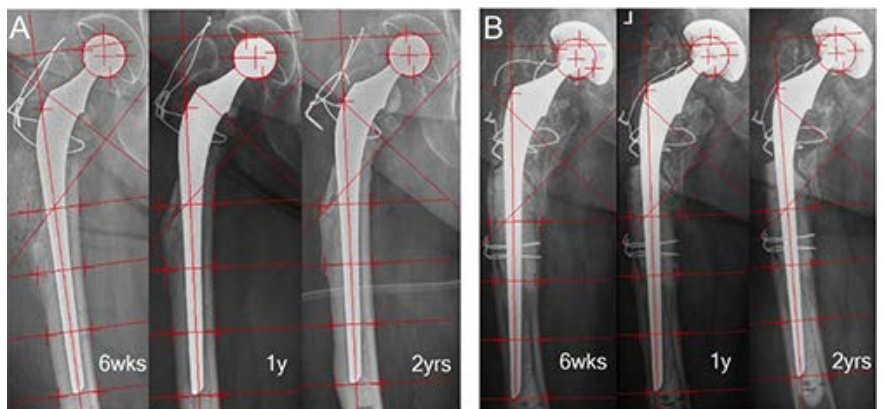


Figure 4. Subsidence analysis with EBRA-FCA software: Two cases of subsidence of (A) 5mm over 2 months and (B) 6mm over 12 months with stable implants thereafter.

destruction of the thin or even incomplete cement mantle.²⁸ From our mid-term data it remains unclear whether this might be a problem during long-term follow-up and further monitoring of these stems remains necessary.^{10,29}

Conclusions

The Centris® stem provides a reliable early full-weight bearing solution for revision THA with excellent mid-term survival in a high-aged population. Even in two cases with subsidence, mobility was not impaired and re-revision up to latest f/u could be avoided.

References

- Junnila M, Laaksonen I, Eskelinen A, et al. Implant survival of the most common cemented total hip devices from the Nordic Arthroplasty Register Association database. *Acta Orthop* 2016;87:546-53.
- Schmitz MW, Bronsema E, de Kam DC, et al. Results of the cemented Exeter femoral component in patients under the age of 40 : an update at ten to 20 years' follow-up. *Bone Joint J* 2017; 99B:192-8.
- Te Stroet MA, Rijnen WH, Gardeniers JW, et al. Satisfying Outcomes Scores and Survivorship Achieved With Impaction Grafting for Revision THA in Young Patients. *Clin Orthop Relat Res* 2015;473:3867-75.
- Schreurs BW, Arts JJ, Verdonschot N, et al. Femoral component revision with use of impaction bone-grafting and a cemented polished stem. *J Bone Joint Surg Am* 2005;87:2499-507.
- Ornstein E, Atroshi I, Franzen H, et al. Early complications after one hundred and forty-four consecutive hip revisions with impacted morselized allograft bone and cement. *J Bone Joint Surg Am* 2002;84-A:1323-8.
- Scheerlinck T, Casteleyn PP. The design features of cemented femoral hip implants. *J Bone Joint Surg Br* 2006;88:1409-18.
- Kerboul M. The Charnley-Kerboul prosthesis. In: Postel M, Kerboul M, Evrad J, Courpied JP, editors. *Total hip replacement*. Heidelberg: Springer; 1987. pp. 13-7.
- Kerboul L, Hamadouche M, Courpied JP, Kerboul M. Long-term results of Charnley-Kerboul hip arthroplasty in patients younger than 50 years. *Clin Orthop Relat Res* 2004:112-8.
- Numata Y, Kaneuji A, Kerboul L, et al. Biomechanical behaviour of a French femoral component with thin cement mantle: The 'French paradox' may not be a paradox after all. *Bone Joint Res* 2018;7:485-93.
- Clauss M, Breusch SJ. The 'French paradox' may not be a paradox after all – but for what reason? *Bone Joint Res* 2019.
- Unnanuntana A, Dimitroulias A, Bolognesi MP, et al. Cementless femoral prostheses cost more to implant than cemented femoral prostheses. *Clin Orthop Relat Res* 2009;467:1546-51.
- Aribindi R, Barba M, Solomon MI, et al. Bypass fixation. *Orthop Clin N Am* 1998;29:319-29.
- Sendi P, Lotscher PO, Kessler B, et al. Debridement and implant retention in the management of hip periprosthetic joint infection: outcomes following guided and rapid treatment at a single centre. *Bone Joint J* 2017;99B:330-6.
- Zimmerli W, Trampuz A, Ochsner PE. Prosthetic-joint infections. *N Engl J Med* 2004;351:1645-54.
- Clauss M, Luem M, Ochsner PE, Ilchmann T. Fixation and loosening of the cemented Muller straight stem: a long-term clinical and radiological review. *J Bone Joint Surg Br* 2009;91:1158-63.
- Joshi AB, Markovic L, Ilchmann T. Polyethylene wear and calcar osteolysis. *Am J Orthop* 1999;28:45-8.
- Krismer M, Bauer R, Tschupik J, Mayrhofer P. EBRA: a method to measure migration of acetabular components. *J Biomech* 1995;28:1225-36.
- Harris WH, McCarthy JC, Jr., O'Neill DA. Femoral component loosening using contemporary techniques of femoral cement fixation. *J Bone Joint Surg Am* 1982;64:1063-7.
- Clauss M, Bolliger L, Brandenberger D, et al. Similar effect of stem geometry on radiological changes with 2 types of cemented straight stem. *Acta Orthop* 2015:1-6.
- Krismer M, Biedermann R, Stockl B, et al. The prediction of failure of the stem in THR by measurement of early migration using EBRA-FCA. *Einzel-Bild-Roentgen-Analyse-femoral component analysis*. *J Bone Joint Surg Br* 1999;81:273-80.
- El Masri F, Kerboul L, Kerboul M, et al. Is the so-called 'French paradox' a reality?: long-term survival and migration of the Charnley-Kerboul stem cemented line-to-line. *J Bone Joint Surg Br* 2010;92:342-8.
- Kerboul L, Hamadouche M, Kerboul M. Impaction grafting in association with the Charnley-Kerboul cemented femoral component: operative technique and two- to 16-year follow-up results. *J Bone Joint Surg Br* 2009;91:304-9.
- Nich C, Courpied JP, Kerboul M, et al. Charnley-Kerboul total hip arthroplasty for osteonecrosis of the femoral head a minimal 10-year follow-up study. *J Arthroplasty* 2006;21:533-40.
- Abdel MP, Houdek MT, Watts CD, et al. Epidemiology of periprosthetic femoral fractures in 5417 revision total hip arthroplasties: a 40-year experience. *Bone Joint J* 2016;98:468-74.
- Wu HB, Yan SG, Wu LD, et al. Combined use of extensively porous coated femoral components with onlay cortical strut allografts in revision of Vancouver B2 and B3 periprosthetic femoral fractures. *Chinese Med J* 2009;121:2612-5.
- Hanssen AD, Rand JA. Evaluation and treatment of infection at the site of a total hip or knee arthroplasty. *Instr Course Lect* 1999;48:111-22.
- Wyles CC, Van Demark RE 3rd, Sierra RJ, Trousdale RT. High rate of infection after aseptic revision of failed metal-on-metal total hip arthroplasty. *Clin Orthop Relat Res* 2014;472:509-16.
- Howell JR Jr, Blunt LA, Doyle C, et al. In vivo surface wear mechanisms of femoral components of cemented total hip arthroplasties: the influence of wear mechanism on clinical outcome. *J Arthroplasty* 2004;19:88-101.
- Pallaver A, Zwicky L, Bolliger L, et al. Long-term results of revision total hip arthroplasty with a cemented femoral component. *Arch Orthop Trauma Surg* 2018;138:1609-16.