

Antiviral therapy leads to histological improvement of HBeAg-negative chronic hepatitis B patients

Nikolaos Papachrysos^a, Prodromos Hytiroglou^b, Lavrentios Papalavrentios^a, Emmanouil Sinakos^a, Ioannis Kouvelis^a, Evangelos Akriviadis^a

Aristotle University, Medical School, Thessaloniki, Greece

Abstract

Background We investigated hepatic histological changes in a cohort of HBeAg-negative chronic hepatitis B (CHB) patients (n=50) under long-term antiviral treatment in clinical practice.

Methods Liver biopsies were obtained at baseline and after prolonged antiviral treatment with lamivudine (42/50), entecavir (6/50), telbivudine (1/50), or tenofovir (1/50). Due to viral resistance to lamivudine a nucleotide analog was added in 17 patients (adefovir n=11; tenofovir n=6). Twenty-two patients had initially received a 12-month course of pegylated interferon- α , followed by nucleos(t)ide analogs. Necroinflammatory activity was graded as 1-minimal (histological activity index [HAI]: 0-3), 2-mild (HAI: 4-8), 3-moderate (HAI: 9-12), or 4-severe (HAI: 13-18); staging was performed according to the METAVIR system.

Results Twenty-seven patients were male and 23 female; mean age was 46.9 \pm 10.7 years. Mean interval between biopsies was 72.6 \pm 27.8 months. Improvement in activity was observed in 31/42 patients (74%) (mean drop -1.1 grade, SD=1.0), and in histological staging in 24/50 patients (48%) (mean drop -0.56 stage, SD=0.73). Importantly, the repeat biopsies of 5/10 patients with initial stage F4 were classified as F3 (n=3), F2 (n=1) or F1 (n=1). Worsening of staging was observed in only one patient. Development of resistance to lamivudine had no significant effect on stage improvement.

Conclusions Sustained hepatitis B virus suppression with antiviral treatment in HBeAg-negative CHB patients leads to reduction in necroinflammatory activity and improvement in staging, regardless of transient viral breakthrough. Potent antivirals in common clinical use for CHB can even lead to regression of fibrous septa and architectural improvement of cirrhotic livers.

Keywords Antiviral treatment, chronic hepatitis B, cirrhosis, fibrosis, nucleos(t)ide analogs

Ann Gastroenterol 2015; 28 (3): 374-378

Introduction

Chronic hepatitis B (CHB) infection affects an estimated 400 million people worldwide and continues to be an important cause of morbidity and mortality [1]. CHB often leads to cirrhosis and hepatocellular carcinoma (HCC). It has been shown that progression to cirrhosis in CHB is correlated

with the hepatitis B virus (HBV) levels, ranging from 4.5% in patients with low HBV DNA levels (<300 copies/mL) to 36.2% in patients with high viral replication (>10⁶ copies/mL), after a mean follow up of 11 years [2]. Other studies have shown that significant fibrosis is prevalent in a large proportion of HBeAg-negative patients with high viremia and persistently normal alanine aminotransferase (ALT) [3,4].

Liver fibrosis represents the wound healing response of the liver to persistent liver injury. Most importantly, chronic inflammation leads to the transformation of hepatic stellate cells (HSCs) from the quiescent status (vitamin A-storing cells) to activated myofibroblasts secreting matrix proteins, including collagens [5-8]. Until recently, it was believed that fibrosis occurring in the course of chronic hepatic diseases is irreversible. However, the ability of HSCs to apoptose or return to the quiescent phase, in conjunction with the regenerative capacity of hepatic cells, led to the conclusion that liver fibrosis is reversible [9-11]. This has already been shown in animal models, in which removing the underlying source of liver injury

^aFourth Unit of Internal Medicine (Nikolaos Papachrysos, Lavrentios Papalavrentios, Emmanouil Sinakos, Ioannis Kouvelis, Evangelos Akriviadis); ^bDepartment of Pathology (Prodromos Hytiroglou), Aristotle University, Medical School, Thessaloniki, Greece

Conflict of Interest: None

Correspondence to: Nikolaos Papachrysos, Fourth Unit of Internal Medicine, Aristotle University, Medical School, Konstantinoupolis 49, 54642 Thessaloniki, Greece, Tel.: +4673 912 7319, Fax: +30 2310 992940, e-mail: nickpapachrisos@gmail.com

Received 05 November 2014; accepted 23 January 2015

results in elimination of activated HSCs and transformation of scar matrix into normal extracellular matrix [12,13]. Moreover, with the advent of effective therapies for various liver diseases, including chronic viral hepatitis, reports of histological improvement in cases with fibrosis, as well as cirrhosis, are continuously accumulating in the literature [14-25].

Long-term antiviral treatment with nucleos(t)ide analogs (NUCs) suppresses HBV replication, delays disease progression and contributes to resolution of fibrosis. Lamivudine was the first agent achieving reversal of clinical progression in patients with advanced fibrosis [26-27]. Subsequent studies showed improvement in histology with the use of newer NUCs, such as adefovir, entecavir, and tenofovir [28-31]. However, these studies were large randomized trials. Limited data exist on histological response to treatment in HBeAg-negative patients in everyday clinical practice. The aim of our study was to determine if long-term treatment with NUCs in clinical practice is associated with histological improvement in HBeAg-negative CHB patients and to analyze factors contributing to such an improvement.

Patients and methods

Study design and population

Patients presenting at the Fourth Unit of Internal Medicine of the Aristotle University of Thessaloniki between January 1998 and December 2011 were included in this study. All patients were required to have documented HBV mono-infection, HBeAg-negative, as well as available baseline liver biopsy and HBV DNA measurements. A total of 258 eligible patients were started on antiviral treatment within this time range. We performed a second biopsy to patients who agreed to participate to our study. There was no other clinical indication for the control biopsy. A second biopsy after prolonged treatment was available in 52 of the 257 patients. From these 52 patients, one had hepatitis delta virus co-infection and one had concomitant steatohepatitis. These 2 patients were excluded from the study analysis, leaving 50 patients as our study population. Once the study population was defined, a retrospective chart review was performed in order to retrieve the demographic and laboratory data of these patients.

Drug administration

The great majority of patients originally received lamivudine (n=42, 84%), whereas six received entecavir, one telbivudine, and one tenofovir, all in the recommended dosages. Due to viral resistance to lamivudine, a NUC was added in 17 patients (adefovir n=11; tenofovir n=6). In addition, one patient was subsequently switched from adefovir to tenofovir during the study period. Currently, these 17 patients have been switched to tenofovir monotherapy. Twenty-two of the 50 patients had initially received a 12-month course of pegylated interferon (pegIFN)- α , followed by NUCs.

Follow-up patient evaluation

The patients were routinely followed-up every 6 months for evaluation of liver enzymes. HBV DNA measurements were performed every 6-12 months in patients receiving NUCs and adefovir and every 12-24 months in patients on treatment with tenofovir. Serum samples for virological and biochemical examinations were assessed in local laboratories. Serum HBV DNA levels was assayed using the Cobas Amplicor HBV test (Roche Molecular Systems, detection limit <6 IU/mL). Values were matched in time (± 12 weeks) with the corresponding long-term biopsy. In addition, ultrasound examination and α -fetoprotein measurements were performed every 6 months in patients with advanced fibrosis or cirrhosis.

Paired liver biopsy specimens were compared in all patients. All specimens were evaluated by a single histopathologist (PH). In each biopsy, necroinflammatory activity was assessed with the modified histological activity index (HAI) [32], and was classified into 4 categories: 1-minimal (HAI: 0-3); 2-mild (HAI: 4-8); 3-moderate (HAI: 9-12); and 4-severe (HAI: 13-18). Determination of stage was made on Masson trichrome-stained sections using the 5-stage METAVIR system (F0-F4) [33].

Statistical analysis

Continuous variables were presented as means \pm standard deviations or medians (range). Comparisons between the two groups were performed using independent *t*-tests if values were normally distributed, or by the Wilcoxon rank sum test if the distribution was not normal. Frequency data were presented as numbers and percentages, and were compared using the chi-square test or the Fisher's exact test, as appropriate.

Results

Study population

All the patients of the study were Caucasian and had HBeAg-negative CHB. The baseline characteristics of the study patients are shown in Table 1. The distribution of the baseline necroinflammatory activity is shown in Fig. 1A, and the distribution of the baseline METAVIR fibrosis score in Fig. 2A. Twenty patients (40%) had a METAVIR score \geq F3, indicating

Table 1 Demographic and baseline characteristics of the patients

Number of patients	50
Age, mean (years), range	46.9 \pm 10.7, 17-66
Male, n (%)	27 (54%)
HBV-DNA, mean (IU/ml), range	7.8 \times 10 ⁷ , 0-2 \times 10 ⁹
AST, mean (U/ml), range	77 \pm 66, 18-246
ALT, mean (U/ml), range	115 \pm 124, 19-516

advanced fibrosis or cirrhosis. All liver samples had length of at least 15 mm. Baseline biopsy specimens had a mean length of 21.4 mm, and follow-up biopsy specimens had a mean length of 29.0mm. The mean time on antiviral treatment at the time of the follow-up biopsy was 72.6±27.8 months.

Histological response

Thirty-six patients (72%) had improved histological activity in the follow-up compared to baseline biopsy. The mean reduction in the modified HAI score was 1.1±1.06 point. The change in the distribution of the histological activity between baseline and follow-up biopsies is shown in Fig. 1. In addition, 24 patients (48%) had improved METAVIR fibrosis score of at least 1 point when the two biopsies were compared. The mean reduction in METAVIR fibrosis score was 0.56±0.73 points. The change in the distribution of the

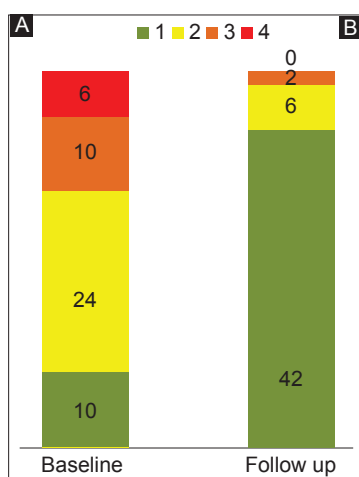


Figure 1 (A,B) Distribution of necroinflammatory activity (modified histological activity index [HAI] score) at baseline and at the time of long-term biopsy (mean time interval: 72.6 months)

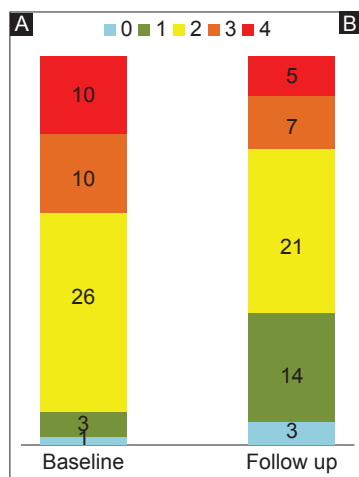

Figure 2 (A,B) Distribution of METAVIR fibrosis score at baseline and at the time of long-term biopsy (mean time interval: 72.6 months)

METAVIR fibrosis scores between baseline and follow-up biopsies is shown in Fig. 2.

One of the 50 patients (2%) had an increase in METAVIR fibrosis score, rising from F2 at baseline to F3 at the follow-up biopsy. The first biopsy length in this patient was 27 mm and the second one 29 mm. This patient had undetectable HBV DNA and normal transaminase levels at the time of follow-up biopsy. Of note, the HAI was minimal (HAI=1) in the second biopsy specimen. The patient two years before the follow-up biopsy, had developed viral resistance to lamivudine and received rescue treatment with adefovir.

Assessment of factors predicting improvement in staging

No significant difference in the time intervals between the two biopsies was found when patients with improvement in staging were compared with patients with no improvement or worsening in staging (79 vs. 67 months, P=0.13). Patients with improvement in staging tended to have lower aspartate aminotransferase and ALT levels, but this did not reach statistical significance (22 vs. 33, P=0.25 and 25 vs. 49, P=0.29, respectively).

Patients with CHB of advanced stages

Twelve of the 20 patients (60%) with advanced fibrosis or cirrhosis (METAVIR score ≥F3) at baseline had at least a 1-point reduction in METAVIR score at follow-up biopsy, with a mean score drop of 0.80 points. Ten of the 20 patients had cirrhosis (METAVIR score: F4) at baseline; five of them had improvement in their stage (3 patients to F3, 1 to F2 and 1 to F1). Fig. 3 shows a case of cirrhosis with regression of fibrosis and architectural improvement after long-term antiviral therapy.

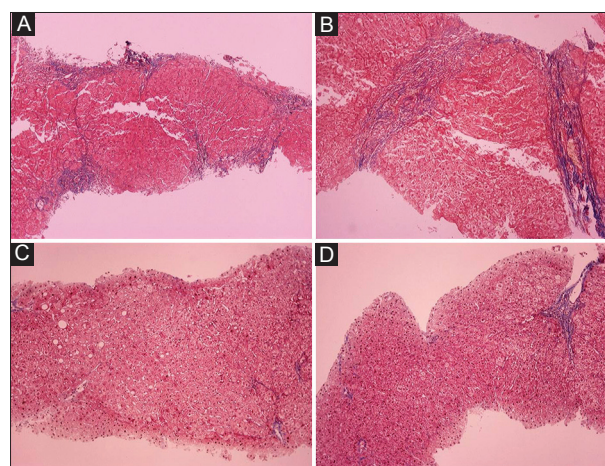


Figure 3 Representative areas of liver biopsy specimens, obtained from a 51-year-old chronic hepatitis B patient before initiation of treatment (A,B) and after 8 years with lamivudine treatment (C, D). Improvement in staging from F4 to F1 is evident. (Masson trichrome stain, X100)

Patients who developed virological breakthrough

Seven of the 17 patients (41%) who developed virological breakthrough to lamivudine had at least a 1-point reduction in METAVIR score at follow-up biopsy. The time interval between the virological breakthrough and the follow-up biopsy was 4.2 ± 2.6 years. All patients were rescued with addition of a NUC. Mean score drop was 0.47 points. No significant difference in the mean score drop was observed when patients who developed virological breakthrough were compared with those who did not (0.47 vs. 0.61, $P=0.54$). Only one of the patients (6%) had a worsening of METAVIR fibrosis score rising from F2 to F3 at the follow-up biopsy.

Patients who received IFN treatment

Twenty-two of the 50 patients (44%) had initially received a 12-month course of pegIFN- α , followed by NUCs. IFN group had improved the fibrosis stage by 0.43 points in comparison to the patients who had not received IFN which improved the stage by 0.63 points. We observed no statistical difference in the fibrosis regression between the two groups ($P=0.33$).

Discussion

The effect of long-term treatment with NUCs on the histological changes is evaluated in this cohort of HBeAg-negative Caucasian CHB patients treated in everyday clinical practice. After a mean treatment period of approximately 6 years, improvement in necroinflammatory activity was achieved in 72% and improvement in METAVIR staging in 48% of the patients, including 60% of those with advanced fibrosis or cirrhosis. Patients who developed transient virological breakthrough during their course of treatment also experienced improvement in staging, suggesting that regression of fibrosis is not hindered in this subpopulation, when early rescue with a second antiviral agent is provided. Our findings can be explained as follows: repression of HBV replication with antiviral drugs leads over time to reduction in inflammatory cell infiltration in the liver, Kupffer cell deactivation and stellate cell apoptosis or return to quiescence (9-11); then excess fibrous tissue can be resorbed and hepatic architecture can be restored.

Regression of cirrhosis following treatment with a NUC (lamivudine) was first reported in 2000, in a CHB patient, who underwent a series of biopsies [34]. This report was followed by a few case series of CHB patients with regression of cirrhosis after treatment [35-37]. Important data regarding histological improvement after treatment with NUCs were also derived from randomized trials. During a 3-year study of lamivudine in NUC-naïve, HBeAg-negative patients, 56% of the participants showed improvement in histological staging [27]. The histological outcome of adefovir-treated patients was evaluated in two cohorts. In the first study assessing HBeAg-negative

patients, 55% (12/22) of the patients treated for 4 years, and 71% (17/24) of the patients treated for 5 years had improvement in Ishak fibrosis score [28]. In the second study assessing HBeAg-positive patients, 60% (9/15) of the patients with paired biopsies showed improvement in fibrosis [29]. In a more recent study, including 57 NUC-naïve patients from two phase III entecavir trials, fibrosis stage was evaluated after approximately 6 years [30]. The study showed a significant improvement in Ishak fibrosis score in 88% of the patients, with a mean decline of 1.53. Recently tenofovir treatment was shown to lead to fibrosis improvement, including cirrhosis regression, in the majority of patients included in the pivotal trials of this drug [31]. Fifty-one percent of the 348 patients with paired biopsies (at baseline and at week 240) had regression of fibrosis in their follow-up biopsy. Importantly, 71 of 96 patients with Ishak stage 5 or 6 (74%) were found not to have cirrhosis at week 240.

Clinical trials offer the chance to evaluate large population samples in a predefined way. However, many patients are often excluded from these trials for various reasons, thus making their results difficult to interpret in clinical practice. It is important for clinicians to know that antiviral therapy for CHB leads also to fibrosis regression in the setting of everyday clinical practice, where all patients are included, as shown by our study. Moreover it is of interest that such improvement can be achieved despite the emergence of viral resistance, provided that antiviral therapy with a potent NUC is promptly initiated.

Forty-eight percent of the patients in our study experienced improvement in METAVIR score within a mean period of approximately 6 years of treatment. Notably, regression of cirrhosis was found in a similar percentage of our patients (5 out of 10). Currently, cirrhosis is considered as a dynamic

Summary Box

What is already known:

- Liver fibrosis is a dynamic process, potentially reversible
- Antiviral therapy in patients with chronic hepatitis B (CHB) can delay disease progression and contribute to resolution of fibrosis
- Clinical observations of long-term treatment with nucleos(t)ide analogs (NUCs) are missing, especially in Caucasian patients with HBeAg-negative CHB

What the new findings are:

- Antiviral therapy with NUCs can lead to regression of fibrosis in a heterogenic group of patients with HBeAg-negative CHB treated in clinical practice
- Development of transient virological breakthrough does not hinder the regression of fibrosis when early rescue with a second antiviral agent is provided

stage in the evolution of chronic liver diseases, with the potential to regress, particularly in cases without severe architectural distortion and where effective treatments are available [38]. Only one patient of our study showed worsening of his METAVIR score, although he had marked improvement in other histological, biochemical, and virological parameters. This patient did not have evidence of advanced fibrosis in the baseline biopsy specimen and may represent the known limitations of liver biopsy (sampling error).

In conclusion, our data show that long-term antiviral therapy in clinical practice can lead to regression of fibrosis and hepatic architectural improvement in patients with HBeAg-negative CHB. Thus, histological improvement could become a rational endpoint of treatment and an important motivation factor for such patients.

References

- McMahon BJ. Epidemiology and natural history of hepatitis B. *Semin Liv Dis* 2005;**25**(Suppl 1):3-8.
- Iloeje UH, Yang HI, Su I, et al. Predicting cirrhosis risk based on the level of circulating hepatitis B viral load. *Gastroenterology* 2006;**130**:678-686.
- Sanai FM, Helmy A, Bzeizi KI, et al. Discriminant value of serum HBV DNA levels as predictors of liver fibrosis in chronic hepatitis B. *J Viral Hepat* 2011;**18**:e217-e225.
- Alam S, Ahmad N, Mustafa G, et al. Evaluation of normal or minimally elevated alanine transaminase, age and DNA level in predicting liver histological changes in chronic hepatitis B. *Liver Int* 2011;**31**:824-830.
- Bataller R, Brenner DA. Liver fibrosis. *J Clin Invest* 2005;**115**:209-218.
- Friedman SL. Liver fibrosis - from bench to bedside. *J Hepatol* 2003;**38**:S38-S53.
- Henderson N, Iredale J. Liver fibrosis: cellular mechanisms of progression and resolution. *Clin Sci* 2007;**112**:265-280.
- Iredale JP. Models of liver fibrosis: exploring the dynamic nature of inflammation and repair in a solid organ. *J Clin Invest* 2007;**117**:539-548.
- Elsharkawy AM, Oakley F, Mann DA. The role and regulation of hepatic stellate cell apoptosis in reversal of liver fibrosis. *Apoptosis* 2005;**10**:927-939.
- Iredale JP, Benyon RC, Pickering J, et al. Mechanisms of spontaneous resolution of rat liver fibrosis. Hepatic stellate cell apoptosis and reduced hepatic expression of metalloproteinase inhibitors. *J Clin Invest* 1998;**102**:538-549.
- Issa R, Williams E, Trim N, et al. Apoptosis of hepatic stellate cells: involvement in resolution of biliary fibrosis and regulation by soluble growth factors. *Gut* 2001;**48**:548-557.
- Cameron GR, Karunaratne WAE. Carbon tetrachloride cirrhosis in relation to liver regeneration. *J Path Bact* 1936;**42**:1-21.
- Jacques WE, McAdams AI. Reversible biliary cirrhosis in rat after partial ligation of common bile duct. *AMA Arch Path* 1957;**63**:149-153.
- Dufour JF, DeLellis R, Kaplan MM. Regression of hepatic fibrosis in hepatitis C with long-term interferon treatment. *Dig Dis Sci* 1998;**43**:2573-2576.
- Hammel P, Couvelard A, O'Toole D, et al. Regression of liver fibrosis after biliary drainage in patients with chronic pancreatitis and stenosis of the common bile duct. *N Engl J Med* 2001;**344**:418-423.
- Muretto P, Angelucci E, Lucarelli G. Reversibility of cirrhosis in patients cured of thalassemia by bone marrow transplantation. *Ann Intern Med* 2002;**136**:667-672.
- Benyon RC, Iredale JP. Is liver fibrosis reversible? *Gut* 2000;**46**:443-446.
- Poynard T, McHutchison J, Manns M, et al. Impact of pegylated interferon alfa-2b and ribavirin on liver fibrosis in patients with chronic hepatitis C. *Gastroenterology* 2002;**122**:1303-1313.
- Sereje F, Costa A, Oliveira AG, et al. Alpha interferon improves liver fibrosis in chronic hepatitis C: clinical significance of the serum N-terminal propeptide of procollagen type III. *Dig Dis Sci* 2001;**46**:1684-1689.
- Shiratori Y, Imazeki F, Moriyama M, et al. Histologic improvement of fibrosis in patients with hepatitis C who have sustained response to interferon therapy. *Ann Intern Med* 2000;**132**:517-524.
- Manolakopoulos S, Triantos C, Theodoropoulos J, et al. Antiviral therapy reduces portal pressure in patients with cirrhosis due to HBeAg-negative chronic hepatitis B and significant portal hypertension. *J Hepatol* 2009;**51**:468-474.
- Pozzi M, Pizzala DP, Maldini FF, et al. Portal pressure reduction after entecavir treatment in compensated HBV cirrhosis. *Hepato gastroenterology* 2009;**56**:231-235.
- Bourlière M, Kahloun A, Gascou-Tessonier G. Analogs and fibrosis regression in hepatitis B. *Gastroenterol Clin Biol* 2009;**33**:923-929.
- Brown A, Goodman Z. Hepatitis B-associated fibrosis and fibrosis/cirrhosis regression with nucleoside and nucleotide analogs. *Expert Rev Gastroenterol Hepatol* 2012;**6**:187-198.
- Chang CY, Martin P, Fotiadu A, et al. A patient with chronic hepatitis B and regression of fibrosis during treatment. *Semin Liver Dis* 2010;**30**:296-301.
- Liaw YF, Sung JJ, Chow WC, et al. Lamivudine for patients with chronic hepatitis B and advanced liver disease. *N Engl J Med* 2004;**351**:1521-1531.
- Dienstag JL, Goldin RD, Heathcote EJ, et al. Histological outcome during long-term lamivudine therapy. *Gastroenterology* 2003;**124**:105-117.
- Hadziyannis SJ, Tassopoulos NC, Heathcote EJ, et al. Long-term therapy with adefovir dipivoxil for HBeAg-negative chronic hepatitis B for up to 5 years. *Gastroenterology* 2006;**131**:1743-1751.
- Marcellin P, Chang TT, Lim SG, et al. Long-term efficacy and safety of adefovir dipivoxil for the treatment of hepatitis B e antigen-positive chronic hepatitis B. *Hepatology* 2008;**48**:750-758.
- Chang TT, Liaw YF, Wu SS, et al. Long-term entecavir therapy results in the reversal of fibrosis/cirrhosis and continued histological improvement in patients with chronic hepatitis B. *Hepatology* 2010;**52**:886-893.
- Marcellin P, Gane E, Butti M, et al. Regression of cirrhosis during treatment with tenofovir disoproxil fumarate for chronic hepatitis B: a 5-year open-label follow-up study. *Lancet* 2013;**381**:468-475.
- Ishak K, Baptista A, Bianchi L, et al. Histological grading and staging of chronic hepatitis. *J Hepatol* 1995;**22**:696-699.
- Bedossa P, Poynard T. An algorithm for the grading of activity in chronic hepatitis C. The METAVIR Cooperative Study Group. *Hepatology* 1996;**24**:289-293.
- Wanless I, Nakashima E, Sherman M. Regression of human cirrhosis: morphologic features and the genesis of incomplete septal cirrhosis. *Arch Pathol Lab Med* 2000;**124**:1599-1607.
- Malekzadeh R, Mohamadnejad M, Rakhshani N, et al. Reversibility of cirrhosis in chronic hepatitis B. *Clin Gastroenterol Hepatol* 2004;**2**:344-347.
- Bortolotti F, Guido M, Cadrobbi P, et al. Spontaneous regression of hepatitis B virus-associated cirrhosis developed in childhood. *Dig Liver Dis* 2005;**36**:964-967.
- Serpaggi J, Carnot F, Nalpas B, et al. Direct and indirect evidence for the reversibility of cirrhosis. *Hum Pathol* 2006;**37**:1519-1526.
- Hytiroglou P, Snover DC, Alves V, et al. Beyond "cirrhosis": a proposal from the International Liver Pathology Study Group. *Am J Clin Pathol* 2012;**137**:5-9.