

Analysis of renal artery morphometry in adults: A study conducted by using Multidetector computed Tomography Angiography

Maria Mohiuddin¹, Arsalan Mansoor²,
Muhammad Ali³, Nuzhat Hassan⁴

ABSTRACT

Objective: To determine a reference range of renal artery measurements by using Multidetector Computed Tomography (MDCT) angiography and to find association of renal artery measurements with side of artery, gender and age.

Method: Two hundred and fifty study participants without renal artery disease who were presented to Radiology Department, Ziauddin Hospital, Karachi, from November, 2016 to April, 2017 were included in this study. Main renal artery measurements were taken on Multidetector computed angiography and variation with side, gender and age were analyzed. Statistical analysis was done on Statistical Package for Social Sciences (SPSS) version 20. Independent sample T test, one way ANOVA and Pearson's correlation analysis were applied. P-value of ≤ 0.05 was considered significant.

Results: A significance difference ($p=0.001$) was seen between mean right renal artery (diameter 6.66 ± 0.39 mm; length 44.69 ± 2.48 mm) and left renal artery (diameter 6.79 ± 0.36 ; length 35.10 ± 2.86 mm). Females found to have smaller mean diameter and length of renal arteries than males. However, a weak negative correlation was seen between mean renal artery diameter and age (right $r= -0.158$, $p=0.0121$; left $r= -0.017$, $p= 0.708$).

Conclusion: The mean diameter and mean length were found to be significantly different between right and left main renal artery and between males and females. A significant weak negative correlation was observed between renal artery diameter and age.

KEYWORDS: Age, Computerized Tomography, Gender, Renal artery.

doi: <https://doi.org/10.12669/pjms.334.13063>

How to cite this:

Mohiuddin M, Mansoor A, Ali M, Hassan N. Analysis of renal artery morphometry in adults: A study conducted by using Multidetector computed Tomography Angiography. *Pak J Med Sci.* 2017;33(4):943-947. doi: <https://doi.org/10.12669/pjms.334.13063>

This is an Open Access article distributed under the terms of the Creative Commons Attribution License (<http://creativecommons.org/licenses/by/3.0>), which permits unrestricted use, distribution, and reproduction in any medium, provided the original work is properly cited.

INTRODUCTION

In South Asian country like Pakistan, incidence of end stage renal disease (ESRD) is gradually increasing and has produced a large economic burden.¹ For end stage renal disease, renal transplant is considered as the best choice of treatment modality. It is essential, that each potential living donor should have a complete renal vasculature evaluation to avoid complications.² It is important for the surgeon to know the precise range of diameter, length and exact site of origin of renal arteries for accurate renal assessment.³

Correspondence:

Dr. Maria Mohiuddin,
Senior Lecturer,
Department of Anatomy,
Ziauddin University,
Shahrah-e-Ghalib,
Clifton Campus,
Karachi, Pakistan.
E-mail: mohiuddinmaria22@gmail.com

- * Received for Publication: May 3, 2017
- * Revision Received: June 14, 2017
- * Revision Accepted: * June 14, 2017

Due to increase in radiological imaging techniques, normal range of renal artery diameter is very important for guiding interventional radiologist during procedures like arterial catheterization and angioplasty.⁴ Decrease in luminal diameter of renal artery leads to renal artery stenosis that will cause renovascular hypertension and ischemic nephropathy.⁵ Percutaneous arterial stenting is the choice of treatment for renal artery stenosis, but this requires definite measurement of renal artery diameter and length.⁶⁻⁸

Renal arteries arises normally from lateral aspects of abdominal aorta at level of intervertebral disc between 1st and 2nd lumbar vertebrae's below the origin of superior mesenteric artery.⁹ Arteries run laterally and enter the renal hilum and divides into segmental branches.¹⁰ Variation in renal artery dimensions was frequently seen in routine clinical and surgical practice. As renal artery measurements varies with factors like age, gender and geographical location. Studies reported variation in renal artery dimensions gender, age and side of artery.^{11,12}

Conventional catheter angiography is regarded as a gold standard technique to visualize arteries but its invasive nature limits its use. In contrast, Multidetector computed tomography (MDCT) angiography is considered to be a major advancement in computerized tomography (CT) imaging.^{13,14} It has many advantages as high speed acquisition, accurate, less invasive, low cost as compared to magnetic resonance angiography (MRA) and provides multiple three dimensional reconstructed images that will help to see accurate renal vascular anatomy in detail and also visualization of surrounding renal parenchyma.¹⁵

Studies have been performed in different parts of world to establish normal reference range of renal artery dimensions.^{3,16,17} Review of literature showed that studies performed in our population were mainly in context with renal vascular pathologies as renal artery stenosis and renovascular hypertension.¹⁸⁻²⁰ Thus, this study was conducted to determine a reference range of normal renal artery measurements and to find its variation with side of artery, gender and age in our population by using MDCT angiography in our population.

METHODS

Study subjects were recruited for those individuals who were presented to Radiology Department of Ziauddin University Hospital, Clifton campus, Karachi, from November 2016 to April 2017 for abdominal contrast CT examination without renal

diseases. Study was conducted after approval from Ethical review committee of Ziauddin University. A total of 250 individuals aged 21 years to 60 years were recruited through consecutive sampling. Informed consent and clinical history was obtained from all participants. Those with serum creatinine ≤ 1.3 mg /dl (as per Hospital Lab value) and adults with no known renal artery and vein diseases were included. Participants with a history of renal transplant, renal surgery, vasculitis, congenital vascular anomalies, allergic reaction to contrast agent, pregnancy, hypertension and diabetes mellitus were excluded.

CT scan was performed using standard protocol,^{14,16} on a 16-slice MDCT scanner (Toshiba 16 slicer Alexion, Japan). Prior to scan emptiness of stomach and bowels were ensured.²¹ Contrast material was given through a wide bore intravenous line placed in the antecubital fossa at the rate of 4 ml/sec and amount of 2 ml/kg contrast was injected. The patient was instructed to hold his/her breath for 10 seconds and scan was initiated. The scanned area was extended from diaphragm to iliac crest. Acquisition of image data was initiated after a preset delay of 10 to 15 seconds after the start of the contrast agent injection. Image data was transferred to an imaging workstation (Toshiba Medical Systems), which was used to post-process volumetric MDCT data. Special computer software was used for 3-dimensional reconstruction of images in different planes and projections in arterial phase of scan. Multiplanar reconstructed (MPR) and Maximum intensity projection (MIP) images with thin (0.5 mm) and thick (3 mm) slice thicknesses were used to evaluate the renal arteries. Oblique coronal and axial MIP images with curved planar reconstruction were generated to visualize renal artery along its route. Renal artery diameter and length were measured. Diameter was measured in the proximal segment (1.5 cm from origin) of the renal artery.²²

Data was analyzed on SPSS version 20. Quantitative variables were presented as mean \pm standard deviation. Quantitative variables were compared by using one sample t-test, independent t-test and one way ANOVA. Correlation analysis by using Pearson's correlation was applied to test the relationship between variables. P-value < 0.05 was considered significant.

RESULTS

Out of 250 individuals 129 (51.6%) were males and 121(48.4%) were females. Study participants

Table-I: Comparison of right and left renal artery.

Parameter	No. of Participant (n)	Right Renal Artery Mean \pm SD	Left Renal Artery Mean \pm SD	p-value
Diameter (mm)	250	6.66 \pm 0.39	6.79 \pm 0.36	0.001*
Length (mm)	250	44.69 \pm 2.48	35.10 \pm 2.86	0.001*

Confidence interval 95%, p-value \leq 0.05 is significant*

were 21 to 60 years of age. Mean age of males were 43.5 \pm 11.0 years and females were 44.3 \pm 12.69 years. Mean values of right and left renal arteries are shown in Table-I. A significant difference (p=0.001) of mean diameter and length was observed between right and left main renal arteries (Table-I).

In males mean diameter of right renal artery was 6.90 \pm 0.24mm and left renal artery was 7.03 \pm 0.22mm. In females mean diameter of right renal artery was 6.40 \pm 0.35mm and of left renal artery was 6.54 \pm 0.31mm. A significant difference (p = 0.001) of mean diameter of right and left renal arteries was observed between males and females (Fig.1). Moreover in males mean right renal artery length was 46.45 \pm 1.93mm and left renal artery

length 36.54 \pm 1.83mm were significantly different (p=0.001) from mean right renal artery length 42.81 \pm 1.39mm and left renal artery length 33.56 \pm 2.96 mm in females.

All participants were stratified accordingly into four age groups i.e. Group-1 (21 to 30 years), Group-2 (31 to 40 years), Group-3 (41 to 50 years) and Group-4 (51 to 60 years). Mean diameter of right renal and left renal arteries were found significantly different (p=0.001) among age groups. By using Pearson's correlation analysis a significant weak negative correlation (r= -0.158, p= 0.012) was found between mean right renal artery diameter and age. A weak negative correlation (r= -0.017, p=0.708) was found between mean left renal diameter and age. Moreover no significant difference of mean length of right and left renal arteries was observed between age groups (Table-II).

DISCUSSION

It is essential for the radiologists and surgeons to have background knowledge of normal range of renal artery measurements and variation in measurements in a specific population as this can affect complex and expertise required procedure.^{23,24} In our study a significant difference was observed between mean diameter of right and left main renal arteries. Mean diameter of right renal artery was found to be smaller than mean diameter of left renal artery. Our results are in agreement with the results reported in a study conducted in Columbia, which reported right renal artery diameter to be significantly less than left renal artery diameter.²⁵ A study conducted in Iran by using Multi-slice CT scan reported right renal artery diameter to be smaller than left renal artery diameter (p=0.35).²⁶ Mean length of right renal artery in present study

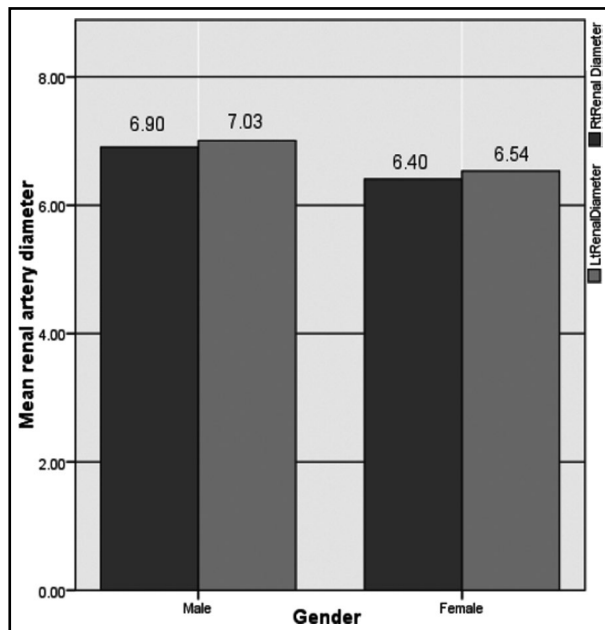


Fig.1: Comparison of mean diameter of right renal artery and left renal artery in males and females.

Table-II: Comparison of mean renal artery diameter and length in different age groups.

Age groups (years)	1 (21-30)	2 (31-40)	3 (41-50)	4 (51-60)	P-value
Total (n)	n=45	n=46	n=78	n=81	
Rt Renal Dia (mm)	6.63 \pm 0.18	6.94 \pm 0.19	6.95 \pm 0.21	6.26 \pm 0.30	0.001*
Lt Renal Dia (mm)	6.75 \pm 0.16	7.05 \pm 0.17	7.07 \pm 0.22	6.43 \pm 0.27	0.001*
Rt Renal L (mm)	44.68 \pm 2.29	44.87 \pm 2.92	45.26 \pm 2.11	44.07 \pm 2.59	0.08
Lt Renal L (mm)	35.24 \pm 2.45	34.85 \pm 4.88	35.49 \pm 2.24	34.78 \pm 2.25	0.58

Rt: right, Lt: left, Dia: diameter, L: length, Confidence interval 95%, p-value \leq 0.05 is significant*

was found to be significantly ($p=0.001$) longer than mean length of left renal artery (Table-I). A study conducted on 200 renal pedicles in Brazil reported mean right renal artery length longer than left renal artery length ($p=0.002$).¹⁶ This is probably due to the location of abdominal aorta to the left of median plane in abdomen and the longer path of the renal artery on the right side, as suggested by different authors.^{3,16,25}

In this study, females were found to have significantly ($p= 0.001$) smaller mean diameter and mean length of right and left renal arteries as compared to males (Table-I). A novel study conducted in university of Virginia reported bilateral renal arteries more in diameter and length in males as compared to females ($p<0.001$) and concluded, these variation in measurements are because of relatively large body size of males as compared to females.¹²

Aging is associated with decreased vascular compliance and increased vascular rigidity.²⁷ In this study, a 0.3 mm increase in mean diameter of both renal arteries was seen after 20 years of age and an approximately constant diameter during fourth and fifth decades of life. However, a decrease of 0.64 mm was seen after 50 years of age. A weak negative correlation was seen between mean right renal artery diameter ($r = - 0.158$, $p= 0.012$) and left renal artery diameter ($r = - 0.017$, $p = 0.708$) with age. Moreover, no significant difference was observed between length of renal arteries and age. Our findings are in accordance with results reported in a study conducted in South Africa, in which a 0.4mm increase in luminal diameter was observed after second decade that remain almost constant till fifth decade and a subsequent decrease of 0.4 mm after 60 years of age.¹¹ Another study also reported a strong influence of increasing age on narrowing of renal artery diameter.²⁸ Increase in diameter during adulthood is probably due to increased physical activity and associated increased cardiac output.²⁹ While, a decrease in luminal diameter of artery with advancing age is possibly due to progressive thickening of the tunica intima layer, separation of individual elastin lamellae and increase in collagen matrix in arterial wall.²⁷

In this study we have established a normal reference range regarding renal artery dimensions in adults in our local population. Morphometric data regarding renal arteries and variation in measurements is imperative for selecting donors for renal transplant, to diagnose renal artery

stenosis, guiding the radiologist during arterial catheterizations, laparoscopic nephrectomies, to design and place arterial stent grafts.^{3,28,30,31}

CONCLUSION

Our study concluded that significant difference of diameter and length exists between right and left renal arteries. Renal artery diameter and length are significantly different between males and females. A significant weak negative correlation was observed between renal artery diameter and age. However, large scale multicentre nationwide studies should be done in future to further strengthen our result.

Grant Support & Financial Disclosures: None.

Declaration of interest: None.

REFERENCES

1. Saeed Z, Mirza W, Sayani R, Sheikh A, Yazdani I, Hussain SA. Sonographic measurement of renal dimensions in adults and its correlates. *Int J Collab Res Intern Med Public Health*. 2012;4:1626-1641.
2. Farouk K, Majeed NU, Qureshi IA. Results of Separate Anastomoses of Multiple Renal Arteries with Recipient External Iliac Artery in Renal Transplant Surgery. *Pak J Med Res*. 2011;50(2):55-59.
3. Ahmed MAAS, Gobran HA. Morphometric Study Of The Renal Arteries In Saudi Population From Aseer Region Using 3-D MDCT Angiography. *Sci Nat*. 2013;2(2):41-45.
4. Saldarriaga B, Pérez A, Ballesteros L. A direct anatomical study of additional renal arteries in a Colombian mestizo population. *Folia Morphol*. 2008;67(2):129-134.
5. Krumme B, Hollenbeck M. Doppler sonography in renal artery stenosis – does the Resistive Index predict the success of intervention? *Nephrol Dial Transplant*. 2007;22(3):692-696. doi: 10.1093/ndt/gfl686.
6. Gümüş H, Bükte Y, Özdemir E, Çetinçakmak MG, Tekbaş G, Ekici F, et al. Variations of renal artery in 820 patients using 64-detector CT-angiography. *Renal Failure*. 2012;34(3):286-290. doi:10.3109/0886022X2011.647295.
7. Türkvatan A, Özdemir M, Cumhuri T, Ölçer T. Multidetector CT angiography of renal vasculature: normal anatomy and variants. *Euro Radiol*. 2009;19(1):236-244. doi:10.1007/s00330-008-1126-3.
8. Weber BR, Dieter RS. Renal artery stenosis: epidemiology and treatment. *Int J Nephrol Renovasc Dis*. 2014;7:169-181. doi:10.2147/IJNRD.S4015.
9. Moore KL. Clinically Oriented Anatomy. In: Moore KL, editor. *Clinically Oriented Anatomy*. Seventh Edition ed 2014. p. 292-297.
10. Healy JC. Abdomen and Pelvis. In: Standring S, editor. *Gray's Anatomy, The Anatomical Basis of Clinical Practice*. Fortieth Edition 2008. p. 1225-1233.
11. Chiaganam NO, Ekpo EU, Egbe NO, Nzotta CC, Okwara KK. Aging and the average diameter of the renal artery using computed tomography angiography (CTA). *The South African Radiographer*. 2013;51(1):23-25.
12. Turba UC, Uflacker R, Bozlar U, Hagspiel KD. Normal renal arterial anatomy assessed by multidetector CT angiography: are there differences between men and women? *Clin Anat*. 2009;22(2):236-242. doi:10.1002/ca.20748.

13. Burrill J, Dabbagh Z, Gollub F, Hamady M. Multidetector computed tomographic angiography of the cardiovascular system. *Postgraduate Med J*. 2007;83(985):698-704. doi: 10.1136/pqmj.2007.061804.
14. Urban BA, Ratner LE, Fishman EK. Three-dimensional Volume-rendered CT Angiography of the Renal Arteries and Veins: Normal Anatomy, Variants, and Clinical Applications 1. *Radiographics*. 2001;21(2):373-386. doi: 10.1148/radiographics.21.2.q01mr19373.
15. Vijayakumar M, Ganpule S, Ganpule AP, Murali V, Mishra S, Sabnis R, et al. Diagnostic accuracy of CT angiography in evaluation of vascular anatomy in comparison with intraoperative findings an assessment of 392 patients. *F1000 Research*. 2015;4:998.
16. Palmieri BJ, Petroianu A, Silva LC, Andrade LM, Alberti LR. Study of arterial pattern of 200 renal pedicle through angiotomography. *Revista do Colégio Brasileiro de Cirurgiões*. 2011;38(2):116-121.
17. Ramulu MV, Prasanna LC. Morphometric evaluation of the kidney and its main renal artery. *Int J Res Med Sci*. 2015;3(2):429-432.
18. Khan S, Nayyar B, Baloch S. Resistive index on doppler ultrasound after renal transplantation as renal function predictor. *Pak Armed Forces Med J*. 2015;65(5):635-639.
19. Lashari MN, Khan MS. Endovascular Treatment of Renal Artery Stenoses. *J Coll Physicians Surg Pak*. 2015;25(1):8-11.
20. Ashraf HS, Hussain I, Siddiqui AA, Ibrahim MN, Khan MU. The outcome of living related kidney transplantation with multiple renal arteries. *Saudi J Kidney Dis Transplant*. 2013;24(3):615-619.
21. Lee B-Y, Ok J-J, Abdelaziz Elsayed AA, Kim Y, Han DH. Preparative fasting for contrast-enhanced CT: reconsideration. *Radiology*. 2012;263(2):444-450. doi: 10.1148/radiol.12111605.
22. Ramadan SU, Yigit H, Gökharman D, Tuñçbilek I, Dolgun NA, Kosar P, et al. Can renal dimensions and the main renal artery diameter indicate the presence of an accessory renal artery? A 64-slice CT study. *Diagn Interv Radiol*. 2011;17(3):266-271. doi:10.4261/1305-3825.DIR.3507-10.0.
23. Mello Júnior CFd, Araujo Neto SA, Carvalho Junior AMD, Rebouças RB, Negromonte GRP, Oliveira CDd. Multidetector computed tomography angiography of the renal arteries: normal anatomy and its variations. *Radiologia Brasileira*. 2016;49(3):190-195. doi:10.1590/0100-3984.2014.0048.
24. Schönherr E, Rehwald R, Nasseri P, Luger AK, Grams AE, Kerschbaum J, et al. Retrospective morphometric study of the suitability of renal arteries for renal denervation according to the Symplicity HTN2 trial criteria. *BMJ Open*. 2016;6(1):e009351. doi:10.1136/bmjopen-2015-009351.
25. Saldarriaga B, Pinto SA, Ballesteros LE. Morphological expression of the renal artery: a direct anatomical study in a Colombian half-caste population. *Int J Morphol*. 2008;26(1):31-38.
26. Tarzamni M, Nezami N, Rashid R, Argani H, Hajealioghli P, Ghorashi S. Anatomical differences in the right and left renal arterial patterns. *Folia Morphol (Warsz)*. 2008;67(2):104-110.
27. Miyawaki NB, Lester PE. *Vascular Disease in the Elderly*. 2009:1-4.
28. Lorenz EC, Vrtiska TJ, Lieske JC, Dillon JJ, Stegall MD, Li X, et al. Prevalence of renal artery and kidney abnormalities by computed tomography among healthy adults. *Clin J Am Soc Nephrol*. 2010;5(3):431-438.
29. Weinstein JR, Anderson S. The aging kidney: physiological changes. *Adv Chronic Kidney Dis*. 2010;17(4):302-307. doi:10.1053/j.ackd.2010.05.002.
30. Khan A, Sohaib M, Saeed S. Imaging in renal artery stenosis/renovascular hypertension. Retrieved June. 2008;25:2012.
31. Shammam NW, Kapalis MJ, Dippel EJ, Jerin MJ, Lemke JH, Patel P, et al. Clinical and angiographic predictors of restenosis following renal artery stenting. *J Invasive Cardiol*. 2004;16(1):10-13.

Author`s Contribution:

MM designed, did data collection and writes the manuscript.

AM did critical analysis and editing of manuscript.

MA provided intellectual and clinical approval.

NH did critical analysis and provides intellectual support.

Authors:

1. Dr. Maria Mohiuddin,
Senior Lecturer,
Department of Anatomy,
2. Dr. Arsalan Mansoor,
Assistant Professor,
Department of Anatomy,
3. Dr. Muhammad Ali,
Assistant Professor,
Head of Department of Radiology,
4. Prof. Dr. Nuzhat Hassan,
Chairperson,
Department Of Anatomy,
- 1-4: Ziauddin University, Hospital,
Karachi, Pakistan.