

## Bilateral spontaneous anterior dislocation of intraocular lens with the capsular bag in a patient with pseudoexfoliation

Harsha Bhattacharjee, Rushil Kumar Saxena,  
Jnanankar Medhi

We report a rare case of bilateral spontaneous anterior partial in-the-bag intraocular lens (IOL) dislocation in a 75-year-old man with pseudoexfoliation (PXF). He underwent uneventful phacoemulsification in both eyes with in-the-bag IOL implantation 9 years back. In the right eye, single piece poly (methyl methacrylate) (PMMA) IOL (+19 D) and in the left eye, single piece acrylic foldable IOL (+19 D) were implanted. An attempt at pharmacological IOL repositioning was unsuccessful. The dislocated IOLs were explanted and exchanged with scleral suture fixated PMMA IOLs. Vision improved to 20/30 in both eyes following surgery, without any associated ocular morbidity. We believe that zonular weakness secondary to PXF, capsular contraction, and myopia together were the predisposing factors for partial anterior dislocation of IOLs and IOL exchange with scleral suture fixation of IOL is a safe and effective treatment option.

**Key words:** Spontaneous bilateral anterior dislocation of intraocular lens, pseudoexfoliation, pseudophakia

Bilateral spontaneous anterior partial in-the-bag intraocular lens (IOL) dislocation is extremely rare.<sup>[1]</sup> Overall anterior and posterior dislocation of IOL occurs in 0.2–3% pseudophakic cases as postoperative complications.<sup>[2–4]</sup> We report a case of bilateral spontaneous anterior partial in-the-bag IOL dislocation in a case of pseudoexfoliation (PXF) which occurred 9 years following surgery along with its management.

### Case Report

A 75-year-old man reported with the blurring of vision in both eyes. He was known to suffer from PXF and had undergone standard uneventful phacoemulsification with in-the-bag implantation of monofocal IOL in both eyes. In the right eye, a single piece poly (methyl methacrylate) (PMMA) IOL (+19 D) and in the left eye, a single piece acrylic foldable IOL (+19 D)

were implanted. The surgeries were performed in the right and left eye at 9 and 8½ years, respectively, before to this examination. All the previous dilated annual eye examinations had been normal, with no clinical evidence of IOL subluxation.

On clinical examination, his visual acuity was 20/60 in both the eyes. Slit lamp examination revealed anterior partial in-the-bag IOL dislocation [Figs. 1 and 2], capsular contraction and deformation of IOL haptics. Intraocular pressure by Goldmann applanation tonometer (GAT) was 19 mmHg in both eyes. Pupils were dilated with 2.5% phenylephrine eye drops. Indirect ophthalmoscopy revealed normal ocular fundi. Constriction of pupils and IOL repositioning was tried by instillation of 2.0% pilocarpine eye drops in the supine position, but the procedure was unsuccessful. The next day, IOL along with the capsular bag were explanted surgically, [Fig. 3] and secondary scleral suture fixation of single piece PMMA IOL (Auro India) was done in the same sitting for the right eye. The procedure was repeated for the left eye 7 days later. The IOLs were held with micro forceps and explanted through the limbal route. Limited anterior vitrectomy through pars plana route was also performed. The secondary IOL implantation procedures and postoperative period were uneventful. After 12 months of surgery, best corrected visual acuity was 20/30 in both eyes. The manifest refraction was  $\pm 1.00$  DC  $\times 180^\circ$  and  $+1.00$  DS/ $-1.50$  DC  $-180^\circ$  in the right and left eye, respectively. The eyes were quiet and IOP was 19 mmHg (GAT) in both eyes.

### Discussion

IOL dislocation may occur in the immediate postoperative period and is mainly due to poor IOL fixation. This complication may also occur months to years after surgery secondary to zonular weakness. 50% cases of IOL dislocation are associated with PXF.<sup>[1]</sup> Other predisposing factors are prior vitrectomy surgery,<sup>[1]</sup> trauma,<sup>[1]</sup> high myopia,<sup>[2]</sup> retinitis pigmentosa<sup>[5]</sup> and connective tissue disorders such as Marfan syndrome, homocystinuria, hyperlysinemia, scleroderma, Weill–Marchesani, and Ehler–Danlos syndrome.<sup>[3]</sup> A cause-effect relationship between IOL dislocation and severity of glaucoma is suspected.<sup>[4]</sup> The late dislocation of IOL may occur anytime from 1 month to 8½ years following surgery.<sup>[1–4,6,7]</sup>

Bilateral spontaneous in-the-bag IOL dislocations were reported in the anterior or posterior chamber in two cases of gyrate atrophy,<sup>[7–9]</sup> one case of retinitis pigmentosa,<sup>[5]</sup> and in one patient with intermediate uveitis.<sup>[10]</sup> A literature search revealed only one case report of bilateral spontaneous anterior partial in-the-bag IOL dislocation in a patient with PXF. It occurred following mydriasis during a routine annual eye examination.<sup>[3]</sup> The case was managed by IOL repositioning and scleral suture fixation of same IOL.<sup>[3]</sup> Various corrective surgical management approaches to

This is an open access article distributed under the terms of the Creative Commons Attribution-NonCommercial-ShareAlike 3.0 License, which allows others to remix, tweak, and build upon the work non-commercially, as long as the author is credited and the new creations are licensed under the identical terms.

**For reprints contact:** reprints@medknow.com

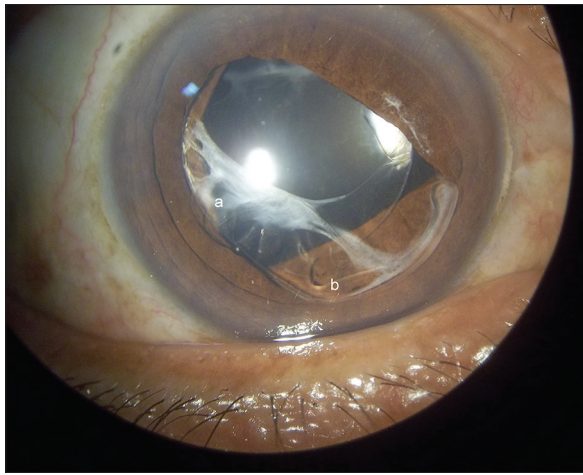
**Cite this article as:** Bhattacharjee H, Saxena RK, Medhi J. Bilateral spontaneous anterior dislocation of intraocular lens with the capsular bag in a patient with pseudoexfoliation. Indian J Ophthalmol 2015;63:796-8.

Access this article online	
Quick Response Code:	Website: www.ijo.in
	DOI: 10.4103/0301-4738.171520

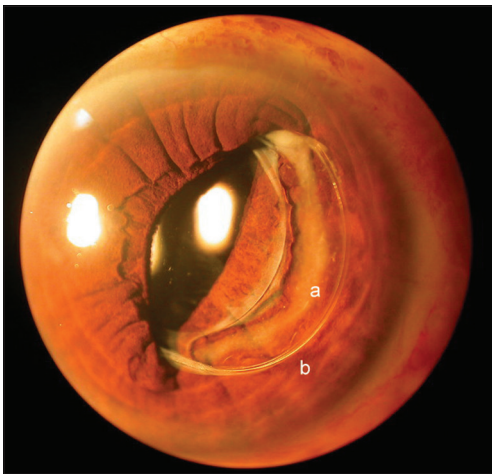
Department of Vitreoretina Services, Sri Sankardeva Nethralaya, Guwahati, Assam, India

**Correspondence to:** Dr. Rushil Kumar Saxena, Sri Sankardeva Nethralaya, 96, Basistha Road, Beltola, Guwahati - 781 028, Assam, India. E-mail: rushilkr@gmail.com

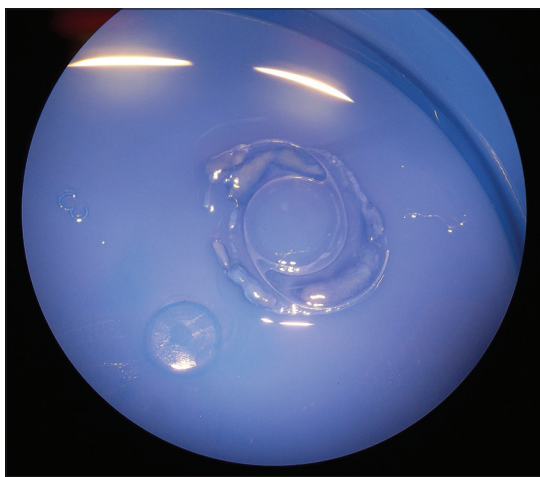
**Manuscript received:** 01.05.15; **Revision accepted:** 15.09.15



**Figure 1:** Anteriorly dislocated in-the-bag acrylic foldable intraocular lens with (a) capsular contraction and (b) compressed haptic



**Figure 2:** In-the-bag modified C loop poly (methyl methacrylate) intraocular lens with (a) ring of soemmering and (b) compressed haptic



**Figure 3:** Explanted intraocular lens with the capsular bag

dislocated IOL including IOL exchange or IOL repositioning with scleral or iris fixation have been described.<sup>[3,11,12]</sup> Apart from the more commonly used suture fixation, a sutureless,

glued IOL technique has also been described in a case of bilateral, anterior, in-the-bag subluxation of IOL in a patient with retinitis pigmentosa.<sup>[13]</sup> As all the mentioned surgical procedures are reported to be equally efficacious, the ultimate choice of surgery depends on the surgeons' preference and experience. Our case is of a healthy man with myopia and PXF both eyes. He denied any history of trauma. Bilateral anterior partial in-the-bag IOL dislocation occurred spontaneously 9 years after cataract surgery. Capsular bag revealed fibrotic activity and ring of soemmering. Both the IOLs were of different design and biomaterial. IOL haptics were found to be compressed either due to loss of biomechanical memory or due to contraction of the capsule. Except pseudophakia, during all previous eye examinations, no other signs indicative of future risk of IOL dislocation were observed. The present method of management of IOL exchange, limited anterior vitrectomy, and scleral suture fixation of IOL was found to be a safe and effective surgical option in such a case. It is also observed that IOL design and biomaterial had no role in the prevention of spontaneous dislocation of IOL. We believe PXF, myopia, and capsular contraction together were responsible for spontaneous dislocation of the IOLs, and it is only the second such case report in literature.

## Conclusion

Pseudophakia in PXF has potential for spontaneous anterior dislocation with the capsular bag. Annual detailed eye examination has no preventive role in such complications. IOL design and biomaterial are independent of such complications. Such dislocations can be managed definitively by IOL exchange and scleral suture fixation and limited anterior vitrectomy.

## Acknowledgment

Sri Kanchi Sankara Health and Educational Foundation.

## Financial support and sponsorship

Nil.

## Conflicts of interest

There are no conflicts of interest.

## References

1. Davis D, Brubaker J, Espandar L, Stringham J, Crandall A, Werner L, *et al.* Late in-the-bag spontaneous intraocular lens dislocation: Evaluation of 86 consecutive cases. *Ophthalmology* 2009;116:664-70.
2. Fernández-Buenaga R, Alio JL, Pérez-Ardoy AL, Larrosa-Quesada A, Pinilla-Cortés L, Barraquer R, *et al.* Late in-the-bag intraocular lens dislocation requiring explantation: Risk factors and outcomes. *Eye (Lond)* 2013;27:795-801.
3. Ford JR, Werner L, Owen L, Vasavada SA, Crandall A. Spontaneous bilateral anterior partial in-the-bag intraocular lens dislocation following routine annual eye examination. *J Cataract Refract Surg* 2014;40:1561-4.
4. Leung VC, Singh H, Ahmed II. Inter-eye differences in patients with pseudoexfoliation syndrome presenting with intraocular lens dislocation. *Ophthalmology* 2015;122:480-5.
5. Kwon YA, Bae SH, Sohn YH. Bilateral spontaneous anterior lens dislocation in a retinitis pigmentosa patient. *Korean J Ophthalmol* 2007;21:124-6.

6. Jehan FS, Mamalis N, Crandall AS. Spontaneous late dislocation of intraocular lens within the capsular bag in pseudoexfoliation patients. *Ophthalmology* 2001;108:1727-31.
7. Østern AE, Sandvik GF, Drolsum L. Late in-the-bag intraocular lens dislocation in eyes with pseudoexfoliation syndrome. *Acta Ophthalmol* 2014;92:184-91.
8. Kinori M, Desatnik H, Moisseiev J. Bilateral spontaneous dislocation of posterior chamber intraocular lens in a patient with gyrate atrophy. *Indian J Ophthalmol* 2012;60:133-4.
9. Tsilou E, Rubin BI, Abraham FA, Kaiser-Kupfer M. Bilateral late posterior chamber intraocular lens dislocation with the capsular bag in a patient with gyrate atrophy. *J Cataract Refract Surg* 2004;30:1593-4.
10. Brilakis HS, Lustbader JM. Bilateral dislocation of in-the-bag posterior chamber intraocular lenses in a patient with intermediate uveitis. *J Cataract Refract Surg* 2003;29:2013-4.
11. Slade DS, Hater MA, Cionni RJ, Crandall AS. Ab externo scleral fixation of intraocular lens. *J Cataract Refract Surg* 2012;38:1316-21.
12. Shingleton BJ, Yang Y, O'Donoghue MW. Management and outcomes of intraocular lens dislocation in patients with pseudoexfoliation. *J Cataract Refract Surg* 2013;39:984-93.
13. Nair V, Kumar DA, Prakash G, Jacob S, Agarwal A, Agarwal A. Bilateral spontaneous in-the-bag anterior subluxation of PCIOL managed with glued IOL technique: A case report. *Eye Contact Lens* 2009;35:215-7.