



ORIGINAL ARTICLE

# Bifid mandibular canals and their cortex thicknesses: A comparison study on images obtained from cone-beam and multislice computed tomography



E-Chin Shen <sup>a,b\*</sup>, Earl Fu <sup>a</sup>, Michelle Peng <sup>a</sup>, Yao-Dung Hsieh <sup>a,c</sup>,  
Hsiao-Pei Tu <sup>a</sup>, Min-Wen Fu <sup>a</sup>

<sup>a</sup> Department of Periodontology, School of Dentistry, National Defense Medical Center and Tri-Service General Hospital, Taipei City, Taiwan, ROC

<sup>b</sup> Dental Department, Taipei Tzu Chi Hospital, Buddhist Tzu Chi Medical Foundation, New Taipei City, Taiwan, ROC

<sup>c</sup> Department of Dentistry, Kaohsiung Veterans General Hospital, Taiwan, ROC

Received 28 December 2015; Final revision received 27 January 2016

Available online 29 March 2016

## KEYWORDS

bone;  
computerized  
tomography;  
mandibular canal

**Abstract** *Background/purpose:* High prevalence of bifid mandibular canals has been visualized with various types of computerized tomography (CT). Along the canals, a various ranged corticalization was recently reported. The depiction of the fine anatomic structures on multislice and cone-beam CT images was compared.

*Material and methods:* The presence or absence of the bifid canal was assessed on 327 images obtained by multislice CT (MSCT;  $n = 173$ ) or by cone-beam CT (CBCT;  $n = 154$ ), according to the configuration. The cortex thickness and distribution were also assessed.

*Results:* The prevalence of bifid canal detected by CBCT was significantly greater than that detected by MSCT (42.2% vs. 18.7% for hemi-mandibles and 58.4% vs. 30.6% for patients). Cortical thickness recorded by CBCT was significantly thinner than that recorded by MSCT (0.48 mm vs. 0.65 mm,  $P < 0.001$ ); however, the distributions of corticalization detected by the two tomography methods were similar. There was a significant association of cortex thickness with CT type and corticalization degree ( $R^2 = 0.530$ ,  $P < 0.001$ ).

\* Corresponding author. Department of Periodontology, School of Dentistry, National Defense Medical Center and Tri-Service General Hospital, P.O. Box 90048-507, Number 161, Section 6, Minquan East Road, Taipei, Taiwan, ROC.

E-mail address: [dentalab@tpts5.seed.net.tw](mailto:dentalab@tpts5.seed.net.tw) (E.-C. Shen).

**Conclusion:** Thinner cortices, but greater prevalence of bifid canals recorded by CBCT, compared to MSCT, suggests that clinicians should be cautious when using CT to interpret this fine anatomic structure.

Copyright © 2016, Association for Dental Sciences of the Republic of China. Published by Elsevier Taiwan LLC. This is an open access article under the CC BY-NC-ND license (<http://creativecommons.org/licenses/by-nc-nd/4.0/>).

## Introduction

The mandibular canal is a single bony structure with the inferior alveolar blood vessels and nerve running through the channel. However, anatomical aberrations such as bifid and trifid canals have been reported.<sup>1–4</sup> Nerve bundles and arteries have been observed within the bifid canals,<sup>5,6</sup> indicating the significance of bifid canals in the innervation and blood supply of the mandible. It is therefore important to be familiar with the anatomical details of the bifid mandibular canal to avoid neurovascular damage during surgical procedures involving the posterior mandible.<sup>6</sup>

A higher prevalence of bifid mandibular canals has been observed with various types of computerized tomography (CT)<sup>7,8</sup> and the CT images were compared to dental panoramic radiographs<sup>2,3,9,10</sup> because of the high-resolution and three-dimensional imaging quality of CT.<sup>11,12</sup> In addition, various degrees of corticalization along the bifid canals was observed on the CT images.<sup>13</sup> The exact role of corticalization of bifid canals is unknown; however, the presence of corticalization may have a critical role in the exploration of this area and in the identification of bifid canals because of its obvious radio-opacity. In the present study, 195 bifid mandibular canals and their corticalization were observed on multislice CT (MSCT,  $n = 154$ ) images or cone-beam CT (CBCT,  $n = 173$ ) images.

## Materials and methods

### Experimental design

All CT images were obtained for the needs of dental implant treatment and planning at the dental section of Taipei Tzu Chi General Hospital (New Taipei City, Taiwan) from July 2007 to September 2012. The study received the Institutional Review Board approval from, Taipei Tzu Chi Hospital. The CT images that had inadequate information or signs of previous major traumas or injuries were excluded. The CT images used and analyzed in this study were from MSCT (GE Light Speed VCT scanner; GE Healthcare, Milwaukee, WI, USA;  $n = 173$ ) or CBCT (KaVo 3D eXam scanner; Imaging Science International LLC, Hatfield, PA 19440, USA).

For MSCT, the scan parameters were helical pitch of 0.531; gantry rotation time, 1 second; tube voltage, 120 kV; and tube current, 300 mA. At 0.625-mm intervals, 2.5-mm axial images were obtained from the level of the apex of the mandibular symphysis to the level of the mandibular angle.

For the CBCT, the scan parameters were gantry rotation time of 7 millisecond; tube voltage, 120 kV; and tube current, 5 mA. At 0.25 mm intervals, 0.25-mm axial images were obtained from the level of the apex of the mandibular symphysis to the level of the mandibular angle. A total of 327 CT images were obtained: 167 from women and 160 from men. The participants' age ranged 23–85 years with a mean age of 51 years. Parts of images selected in this study were the same images used in our previous studies.<sup>11,13</sup> Using a dedicated 3DX software model (Hi-Aim Plan; Hi-Aim Biomedical Technology Inc., Taipei, Taiwan, R.O.C.), the length and width of the bifid canal were identified. The degree of corticalization<sup>13</sup> and the thickness of the cortex were also measured (Figure 1). A total of 195 bifid canals, which included 65 from MSCT and 130 from CBCT, were examined in this study. One radiologist (MP) performed all assessments and measurements of the CT images in this study.

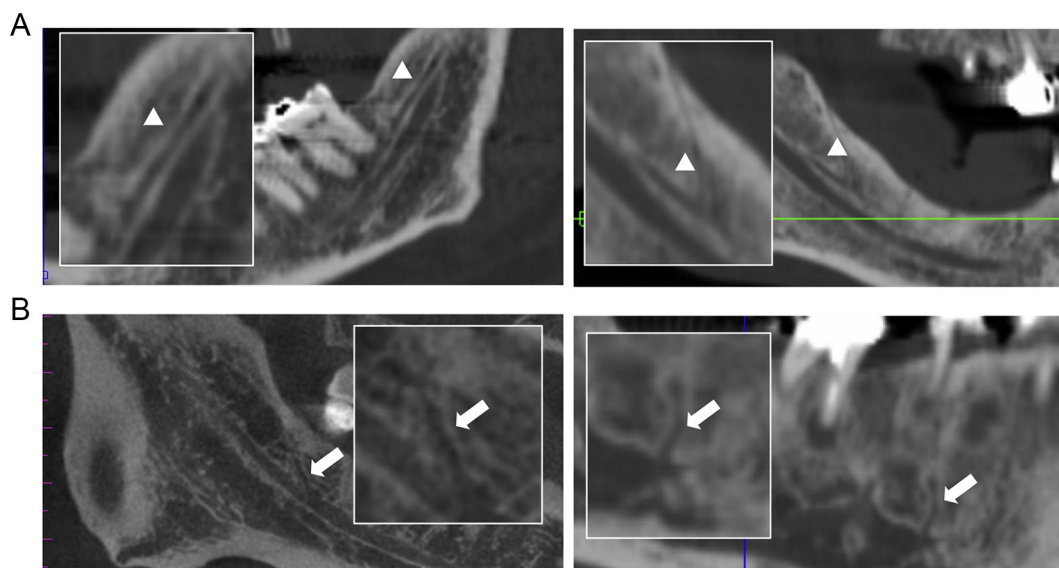
### Statistical analysis

The effectiveness of the CBCT and MSCT methods on determining the presence of the bifid canal was compared using the Chi-square test. The Student  $t$  test was used to compare the cortex thicknesses detected by the two examining CT methods. The effect of the degree of corticalization along the bifid canals on the cortex thickness was evaluated by the regression model. The association of the cortex thickness with possible related variables (e.g., CT type, age, sex, right/left hemi-mandible, length or width of the bifid canals, cortex thickness of mandibular main canal, and degree of corticalization) was examined by multiple regression analysis. All values are presented as the mean  $\pm$  the standard deviation. The null hypothesis was rejected at  $P < 0.05$ .

## Results

There were 195 (29.8%) bifid canals in 654 hemi-mandibles, which corresponded to a prevalence of 43.7% (i.e., 143/327 patients; Table 1). Using CBCT, the prevalence of bifid canals in 308 hemi-mandibles was 42.2%, which was significantly higher than the prevalence using MSCT (18.7% in 346 hemi-mandibles;  $P < 0.001$ ; Table 1). A higher prevalence of a bifid canal in the patients was also observed with CBCT than with MSCT (58.4% vs. 30.6%;  $P < 0.001$ ).

Along the bifid canals, the mean cortex thickness was 0.53 mm, and the thickness decreased when the degree of corticalization was reduced ( $P = 0.02$ ; Table 2). Cone-beam computed tomography and MSCT were equally



**Figure 1** Computed tomography images of the bifid canal structures. (A) MSCT images present the bifid mandibular canals (arrowheads) running in the retromolar regions of the hemi-mandibles in a 56-year-old man and an 80-year-old man. The bifid canals are 14.8 mm and 14.4 mm, respectively, in length, and 0.7 mm in width. The canals have complete coverage of the cortex (i.e., > 85%) or moderate coverage (50–84%) along the canal (the cortex thickness is 0.6 mm and 0.5 mm, respectively). (B) CBCT images show a bifid mandibular canal (white arrowhead) in a 48-year-old man and a 33-year-old man; it is 6.5 mm and 10.1 mm, respectively, in length, and 0.5 mm and 0.7 mm in width; the canal stays in the apical region of the right third molar and second premolars. The cortex coverage was moderate (in the range of 50–84% along the canal) and the cortex thickness was 0.5 mm for both canals). (The rectangular inserts are the high magnification of the areas of interest, magnification, 4 $\times$ ). CBCT = cone-beam computed tomography; MSCT = multislice computed tomography.

able to detect the degree of corticalization of the bifid canals (39%, 26%, 12%, and 23% of 65 bifid canals by MSCT and 42%, 22%, 12%, and 24% of 103 canals by CBCT for complete, moderate, mild, and minimal degree of corticalization, respectively); however, the thicknesses measured by CBCT were significantly lower than those

measured by MSCT (with a mean of 0.48 mm and 0.65 mm by CBCT and MSCT, respectively;  $P < 0.001$ ; Table 3). The influence of the degree of corticalization and CT type on the cortex thicknesses of bifid canals was also confirmed by multiple regression analysis ( $P < 0.001$  and  $R^2 = 0.530$ ; Table 4).

**Table 1** The prevalence of the bifid mandibular canals in the examined patients or hemi-mandibles.

	Multislice CT	Cone-beam CT	Total
<b>Patients</b>			
Presence of bifid canals	53 (30.6)	90 (58.4)*	143 (43.7)
Bilateral bifid canals	12 (6.4)	40 (26.0)	52 (15.9)
Unilateral bifid canals	41 (24.3)	50 (32.5)	91 (27.8)
Right hemi-mandible	25 (14.5)	34 (22.1)	59 (18.0)
Left hemi-mandible	16 (9.8)	16 (10.4)	32 (9.7)
Absence of bifid canals, bilaterally	120 (69.4)	64 (41.6)	184 (56.3)
Total patients examined	173 (100)	154 (100)	327 (100)
<b>Hemi-mandibles</b>			
Presence of bifid canals	65 (18.7)	130 (42.2)*	195 (29.8)
Bilaterally bifid canals	24 (6.9)	80 (26.0)	104 (15.9)
Unilaterally bifid canals	41 (11.9)	50 (16.2)	91 (13.9)
Right hemi-mandible	25 (7.2)	34 (11.0)	59 (9.0)
Left hemi-mandible	16 (4.6)	16 (5.2)	32 (4.9)
Absence of bifid canals	281 (81.2)	178 (57.8)	459 (70.1)
Total hemi-mandibles examined	346 (100)	308 (100)	654 (100)

The data are presented as  $n$  (%) of the patients or hemi-mandibles examined by multislice computed tomography (CT) and/or cone-beam CT.

\* Indicates a significant difference at  $p < 0.01$ , versus multislice CT.

**Table 2** The cortex thicknesses of 185 mandibular bifid canals depicted on computed tomography images.

Cortex thickness (mm)	
Degree of corticalization (%)	
Complete (>85)	0.55 ± 0.17
Moderate (50–84)	0.53 ± 0.17
Mild (16–49)	0.48 ± 0.12
Minimal (from >0 to <15)	0.45 ± 0.09
Zero (0)	nd
Total of bifid canals	0.53 ± 0.16

The data are presented as the mean ± the standard deviation of cortex thickness.

nd = not done because of absence.

## Discussion

A high prevalence of mandibular bifid canals has been reported in certain human populations.<sup>7,8,11,14,15</sup> However, the information about this fine anatomical structure remains limited. The present study is the first to measure the cortex thickness along the bifid canals and to evaluate the factors related to its measurement, although various degrees of corticalization were observed along mandibular bifid canals in our previous study.<sup>13</sup> From CT images of the 195 bifid canals that were assessed, the mean cortex thickness was 0.53 mm (Table 1). In addition, cortex thickness decreased in bifid canals as the degree of corticalization decreased (Table 2). Based on multiple regression analysis, the influence of the degree of corticalization on the cortex thickness was significant (Table 2). Moreover, the method of CT also significantly influenced the cortex thickness measurements. The mean cortex thicknesses of bifid canals were 0.39 mm and 0.52 mm using CBCT and MSCT, respectively. The reason for the different cortex thicknesses between the two CT methods is unclear. One factor may be the differences in image quality between the two CT methods. For instance, 0.25-mm intervals and 0.25-mm axial images were obtained with the CBCT in the present study, whereas 0.625-mm intervals and 2.5-mm axial images were obtained through the MSCT.

**Table 4** Association of the cortex thickness of bifid canals with the variables examined.

Variables	Cortex thickness (mm)	
	$\beta$	P
Constant	0.283	
Degree of corticalization	0.67	<0.001*
CT types	-0.228	<0.001*
Bifid length	-0.69	0.209
Bifid width	0.76	0.146
Right or left hemi-mandible	-0.08	0.135
Sex	-0.24	0.650
Age	0.027	0.613

\* Indicates significance at  $p < 0.05$ , based on multiple regression analysis.

CBCT = cone-beam computed tomography; CT = computed tomography; MSCT = multislice computed tomography.

CT has become one of the most common diagnostic imaging modalities for dental practice, and the high prevalence of bifid canals has been assessed on CT images.<sup>7,8</sup> In the present study, the cortex thicknesses along the bifid canals were recorded from images taken by MSCT or CBCT.

In a recent study, 28 Japanese patients underwent both the MSCT and CBCT for a comparison between the two CT methods in the detection discrepancy of fine anatomical structures in the mandible.<sup>16</sup> The result showed that 68% of the bifid canals (19 detected) could be successfully detected by CBCT and MSCT; 21% of the canals could only be found in CBCT, whereas 11% could only be detected in MSCT. The authors therefore suggested that the depiction of fine anatomic features in the mandible associated with neurovascular structures was consistent between CBCT and MSCT images. In another study, however, the inter- and intraobserver agreement showed that the CBCT systems were rated superior to MSCT devices in terms of image quality for all dental structures such as identifying the enamel-dentin and dentin-pulp interface and the periodontal ligament space.<sup>17</sup> A more distinct canal distribution was observed in the limited CBCT images than in the MSCT images by inspection on a Japanese cadaver.<sup>5</sup> The superior image quality of CBCT may partially explain why our results

**Table 3** Comparison of multislice computed tomography and cone-beam computed tomography on the measurement of corticalization thickness along the bifid canals.

	Cortical thickness (mm)		Bifid canals present		
	MSCT	CBCT	MSCT	CBCT	Total
Degree of corticalization (%)					
Complete (>85)	0.67 ± 0.17	0.49 ± 0.14*	25 (39)	54 (42)	79
Moderate (50–84)	0.63 ± 0.21	0.48 ± 0.12*	17 (26)	29 (22)	46
Mild (16–49)	0.60 ± 0.08	0.43 ± 0.10*	8 (13)	16 (12)	24
Minimal (from >0% to <15%)	0.60 ± 0.00	0.40 ± 0.00*	3 (5)	7 (5)	10
Zero (0)	nd	nd	11 (17)	24 (19)	35
Total of bifid canals	0.65 ± 0.17	0.48 ± 0.13*	64 (100)	130 (100)	194

The data are presented as the mean ± standard deviation of the recorded cortex thickness and as the percentage of bifid canals among the total canals detected by MSCT or CBCT.

\* Indicates a significant difference, versus MSCT, at  $p < 0.001$ .

CBCT = cone-beam computed tomography; MSCT = multislice computed tomography; nd = not done due to absence.

showed a thinner cortex and why CBCT identified a higher prevalence of bifid mandibular canals.

Studies have clearly shown that the prevalence of bifid mandibular canals identified by CT imaging<sup>7,8</sup> is higher than that identified by dental panoramic radiographs.<sup>2,3,9,10</sup> One possible reason is the higher resolution and three-dimensional imaging capability of CT.<sup>11,12</sup> The thin cortex and the high prevalence of bifid canals assessed by CBCT, compared to their assessment by MSCT in the present study, may also be influenced by the high image quality of CBCT. In this study, the prevalence of bifid canals based on CBCT was 58.4% (90/154) for patients and 42.2% (130/308) for hemi-mandibles (Table 1). A similar prevalence (43–46% for hemi-mandibles) has also been reported in recent studies with CBCT.<sup>14,15</sup> The contrast in density and the obvious radio-opacity in radiography may be helpful in sketching or depicting fine anatomic structures such as bifid canals, and the structures' corticalization. However, the precise nature of this fine anatomic structure (i.e., the bifid canal) needs further investigation.

In conclusion, this study was the first to measure the cortex thickness along the bifid canals on the CT images and to evaluate factors related to the recorded thicknesses. From the 195 bifid canals identified, a mean cortex thickness of 0.53 mm was recorded; however, it decreased with the degree of corticalization. Two factors—the degree of corticalization of bifid canals and the CT method—significantly influenced the thickness measurement. In images obtained by CBCT, a thinner cortex thickness was observed, compared to measurements obtained by MSCT, and a higher prevalence of bifid canals was identified by CBCT than by MSCT. Our results also suggested that clinicians need to be cautious when using computed tomography to read the fine anatomical structures of bifid canals to avoid neurovascular damage during surgical procedures.

## Conflicts of interest

The authors have no conflicts of interest relevant to this article.

## Acknowledgments

This study was supported by a grant from Tzu Chi Hospital, Buddhist Tzu Chi Medical Foundation (Taipei, Taiwan; grant number, TCRD-TPE-104-RT-3).

## References

- Kiersch TA, Jordan JE. Duplication of the mandibular canal. *Oral Surg Oral Med Oral Pathol Oral Radiol* 1973;35:133–4.
- Langlais RP, Broadus R, Glass BJ. Bifid mandibular canals in panoramic radiographs. *J Am Dent Assoc* 1985;110:923–6.
- Nortje CJ, Farman AG, Grotepass FW. Variations in the normal anatomy of the inferior dental (mandibular) canal: a retrospective study of panoramic radiographs from 3612 routine dental patients. *Br J Oral Surg* 1977;15:55–63.
- Wadhvani P, Mathur RM, Kohli M, Sahu R. Mandibular canal variant: a case report. *J Oral Pathol Med* 2008;37:122–4.
- Fukami K, Shiozaki K, Mishima A, Kuribayashi A, Hamada Y, Kobayashi K. Bifid mandibular canal: confirmation of limited cone beam CT findings by gross anatomical and histological investigations. *Dentomaxillofac Radiol* 2012;41:460–5.
- Naitoh M, Hiraiwa Y, Aimiya H, et al. Bifid mandibular canal in Japanese. *Implant Dent* 2007;16:24–32.
- Kuribayashi A, Watanabe H, Imaizumi A, Tantanapornkul W, Katakami K, Kurabayashi T. Bifid mandibular canals: cone beam computed tomography evaluation. *Dentomaxillofac Radiol* 2010;39:235–9.
- de Oliveira-Santos C, Souza PH, de Azambuja Berti-Couto S, et al. Assessment of variations of the mandibular canal through cone beam computed tomography. *Clin Oral Investig* 2012;16:387–93.
- Grover PS, Lorton L. Bifid mandibular nerve as a possible cause of inadequate anesthesia in the mandible. *J Oral Maxillofac Surg* 1983;41:177–9.
- Sanchis JM, Penarrocha M, Soler F. Bifid mandibular canal. *J Oral Maxillofac Surg* 2003;61:422–4.
- Fu E, Peng M, Chiang CY, Tu HP, Lin YS, Shen EC. Bifid mandibular canals and the factors associated with their presence: a medical computed tomography evaluation in a Taiwanese population. *Clin Oral Implant Research* 2014;25:e64–7.
- Rouas P, Nancy J, Bar D. Identification of double mandibular canals: literature review and three case reports with CT scans and cone beam CT. *Dentomaxillofac Radiol* 2007;36:34–8.
- Shen EC, Fu E, Fu MM, Peng M. Configuration and corticalization of the mandibular bifid canal in a Taiwanese adult population: a computed tomography study. *Int J Oral Maxillofac Implants* 2014;29:893–7.
- Orhan K, Aksoy S, Bilecenoglu B, Sakul BU, Paksoy CS. Evaluation of bifid mandibular canals with cone-beam computed tomography in a Turkish adult population: a retrospective study. *Surg Radiol Anatomy* 2011;33:501–7.
- Naitoh M, Hiraiwa Y, Aimiya H, Arijji E. Observation of bifid mandibular canal using cone-beam computerized tomography. *Int J Oral Maxillofac Implants* 2009;24:155–9.
- Naitoh M, Nakahara K, Suenaga Y, Gotoh K, Kondo S, Arijji E. Comparison between cone-beam and multislice computed tomography depicting mandibular neurovascular canal structures. *Oral Surg Oral Med Oral Pathol Oral Radiol Endod* 2010;109:e25–31.
- Hofmann E, Schmid M, Sedlmair M, Banckwitz R, Hirschfelder U, Lell M. Comparative study of image quality and radiation dose of cone beam and low-dose multislice computed tomography—an in-vitro investigation. *Clin Oral Investig* 2014;18:301–11.