

# Surgical outcome in cystic vestibular schwannomas

Suresh Nair, Sachin S. Baldawa, Chittur Viswanathan Gopalakrishnan, Girish Menon, Vazhayil Vikas, Jayanand B. Sudhir

Department of Neurosurgery, Sree Chitra Tirunal Institute for Medical Sciences and Technology, Trivandrum, Kerala, India

## ABSTRACT

**Background:** Cystic vestibular schwannomas (VS) form a rare subgroup that differs from the solid variant clinically, radiologically, and histopathologically. These tumors also vary in their surgical outcome and carry a different risk of post-operative complications. We analyzed our series of 64 patients with cystic VS and discuss the technical difficulties related to total excision of these tumors and focus on complication avoidance.

**Materials and Methods:** A retrospective review of cystic VS surgically managed over a span of 11 years. The case records were evaluated to record the clinical symptoms and signs, imaging findings, surgical procedure, complications, and follow-up data. Post-operative facial nerve palsy was analyzed with respect to tumor size and tumor type.

**Results:** Progressive hearing impairment was the most common initial symptom (76.6%). Atypical initial symptoms were present in 15 patients (23.4%). Preoperatively, 78% patients had good facial nerve function (HB grade 1, 2) and 22% had intermediate (HB grade 3, 4) to poor (HB grade 5 and 6) function. Mean tumor size was 4.1 cm. Complete tumor removal was achieved in 53 patients (83%). The facial nerve was anatomically intact but thinned out after tumor excision in 38 patients (59.4%). Ninety percent patients had either intermediate or poor facial nerve function at follow-up. Poor facial nerve outcome was associated with giant tumors and peripherally located, thin-walled cystic tumors.

**Conclusion:** Resection of cystic VS is complicated by peritumoral adhesions of the capsule to the nerve. Extensive manipulation of the nerve in order to dissect the tumor–nerve barrier results in worse facial nerve outcome. The outcome is worse in peripherally located, thin-walled cystic VS as compared to centrally located, thick-walled cystic tumors. Subtotal excision may be justified, especially in tumors with dense adhesion of the cyst wall to the facial nerve in order to preserve nerve integrity.

**Key words:** Cystic vestibular schwannoma, facial nerve palsy, vestibular schwannoma

## Introduction

Intracranial schwannomas are common neoplasms, accounting for 8-10% of all primary intracranial neoplasms.<sup>[1,2]</sup> Tumors in the cerebellopontine angle account for 5-10% of all intracranial tumors.<sup>[3]</sup> In the cerebellopontine angle, vestibular schwannoma (VS) is the most common lesion, contributing to 80% of all tumors.<sup>[2,4,5]</sup> The occurrence of cysts within VS

is relatively rare.<sup>[3,5,6]</sup> The true incidence of cystic VS is not known, as universally accepted criteria to define cystic VS do not exist. Various case series report an incidence varying from 4-48%.<sup>[3,5,7-13]</sup> Recent series suggest an incidence of around 10%.<sup>[14]</sup> The incidence of 5.7% is probably more accurate as reported by Fundova *et al.*<sup>[15]</sup> This study had strict criteria for classification of a tumor as cystic, based on CT or MRI appearance, operative, and immunohistological verification. Cyst formation is more frequent in giant schwannomas, as larger tumors undergo a higher rate of degeneration and necrosis than do tumors of smaller size.<sup>[16,17]</sup>

Cystic VS differs from the solid variant clinically, radiologically, histopathologically, and also in terms of surgical outcome. These tumors carry a different risk of post-operative complications when compared to their solid counterpart.<sup>[4,6]</sup> Certain unique features reported in cystic VS are larger size, presentation with atypical initial symptoms like dysgeusia, vertigo, facial pain and gait unsteadiness, short duration of symptoms, rapid progression of symptoms or sudden deterioration, frequent involvement of facial nerve, unusual displacement of the facial nerve, unpredictable biologic behavior, poor facial nerve

### Access this article online

#### Quick Response Code:



#### Website:

www.asianjns.org

#### DOI:

10.4103/1793-5482.145359

### Address for correspondence:

Dr. Suresh Nair, Department of Neurosurgery, Sree Chitra Tirunal Institute for Medical Science and Technology, Trivandrum, Kerala, India. E-mail: snair1952@yahoo.com

outcome, and poor surgical outcome with higher incidence of subtotal tumor excision.

In this study, we present our series of 64 patients with cystic VS treated surgically. The aim was to analyze the clinical characteristics to assess facial nerve preservation and operative outcome of surgically treated cystic VS. We compare our results with other series on cystic VS with regard to clinical manifestations and surgical morbidity.

## Materials and Methods

A total of 488 cases of vestibular schwannomas were surgically managed during the period from January 1998 to December 2008 at our institute. Among these, 64 patients (13.1%) were diagnosed to have cystic VS on neuroimaging. We defined cystic VS as one, in which the cyst component constituted greater than 50% of the solid component on imaging calculated as percentage of volume. Case records were reviewed to analyze data such as patient demographics, symptoms and signs at presentation, and the presence of preoperative cranial nerve deficits. Audiometry charts were evaluated, and extent of hearing loss was documented using the Gardner Robertson classification. Radiological investigations including CT and/or MR images were examined for estimating tumor size by measuring the mean maximum anteroposterior and mediolateral diameters. Cysts were classified according to Piccirillo's classification,<sup>[1]</sup> which identified cystic VS as follows:

Type A – central and thick-walled cysts, which were further subdivided as

1. Polycystic (multiple small intra-tumoral cysts with thick cyst wall)
2. Polycystic (multiple moderate-sized intra-tumoral cysts with thick cyst wall)
3. Monocystic (single large cyst)

Type B – peripheral and thin-walled cysts

1 – Anterior, 2 – Medial, 3 – Posterior, 4 – Combined.

All patients underwent tumor excision through retrosigmoid sub-occipital approach in lateral position by the senior author (S.N). Standard microsurgical techniques were used in all patients. Adjuncts like cavitron ultrasonic surgical aspirator and facial nerve monitoring were used in cases operated after 2004 when it became available in our hospital. Operation records were analyzed for type of tumor and anatomical preservation of facial nerve. The extent of tumor removal was classified as either total or subtotal depending on the intra-operative impression of the surgeon and post-operative imaging. Surgical morbidity was assessed in terms of Glasgow outcome scale.

The pre-operative and post-operative facial nerve function at discharge, 6 months, and at follow-up on was recorded

according to the House Brackmann (HB) classification system. An attempt was made to see if any correlation exists between the type of cyst based on Piccirillo's classification<sup>[1]</sup> and facial nerve outcome at 6 months. Patients were grouped into three depending on the degree of facial nerve palsy:

Group 1: Good facial nerve function: HB grade 1 or 2

Group 2: Intermediate facial nerve function: HB grade 3 or 4

Group 3: Poor facial nerve function: HB grade 5 or 6

Patients were also divided into two groups in order to facilitate comparison of facial nerve outcome in different series:

Group A: Favorable outcome (HB Grade 1-3)

Group B: Unfavorable outcome (HB Grade 4-6)

Descriptive statistical analysis was carried out for data analysis. Significance was assessed at 5% level of significance. Paired proportion test was used to find the significance of change. SAS 9.2, SPSS 15.0, Stata 10.1, MedCalc 9.0.1, Systat 12.0, and R environment ver. 2.11.1 was used for data analysis.

Significant figures

Suggestive significance ( $P$  value:  $0.05 < P < 0.10$ )

Moderately significant ( $P$  value:  $0.01 < P \leq 0.05$ )

Strongly significant ( $P$  value:  $P \leq 0.01$ )

## Results

Age ranged from 17 years to 72 years with the mean age being 45.5 years. The most common age group was in fourth decade (31.2%) followed by fifth decade (26.6%). There were 30 males (46.9%) and 34 (53.1%) females in the study population. The most common initial symptom was progressive hearing impairment in 49 (76.6%) patients. Atypical initial symptoms were present in 15 (23.4%) patients [Table 1]. Table 2 shows the clinical symptoms and signs at presentation. Mean duration of initial symptoms was 18 months (range: 1-68 months), being shortest for lower cranial and facial nerve palsy (3.29 and 4.47 months, respectively) as shown in [Table 3]. Preoperatively, 78% patients had good facial nerve function (HB grade 1 and 2) while 22% of patients had intermediate (HB grade 3 and 4) to poor (HB grade 5 and 6) facial nerve function.

All patients underwent pre-operative imaging namely, CT in 12, MR imaging in 13, or both in 39 patients. In general, non-contrast CT revealed isodense tumors with areas of

**Table 1: Atypical initial symptoms in cystic VS**

Atypical Initial symptoms	Number of patients (n=64)	%
Unsteadiness of gait	6	40
Headache	3	20
Facial numbness	2	13.3
Vertigo	2	13.3
Facial pain	1	6.6
Dysguesia	1	6.6
Total	15	100

hypodensity in the cerebellopontine angle. On contrast administration, only the isodense areas showed enhancement. T1-weighted images on MRI revealed isointense tumors with hypointense areas within. T2-weighted imaging revealed hyperintense cysts within the tumor that varied in size and number but had similar signal characteristics between tumors. On gadolinium administration, enhancement of cyst wall was evident. Evidence of bleed in form of fluid-fluid level [Figure 1] was seen on imaging in 12 cases (18.7%). Figures 2-4 shows different types of cystic VS. Tumor size ranged from 2.7 cm to 6.6 cm. Mean tumor size was 4.1 cm. Giant cystic VS (>4 cm) were observed in 37 cases (57.8%). Sixty-one patients (95.3%) had large VS (3 × 2 cm). Mild to moderate hydrocephalus was

present in 40 patients (62.5%). CSF diversion prior to definitive surgery was necessary in 5 patients (12.5%) in view of raised intracranial pressure at the time of admission. Cysts were classified according to Piccirillo's classification<sup>[1]</sup> [Table 4]. Type A2 and B4 contributed 37.5% and 14.2% according to Piccirillo classification.<sup>[1]</sup>

Complete tumor removal was achieved in 53 patients (83%). Eleven patients (17%) underwent subtotal removal due to extensive adherence to brainstem, lower cranial nerves, or the facial nerve. In 26 patients (40.6%), the facial nerve could not be preserved. The facial nerve was intact but thinned out in 38 patients (59.4%). Post-operative CSF diversion was necessary in 4 patients (6.3%) in view of symptomatic hydrocephalus. Overall, there was no post-operative mortality defined as death within 30 days of surgery. However, 1 patient died due to sepsis, following aspiration pneumonia, 4 months after surgery.

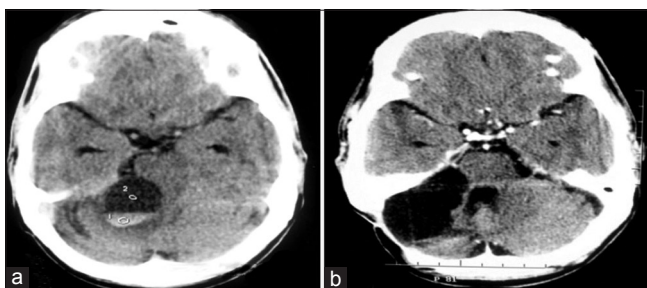
Follow-up period ranged from 6 months to 13 years (mean: 4.8 years). Twelve patients were lost to follow-up after 6 months. Table 5 demonstrates facial nerve function prior to surgery, at 6 months, and on follow-up. Good facial nerve function was seen in 78% patients prior to surgery while at 6 months and on follow up, 90% patients had either intermediate or poor facial nerve function. In patients with anatomical preservation of facial nerve, two third of patients had HB grade 4 and 5 facial palsy, 6 months after

**Table 2: Symptoms and signs at the time of presentation**

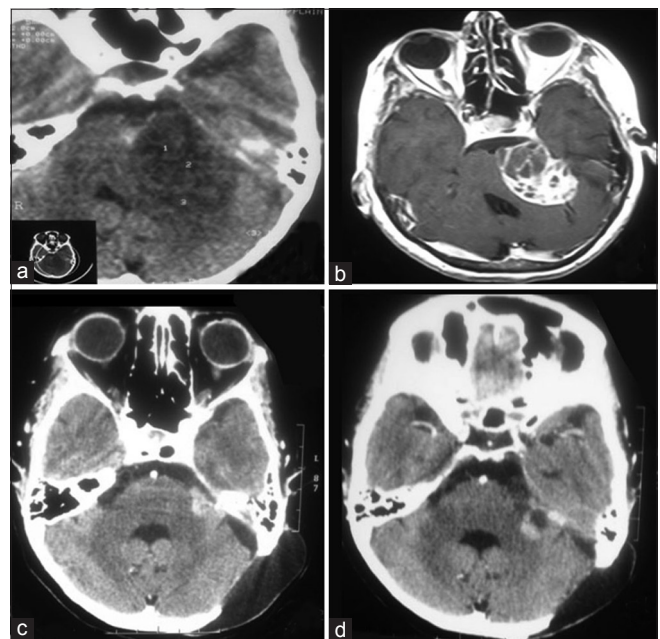
Symptoms and signs	Number of patients (n=64)	%
Hearing Impairment	63	98.4
Gait ataxia	61	95.3
Facial numbness	57	89
Dysguesia	42	65.6
Facial weakness	36	56.2
Tinnitus	22	34.3
Raised ICP	20	31.2
Lower cranial nerve	16	25
Vertigo	12	18.7
Fifth nerve (Motor)	12	18.7
Pyramidal signs	10	15.6
Hemiparesis	5	7.8
Sixth nerve	4	6.2
Visual deterioration	4	6.2
Seizures	1	1.5

**Table 3: Mean duration of symptoms**

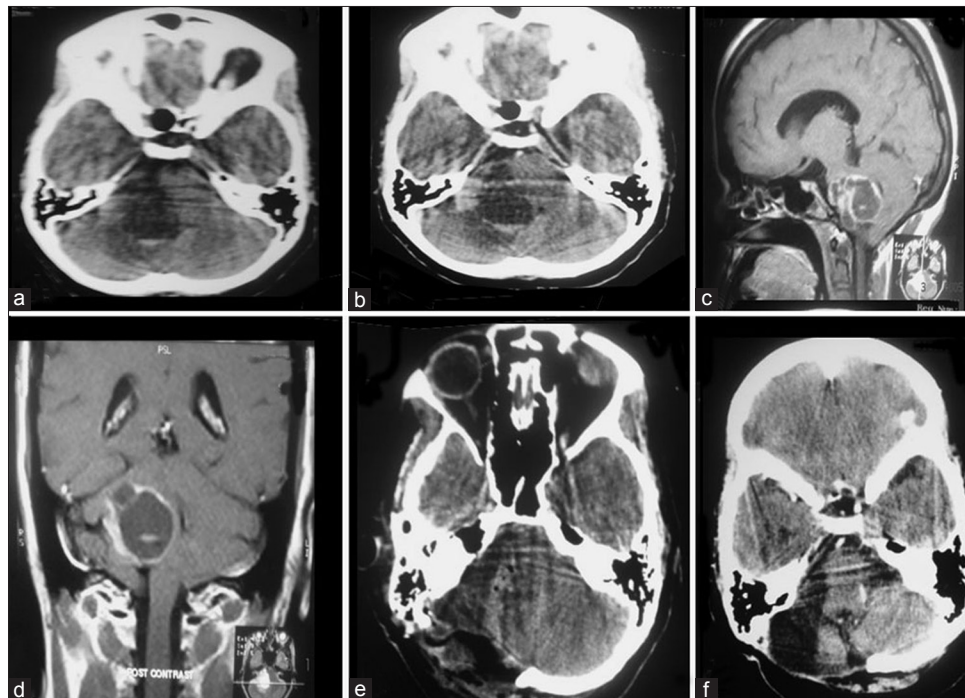
Symptoms	Duration (months) mean±SD
Hearing loss	15.87±24.70
Fifth nerve	7.18±7.81
Seventh nerve	4.47±5.71
Lower cranial nerve	3.29±3.45
Cerebellar	5.95±6.71



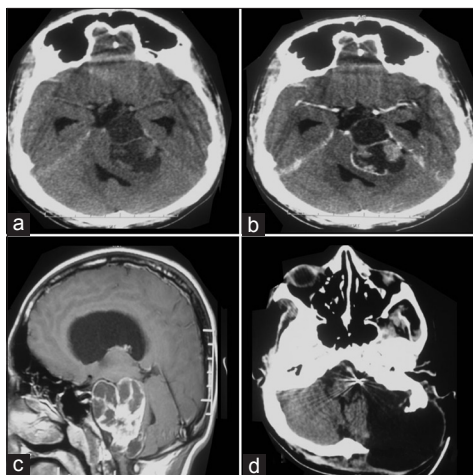
**Figure 1:** Piccirillo type A3 cystic VS. non-contrast CT (a) demonstrating a hypodense lesion in the right cerebellopontine angle with hyperdensity, suggestive of bleed within the tumor. Post-contrast CT (b) done after six years did not reveal any tumor recurrence



**Figure 2:** Piccirillo type A1 cystic VS. plain CT (a) demonstrating a heterogenous density lesion in the left cerebellopontine angle. Axial post-gadolinium MR image (b) showing the polycystic nature of the tumor. Post-operative CT (c) with specks of blood at the operative site. Post-contrast CT (d) four years after surgery showing ring enhancement at the internal auditory meatus suggestive of recurrence. This patient was kept on follow-up imaging



**Figure 3:** Piccirillo type B2 cystic VS. plain (a) and contrast CT (b) brain showing a hypodense lesion in right cerebellopontine angle with enhancing solid component near the meatus, enhancing cyst wall and evidence of fluid level. Sagittal (c) and coronal (d) post-gadolinium MR images demonstrating a cyst with rim enhancement. Immediate post-excision CT (e) and one (f) taken four years after surgery showing no evidence of tumor



**Figure 4:** Piccirillo type A2 cystic VS. (a, b) CT brain showing a large hypodense lesion in the left cerebellopontine angle with an isodense solid component within. The septations within the cyst and the wall reveals prominent enhancement following contrast administration. Sagittal MR image (c) demonstrating the multicystic nature of the tumor and its vertical extent. CT (d) done at 6 months after surgery revealing a large pseudomeningocele that was managed with a lumboperitoneal shunt

surgery. Higher-grade facial palsy at 6 months (4, 5, and 6) was associated with giant cystic VS [Table 6]. Unfavorable grade of facial palsy was seen more often in Piccirillo’s type B cysts (90%) as compared to type A cyst (74%) [Table 4]. Though *P* value did not reach statistical significance, it was suggestive of significance. Post-operative complications included pseudomeningocele in 4 patients, paradoxical CSF

**Table 4: Type of cystic VS according to Piccirillo classification<sup>[1]</sup> and facial nerve outcome at 6 months depending on the tumor type**

Type of cystic VS	Number of patients	Favourable grade (1-3)	Unfavourable grade (4-6)	Total
A1	5	11 (17.5)	32 (50.8)	43
A2	24			
A3	14			
B1	2	2 (3.2)	19 (29.6)	21
B2	5			
B3	5			
B4	9			

rhinorrhea in 3, meningitis and cerebellar infarct in 2 each. Three patients had tumor recurrence on follow-up imaging that required re-excision.

### Discussion

Cystic VS are a subgroup of VS with unique clinical, imaging features, and surgical outcome. The incidence of cystic VS varies depending on what percentage of cysts constitutes VS. In the present series, the incidence of cystic VS (13.1%) closely corresponds to Kameyama *et al.*<sup>[5]</sup> series (13.5%).

The pathogenesis of cysts within VS is not definitely known. Several postulates have been proposed for mechanism of cyst formation and enlargement. Cyst formation is due to coalescence of microcysts in Antoni type B tissue with

compressed surrounding Antoni type A tissue.<sup>[2,5,7,18-21]</sup> Thus, enlargement is mainly due to the expansion of the cyst component rather than high growth rate of tumor cells.<sup>[18,21,22]</sup> Extravasation of serum proteins from an impaired blood tumor barrier or protein secretion from tumor cells can lead to cyst enlargement due to an osmotic effect. Intra-tumoral cyst may also arise from previous bleeding within the lesion or following repeated microhemorrhages as evidenced by hemosiderin-laden macrophages, hemosiderin deposits, and abnormal vessel proliferation.<sup>[2,21,23]</sup>

The rapid clinical worsening or acute evolution of symptoms in cystic VS is due to sudden expansion of cysts, causing compression of surrounding structures, distortion of the brain-stem, stretching the cranial nerves, and a rapid rise of intracranial pressure that results in significant neurological deficits before compensatory mechanisms occur.<sup>[4,16,24]</sup> It is known that the level of matrix metalloproteinase 2 (MMP 2) is higher in the cyst fluid. This results in peritumoral adhesions, as the tumor-nerve barrier is impaired, leading to different clinical and surgical outcome.<sup>[6]</sup>

Cystic VS tend to present with atypical initial symptoms like facial pain or facial palsy rather than hearing loss. In our series, nearly one-fifth presented with atypical initial symptoms, mainly unsteadiness of gait, headache, facial pain, numbness, and dysguesia attributable to the rapidly expanding cysts rather than tumor size alone. The most common initial symptom was hearing loss (76.5%). Benech *et al.*<sup>[4]</sup> also reported a high incidence (81%) of hearing loss as an initial symptom. The mean duration of overall symptoms in this study was

15 months, comparable to the series by Moon *et al.*<sup>[6]</sup> and Sinha *et al.*<sup>[3]</sup> (14 and 16 months, respectively). Table 7 provides an overall comparison of our study findings with that published in literature. Pre-operative facial palsy observed in 56.2% patients was comparable to that observed in Kameyama *et al.*<sup>[5]</sup> study (64.2%). This is in contrast to the articles by Wandong *et al.*<sup>[2]</sup> and El Bahy *et al.*<sup>[25]</sup> where they reported a less than 20% incidence of pre-operative facial palsy. The highest incidence has been reported by Sinha *et al.*<sup>[3]</sup> Cystic VS are large in size (> 3 cm) and frequently giant (> 4 cm) at presentation. Our mean tumor size of 4.1 cm is comparable to other series [Table 7].

Cystic VS lack the typical radiological features of VS like erosive enlargement of internal auditory canal or enhancement of intra-canalicular portion.<sup>[5]</sup> Enhancement surrounding the cyst on Gadolinium administration is due to the presence of enveloping tumor tissue and/or inflammatory reaction to the fluid contents of the cyst.<sup>[11,16]</sup> The presence of fluid-fluid levels and hemosiderin deposits suggests microhemorrhages as possible cause for cyst formation.<sup>[21]</sup> The occurrence of obstructive hydrocephalus requiring CSF diversion is less frequent in cystic VS.<sup>[4]</sup> One possible explanation is that cysts deform to the shape of the surrounding neural structures rather than causing compression on them.<sup>[4]</sup> Pre-operative CSF diversion was done in 12.5% of patients in our series that is substantially less compared to reports by El Bahy *et al.*<sup>[25]</sup> and Benech *et al.*<sup>[4]</sup> (23% and 27%, respectively). Sinha *et al.*<sup>[3]</sup> had the highest incidence of pre-operative CSF diversion (48.3%), probably due to a high mean tumor size.

## Treatment

The treatment options for VS include observation, surgical excision, or radiosurgery. The “wait and scan” policy is not recommended in cystic VS, as rapid expansion of cyst elements can cause acute neurological deterioration. Though conflicting views exist over the surgical outcome in cystic VS with respect to facial nerve,<sup>[5,15,24,26,27]</sup> it is now generally accepted that the occurrence of cysts in VS is predictive of a worse surgical outcome as compared to its solid counterpart of similar size.<sup>[4,6,22,24,28-30]</sup> Even though surgery in cystic VS may appear to be easy and quick in terms of initial debulking than in solid tumor, there is a high incidence of accidental facial nerve injury. This is due to peri-cyst adhesions with absence of adequate tumor-arachnoid dissection plane, especially if the cysts are located anteriorly in intimate relation to the facial nerve.<sup>[1,5,6,29]</sup> The facial nerve may also be displaced in a different position depending on the pattern of cyst growth. In solid tumors, the nerve is almost constantly in a lower anterior position.<sup>[31]</sup> The solid portion in cystic VS is more vascular, leading to greater chances for intra-operative bleeding. However, Jones *et al.*<sup>[14]</sup> concluded that worse facial nerve outcome following surgery for cystic VS is due to their size and not due to the presence of a cysts *per se*. Samii *et al.*<sup>[30]</sup> reported that the rate of anatomic facial nerve preservation decreases from 93% in solid tumors

**Table 5: Postoperative facial nerve function compared to preoperative status**

HB grade	Preoperative (n=64) (%)	Postoperative at 6 months (n=63) (%)	Postoperative at last followup (n=51) (%)	P value
1	28 (43.8)	1 (1.6)	1 (1.9)	<0.001
2	22 (34.4)	3 (4.8)	3 (5.9)	<0.001
3	7 (10.9)	9 (14.3)	7 (13.7)	0.344
4	6 (9.4)	16 (25.4)	12 (23.5)	0.038
5	0	30 (47.6)	26 (50.9)	<0.001
6	1 (1.6)	4 (6.4)	2 (3.9)	0.242

**Table 6: Patients grouped according to facial palsy (HB Grade) at 6 months and tumor size**

HB grade	No of patients (n=63)	%	Mean tumor size (cm)
1	1	1.6	3.5
2	3	4.8	3.6
3	9	14.3	3.7
4	16	25.4	4.5
5	30	47.6	4.3
6	4	6.3	4.7

**Table 7: Comparison of present series with other major series**

	Incidence	Mean age	M %	F %	Duration of initial symptom	Mean duration of symptom (month)	Preop. facial palsy (%)	Tumor size (mm)	Preop. CSF diversion (%)	Total excision	Anatomical preservation of VII nerve	Overall good VII nerve function (1-3)
Present series	13.1	45.5	46.8	53.2	1 month-14 yrs	15	56.2	41	12.5	82.8	59.3	20.5
Piccirillo <sup>[1]</sup>	6.7	51	48	52	-	-	-	28	-	82	-	81
Sinha <sup>[3]</sup>	20.4	39.5	65.5	34.5	-	16	89.6	58	48.3	75.9	60.6	67.9
Mehrotra <sup>[16]</sup>	21.2	42.1	-	-	-	26.2	-	-	4.5	82	95.4	-
Moon <sup>[6]</sup>	-	40.5	50	50	-	14	-	44	-	100	75	-
El Bahy <sup>[25]</sup>	-	-	-	-	4 months-5 years	-	15.4	-	23	54	54	-
Benech <sup>[4]</sup>	20.3	58	61.5	38.5	-	-	-	45	27	92	73	-
Wandong <sup>[2]</sup>	7.6	46	54.5	45.5	2 month-10 years	-	18.1	-	-	81.8	86.4	59
Kameyema <sup>[5]</sup>	13.5	59	42.8	57.2	6 month-10 years	-	64.2	29	-	85.7	-	-

to 88% in cystic VS. Hence, total resection with preservation of the facial nerve is more difficult.<sup>[2]</sup> Sharp dissection technique to separate the peritumoral adhesences must be employed to avoid traction on facial nerve.<sup>[4]</sup> Though the overall surgical goal is total tumor excision, cystic VS may be partially excised so that anatomical integrity of facial nerve can be preserved.

In the present series, total excision of the tumor was possible in 83% cases, comparable to several published series.<sup>[1-3,5,16]</sup> Moon *et al.*<sup>[6]</sup> reported complete excision in all cystic VS. Following surgery in the present series facial nerve function at 6 months was satisfactory (HB grade 1-3) in only 21% of patients. This is in contrast to other series, in which satisfactory facial nerve function was seen in 60-80% of patients.<sup>[1-3]</sup> In patients with anatomical preservation of facial nerve, good outcome (HB grade 1-3) was seen in 34% of patients. The higher incidence of poor facial nerve function in the present study is probably due to large and giant tumors and an attempt at complete tumor removal. The use of intra-operative facial monitoring also is an extremely useful adjunct, especially in cystic VS. We had a much higher incidence of post-operative facial nerve palsy prior to facial monitoring. This has also contributed to an overall poor facial nerve preservation outcome. We believe that portions of the cyst wall firmly adherent to the nerve should be left behind rather than achieve total tumor removal. Based on post-operative imaging, residual tumors can be sent for radiotherapy. Now, the use of three-dimensional (3D) constructive interference in steady state (CISS) sequence in MRI can help preoperatively track to course of the facial nerve, thus increasing the prospects of nerve preservation.

Piccirillo *et al.*<sup>[1]</sup> concluded that in peripherally located, thin-walled anteriorly and medially placed cysts (Type B), subtotal resection is frequently advocated, leaving a portion of the cyst wall on the brainstem and facial nerve. Complete resection can often be achieved in purely posterior cysts and type A cysts.

Radiosurgery is not the ideal treatment modality in cystic VS due to large tumor size and cystic contents.<sup>[12,25,32]</sup> Radiosurgery

usually results in sustained expansion, causing cyst rupture, sustained regression, or transient expansion followed by sustained regression or no change.<sup>[32,33]</sup> Cystic VS that has regressed after radiosurgery is still at risk for expansion, which needs close monitoring even years after radiosurgery.<sup>[34,35]</sup> Surgery after failed radiation therapy is more difficult to perform because intense scarring and fibrosis obscures surgical planes, resulting in an indistinct facial nerve-tumor capsule interface and poor facial nerve outcome.<sup>[36]</sup> Recently, image-guided insertion of a valveless cystoperitoneal shunt as a palliative procedure in elderly patients who are at high risk for traditional surgical approaches has been described.<sup>[37]</sup> Though cystic VS have low proliferative index, residual cystic VS show rapid re-growth and require re-operation as compared to residual solid VS that have slow growth potential.<sup>[28]</sup> Recurrent cystic VS are even more surgically challenging, as they are associated with small chance of complete tumor removal and facial nerve preservation.

## Conclusion

Cystic VS are a heterogenous group of VS presenting with short duration and rapid progression of symptoms with frequent facial nerve involvement due to sudden expansion of the cystic elements. Particular attention should be given to preservation of facial nerve though it may be technically difficult. Resection of cystic VS is complicated by peritumoral adhesions of the capsule to the nerve and large size of the tumor. Extensive manipulation of the nerve in order to dissect the tumor-nerve barrier results in worse facial nerve outcome and poor health-related quality of life. Facial nerve outcome is worse in type B cysts (peripheral located and thin-walled cyst) as compared to type A cysts (centrally located and thick-walled cyst). Subtotal excision may be ideal, especially in type B anterior and medially placed cysts, in order to preserve facial nerve integrity.

## References

1. Piccirillo E, Wiet MR, Flanagan S, Dispenza F, Giannuzzi A, Mancini F, *et al.* Cystic vestibular schwannoma: Classification, management and

- facial nerve outcomes. *Otol Neurotol* 2009;30:826-34.
2. Wandong S, Meng L, Xingang L, Yuguang L, Shugan Z, Lei W, et al. Cystic acoustic neuroma. *J Clin Neurosci* 2005;12:253-5.
  3. Sinha S, Sharma BS. Cystic acoustic neuromas: Surgical outcome in a series of 58 patients. *J Clin Neurosci* 2008;15:511-5.
  4. Benech F, Perez R, Fontanella MM, Morra B, Albera R, Ducati A. Cystic versus solid vestibular schwannomas: A series of 80 grade III–IV patients. *Neurosurg Rev* 2005;28:209-13.
  5. Kameyama S, Tanaka R, Kawaguchi T, Fukuda M, Oyanagi K. Cystic acoustic neurinomas: Studies of 14 cases. *Acta Neurochir (Wien)* 1996;138:695-9.
  6. Moon KS, Jung S, Seo SK, Jung TY, Kim IY, Ryu HH, et al. Cystic vestibular schwannomas: A possible role of matrix metalloproteinase-2 in cyst development and unfavorable surgical outcome. *J Neurosurg* 2007;106:866-71.
  7. Charabi S, Tos M, Thomsen J, Rygaard J, Fundova P, Charabi B. Cystic vestibular schwannoma—clinical and experimental studies. *Acta Otolaryngol Suppl* 2000;543:11-3.
  8. Jeng CM, Huang JS, Lee WY, Wang YC, Kung CH, Lau MK. Magnetic resonance imaging of acoustic schwannomas. *J Formos Med Assoc* 1995;94:487-93.
  9. Kendall B, Symon L. Investigation of patients presenting with cerebellopontine angle syndromes. *Neuroradiology* 1977;13:65-84.
  10. Robbins B, Marshall WH Jr. Computed tomography of acoustic neurinoma. *Radiology* 1978;128:367-70.
  11. Tali ET, Yuh WT, Nguyen HD, Feng G, Koci TM, Jinkins JR, et al. Cystic acoustic schwannomas: MR characteristics. *AJNR Am J Neuroradiol* 1993;14:1241-7.
  12. Unger F, Walch C, Haselberger K, Papaefthymiou G, Trummer M, Eustacchio S, et al. Radiosurgery of vestibular schwannomas: A minimally invasive alternative to microsurgery. *Acta Neurochir (Wien)* 1999;141:1281-5.
  13. Wallace CL, Fong TC, Auer RN. Cystic intracranial schwannoma. *Can Assoc Radiol J* 1993;44:453-9.
  14. Jones SE, Baguley DM, Moffat DA. Are facial nerve outcomes worse following surgery for cystic vestibular schwannoma? *Skull Base* 2007;17:281-4.
  15. Fundova P, Charabi S, Tos M, Thomsen J. Cystic vestibular schwannoma: Surgical outcome. *J Laryngol Otol* 2000;114:935-9.
  16. Mehrotra N, Behari S, Pal L, Banerji D, Sahu RN, Jain VK. Giant vestibular schwannomas: Focusing on the differences between the solid and the cystic variants. *Br J Neurosurg* 2008;22:550-6.
  17. Yokoh A, Kobayashi S, Tanaka Y, Gibo H, Sugita K. Preservation of cochlear nerve function in acoustic neurinoma surgery. *Acta Neurochir (Wien)* 1993;123:8-13.
  18. Charabi S, Klinken L, Mantoni M, Tos M, Thomsen J. Histology and neuro-imaging in cystic acoustic neuromas. *Acta Otolaryngol* 1993;113:519-23.
  19. Charabi S, Klinken L, Tos M, Thomsen J. Histopathology and growth pattern of cystic acoustic neuromas. *Laryngoscope* 1994;104 (11 Pt 1):1348-52.
  20. Charabi S, Mantoni M, Tos M, Thomsen J. Cystic vestibular schwannomas: Neuroimaging and growth rate. *J Laryngol Otol* 1994;108:375-9.
  21. Park CK, Kim DC, Park SH, Kim JE, Paek SH, Kim DG, et al. Microhemorrhage, a possible mechanism for cyst formation in vestibular schwannomas. *J Neurosurg* 2006;105:576-80.
  22. Muzumdar DP, Goel A, Pakhmode CK. Multicystic acoustic neurinoma: Report of two cases. *J Clin Neurosci* 2002;9:453-5.
  23. Asano K, Ebina K, Sekiya T, Suzuki S. Acoustic neurinomas with large cystic components: A clinical and pathological study of 3 cases. *No Shinkei Geka* 1995;23:1075-82.
  24. Charabi S, Tos M, Borgesen SE, Thomsen J. Cystic acoustic neuromas. Results of translabyrinthine surgery. *Arch Otolaryngol Head Neck Surg* 1994;120:1333-8.
  25. El-Bahy K, Ali AK, Al-Abyad AG. Cystic Vestibular Schwannoma: Operative Findings and Surgical Outcome. *Egyptian J Neurosurg* 2007;2:27-35.
  26. Charabi S. Acoustic neuroma/vestibular schwannoma *in vivo* and *in vitro* growth models. A clinical and experimental study. *Acta Otolaryngol Suppl* 1997;530:1-27.
  27. Samii M, Matthies C. Management of 1000 vestibular schwannomas (acoustic neuromas): Surgical management and results with an emphasis on complications and how to avoid them. *Neurosurgery* 1997;40:11-21.
  28. Hwang SK, Kim DG, Paek SH, Kim CY, Kim MK, Chi JG, et al. Aggressive vestibular schwannomas with postoperative rapid growth: Clinicopathological analysis of 15 cases. *Neurosurgery* 2002;51:1381-90.
  29. Matthies C, Samii M, Krebs S. Management of vestibular schwannomas (acoustic neuromas): Radiological features in 202 cases – their value for diagnosis and their predictive importance. *Neurosurgery* 1997;40:469-81.
  30. Samii M, Matthies C. Management of 1000 vestibular schwannomas (acoustic neuromas): The facial nerve preservation and restitution of function. *Neurosurgery* 1997;40:684-94.
  31. Yaşargil MG, Fox JL. The microsurgical approach to acoustic neurinomas. *Surg Neurol* 1974;2:393-8.
  32. Pendl G, Ganz JC, Kitz K, Eustacchio S. Acoustic neurinomas with macrocysts treated with Gamma Knife radiosurgery. *Stereotact Funct Neurosurg* 1996;66:103-11.
  33. De Ipolyi A, Yang I, Buckley A, Barbaro NM, Cheung SW, Parsa AT. Fluctuating response of a cystic vestibular schwannoma to radiosurgery: Case report. *Neurosurgery* 2008;62:E1164-5.
  34. Yamakami I, Uchino Y, Kobayashi E, Yamaura A, Oka N. Removal of large acoustic neurinomas (vestibular schwannomas) by the retrosigmoid approach with no mortality and minimal morbidity. *J Neurol Neurosurg Psychiatry* 2004;75:453-8.
  35. Yasargil MG. A legacy of microneurosurgery: Memoirs, lessons, and axioms. *Neurosurgery* 1999;45:1025-92.
  36. Bennett M, Haynes DS. Surgical approaches and complications in the removal of vestibular schwannomas. *Otolaryngol Clin North Am* 2007;40:589-609.
  37. Barrett C, Prasad KS, Hill J, Johnson I, Heaton JM, Crossman JE, et al. Image-guided drainage of cystic vestibular schwannomata. *Acta Neurochir (Wien)* 2010;152:177-80.

**How to cite this article:** Nair S, Baldawa SS, Gopalakrishnan CV, Menon G, Vikas V, Sudhir JB. Surgical outcome in cystic vestibular schwannomas. *Asian J Neurosurg* 2016;11:219-25.

**Source of Support:** Nil, **Conflict of Interest:** None declared.