

Evaluation of Toluidine Blue-Mediated Photodynamic Therapy for Experimental Bacterial Keratitis in Rabbits

Guanyu Su¹, Zhenyu Wei¹, Leying Wang¹, Jing Shen^{1,2}, Christophe Baudouin^{3,4}, Antoine Labbé^{1,3,4}, and Qingfeng Liang¹

¹ Beijing Institute of Ophthalmology, Beijing Tongren Eye Center, Beijing Tongren Hospital, Capital Medical University, Beijing Ophthalmology & Visual Sciences Key Laboratory, Beijing, China

² National Engineering Research Center for Ophthalmology, Beijing, China

³ Quinze-Vingts National Ophthalmology Hospital, IHU FOReSIGHT, Paris and Versailles Saint-Quentin-en-Yvelines University, Versailles, France

⁴ INSERM, U968, Paris, F-75012, France; UPMC Univ Paris 06, UMR_S 968, Institut de la Vision, Paris F-75012, France; CNRS, UMR_7210, Paris, France

Correspondence: Qingfeng Liang, Beijing Institute of Ophthalmology, Beijing Tongren Eye Center, Beijing Tongren Hospital, Capital Medical University, Beijing Key Laboratory of Ophthalmology and Visual Sciences, Beijing 100005, China. e-mail: qingfengliang@ccmu.edu.cn

Received: June 5, 2019

Accepted: November 29, 2019

Published: February 12, 2020

Keywords: red light; toluidine blue O (TBO); photodynamic therapy; bacterial keratitis; rabbit

Citation: Su G, Wei Z, Wang L, Shen J, Baudouin C, Labbé A, Liang Q. Evaluation of toluidine blue-mediated photodynamic therapy for experimental bacterial keratitis in rabbits. *Trans Vis Sci Tech.* 2020;9(3):13, <https://doi.org/10.1167/tvst.9.3.13>

Objective: The objective of this study was to evaluate the effect of toluidine blue-mediated photodynamic therapy on experimental bacterial keratitis in rabbits.

Methods: Bacterial keratitis was induced in rabbits by the injection of 200 μ l *Staphylococcus aureus* (*S. aureus*) solution into the anterior stroma of the right cornea. Rabbits were randomly divided into four groups: toluidine blue O and red light (TBOR), levofloxacin eye drops (LEV), the combination of TBOR and LEV (TBOR + LEV), and a control group. Clinical manifestations, histopathology, and transmission electron microscopy were analyzed at various time points.

Results: Conjunctival injection and surface area of the corneal ulcer in the TBOR group and the TBOR + LEV group showed significant improvement from baseline after 7 days of treatment. Compared to baseline, the depth of corneal infiltration was decreased at day 14 in the TBOR and TBOR + LEV groups. Microscopic analysis of the TBOR and TBOR + LEV groups showed that the structure of each layer was intact, and there were no inflammatory cells in the corneal stroma. Additionally, IL-1 β and TNF- α were highly expressed in the LEV and control groups but were lower in the TBOR and TBOR + LEV groups. Under transmission electron microscopy, the corneas in the TBOR and TBOR + LEV groups were intact, whereas in the LEV and control groups, double-walled structures corresponding to *S. aureus* were found in the superficial stromal layer.

Conclusions: TBOR demonstrated in vivo antibacterial efficacy against *S. aureus*.

Translational Relevance: This study found in vivo antibacterial efficacy of toluidine blue-mediated photodynamic therapy on rabbit experimental bacterial keratitis, thus providing an additional new option for clinical treatment of bacterial keratitis.

Introduction

In developing countries, infectious keratitis remains a significant corneal disease causing blindness, and bacteria are the second leading cause of infectious keratitis after viruses.¹ A cross-sectional study in northeastern China showed that bacterial keratitis caused 20% and 40% of corneal blindness in children and adults, respectively.² In the United States, approxi-

mately 71,000 new cases of bacterial keratitis occur every year; moreover, bacterial keratitis has become the most common complication of contact lens wear.^{3,4} Topical application of antibiotics is always the preferred treatment for bacterial keratitis. However, several bacterial species have developed resistance, such as methicillin-resistant *Staphylococcus aureus* (MRSA), which seriously weakens the effectiveness of antibiotics against bacterial keratitis.⁵ In addition, the increasingly complex mechanisms of bacterial

resistance, such as bacterial biofilm formation, present greater resistance to antibacterial agents and have been a serious threat to worldwide ocular health.⁶⁻⁹ Therefore, ophthalmologists continue to search for other effective adjuvant therapies for the management of bacterial keratitis.

Photodynamic therapy (PDT) is a process that combines photosensitizers and light irradiation to produce reactive oxygen species (ROS) that will oxidize biological components and lead to target cell death.^{10,11} After its initial use for treatment of tumors, PDT has been shown to be effective for the elimination of microorganisms,¹¹ especially antibiotic-resistant microbial pathogens, such as MRSA, vancomycin-resistant *Enterococcus* species, and multidrug-resistant *Mycobacterium tuberculosis*.¹²⁻¹⁴ Toluidine blue O (TBO) is considered an effective membrane-destroying photosensitizing agent with good interaction with and high affinity for bacterial membranes in vitro.¹⁵ Its antimicrobial effect has only been evaluated in vitro.^{15,16} Our group has already demonstrated in vitro that toluidine blue-mediated photodynamic therapy can effectively inhibit bacterial growth.¹⁷ In this study, we assessed the bactericidal and therapeutic effect of TBO combined with 630-nm PDT on bacterial keratitis in rabbits.

Methods

Preparation of Bacterial Solution

A laboratory strain of *S. aureus* (BIO 5039) was selected for this study. It was isolated from a patient with bacterial keratitis provided by the department of microbiology, Beijing Institute of Ophthalmology, Beijing Tongren Hospital. The bacterial strain, stored in a glycerol tube, was revived and inoculated onto blood agar (Jinzhang Technique Development Co., Tianjin, China) at 36.5°C for 48 hours; bacterial colonies were then scraped with an inoculation loop, and 0.5 McFarland *S. aureus* solution (concentration: 1.5×10^8 colony forming unit, CFU/mL) was prepared.

Animal Model of Bacterial Keratitis

All procedures involving animals were carried out in accordance with standards established by the Association for the Research in Vision and Ophthalmology. Our study protocol was approved by the Animal Care and Use Committee, Capital Medical University (AEEI-2017-081). The protocol adhered to the policy and guidelines regarding the care and use of research animals. Fifty-six healthy adult New Zealand white

rabbits (both genders, aged 3–4 months, weight 2.5–3.0 kg) were provided by the Beijing Longan Animal Research Center (License NO. SCXK Beijing 2-14-0003). The right eye of each animal was selected for the experimental keratitis. They were treated preoperatively with levofloxacin eye drops (0.5%; Santen, Osaka, Japan) three times a day for 3 days in order to prevent unintentional infection with other bacteria.

During the experimental procedure, 10% chloral hydrate (2 mL/kg) was injected intravenously for general anesthesia, and proparacaine hydrochloride (0.5%) was instilled in the right eye three times for local anesthesia. An 8.5-mm corneal trephine was used to make a mark at a depth of one-third corneal thickness in the temporal region. Subsequently, 200 μ L of *S. aureus* solution (1.5×10^8 CFU/mL) was injected into the corneal stroma layer through the temporal incision with a 1 mL insulin syringe (Kindly Group, Shanghai, China). After diffusion of the bacterial fluid, interlamellar edema 3 to 4 mm in diameter was observed, and ofloxacin ophthalmic gel (SINQI, Shen Yang, China) was applied to the eye. No anti-inflammatory eye drops were administered after the surgery for any group.

From the first postoperative day, the ocular surface was examined daily for conjunctival injection, conjunctival discharge, corneal infiltration, ulcer, angiogenesis, and anterior chamber status. On the third postoperative day, 48 rabbits met the following inclusion criteria: (1) conjunctival injection and secretions, (2) corneal infiltration or ulcer, and (3) bacterial culture or smears of corneal lesions showing *S. aureus* infection. The success rate of experimental infection was 85.71% (48/56). This time point was defined as baseline (day 0).

Treatment Groups

At baseline, 48 rabbits with bacterial keratitis were randomized into four groups (12 rabbits in each group): group 1, treatment with toluidine blue O and red light (TBOR group); group 2, treatment with levofloxacin eye drops (LEV group); group 3, treatment with PDT and levofloxacin eye drops (TBOR + LEV group); and group 4, no treatment (control group). At baseline, we conducted a quantitative evaluation of rabbit keratitis in each group, including conjunctival injection, measurement of corneal ulcers, grading of neovascularization, and evaluation of depth of infiltration. There was no significant difference among the various groups for these parameters at baseline (Appendix Table 1).

TBOR group: On the first and seventh days after baseline, 12 rabbits with bacterial keratitis were treated with PDT (Fig. 1) with the following protocol under general anesthesia: 0.2 mL toluidine blue O solution

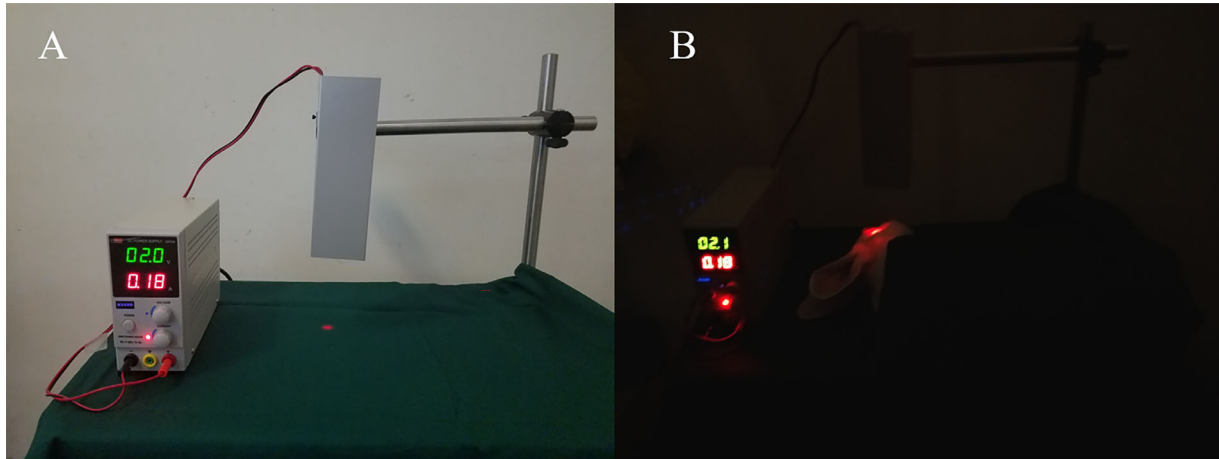


Figure 1. (A) Red light treatment equipment; (B) rabbit undergoing toluidine blue O and red light (TBOR) therapy.

(1 mM, Beijing Solarbio Science & Technology Co., Ltd., Beijing, China) was applied to the lesion area of bacterial keratitis 5 times over 10 minutes. Subsequently, the corneal lesions were irradiated with a red light source (MCH-K305D, MCH Instruments Co., Ltd., Shenzhen, China) for 30 minutes (wavelength, 630 nm; irradiance, 87.8 mW/cm²).

LEV group: During the first week after baseline, levofloxacin eye drops were instilled at the rate of one drop every 2 hours during the day, and ofloxacin ophthalmic ointment (0.3%; Xingqi, Shenyang, China) was applied at night. During the second week, the frequency of levofloxacin eye drop instillation was decreased to three times a day, and ofloxacin ophthalmic ointment once at night. This treatment was continued for 4 weeks.

TBOR + LEV group: Twelve rabbits with bacterial keratitis were treated with the PDT method (same protocol as the TBOR group) and levofloxacin eye drops (same protocol as the LEV group).

Control group: No treatment was administered after successful development of infectious keratitis.

Postintervention Examination

Treatment efficacy in each group was evaluated by clinical manifestations and histopathological examinations at days 3, 7, 14, and 28 after baseline.

The parameters of clinical manifestations were as follows: (1) conjunctival injection was evaluated with the slit lamp microscope (0–3 points),¹⁸ no obvious injection (0 point); mild injection, with no conjunctival chemosis (1 point); obvious injection, accompanied by conjunctival chemosis (2 points); severe injection with tortuosity of all conjunctival vessels, accompanied by conjunctival chemosis and ciliary

flush (3 points). (2) The surface area of the corneal epithelial defect was evaluated with the slit-lamp biomicroscope after corneal staining with 2% sodium fluorescein (Feiya Technique Co., Jiangsu, China). The area was measured with ImageJ software (<http://imagej.nih.gov/ij/>, National Institutes of Health [NIH], Bethesda, MD, USA).¹⁹ (3) Corneal neovascularization was graded as 0–3 points,¹⁸ no obvious neovascularization (0 points); neovascularization occupying 1 or 2 quadrants (1 point or 2 points); neovascularization occupying 3 or 4 quadrants or covering the entire corneal surface (3 points). (4) Inflammatory infiltration of the experimental models was evaluated by anterior segment OCT examination (Optovue Inc., Fremont, CA, USA) for each group prior to and 14 days after treatment. The maximum depth of infiltration was measured with ImageJ software.

Histopathological evaluations included corneal histopathology, immunohistochemistry, and transmission electron microscopy (TEM). Three rabbits from each group were euthanized at days 3, 7, 14, and 28 after treatment. Rabbits were euthanized with an intravenous overdose injection of 5% pentobarbital (1 mg/kg). The corneal lesions were excised along the limbus and divided into two portions. One portion was used for histopathological and immunohistochemical examination to observe changes in the types and number of inflammatory cells. Immunohistochemical staining consisted of IL-1 β (Abcam #ab8320), TNF- α (Abcam #ab1793), and TIMP1 (Abcam #16644-1-AP). Cells with positive expression were counted in each group. The other portion was sent for TEM examination. Corneal specimens were divided into small fragments and fixed in 4% cacodylate buffered glutaraldehyde (pH = 7.4) at room temperature. Under a light microscope, semi-thin sections (2- μ m

Table. Comparison of Conjunctival Injection at Each Time Point Across the Groups (Mean \pm Standard Deviation)

Group	Before Treatment	After Treatment			
		3 Days	7 Days	14 Days	28 Days
TBOR*#	3.18 \pm 0.75	2 \pm 0.45 ($<$ 0.001)	1.33 \pm 0.71 ($<$ 0.001)	0.83 \pm 0.75 ($<$ 0.001)	0.67 \pm 0.58 ($<$ 0.001)
LEV	3.27 \pm 0.79	3 \pm 0.77 (0.14)	2.88 \pm 0.64 (0.06)	1.8 \pm 0.84 ($<$ 0.001)	1.00 \pm 0.00 ($<$ 0.001)
TBOR + LEV*#	3.27 \pm 0.65	2.09 \pm 0.54 ($<$ 0.0001)	1.33 \pm 0.87 ($<$ 0.001)	0.83 \pm 0.75 ($<$ 0.001)	0.67 \pm 0.58 ($<$ 0.001)
Control	3.09 \pm 0.7	3.36 \pm 0.81 (0.29)	3.22 \pm 0.83 (0.55)	3.6 \pm 0.55 (0.05)	3.33 \pm 0.58 (0.29)

LEV, levofloxacin; TBOR, toluidine blue O and red light.

Data were expressed as the means \pm standard deviation, with the probabilities in parentheses. Probabilities show the comparison of each dose group with pretreatment values. Due to multiple comparisons, the inspection level was corrected to 0.0125.

*Statistically significant difference from the control group,

#Statistically significant difference from the LEV group.

thick) were reviewed, and selected areas were obtained. Ultrathin sections were examined and photographed under TEM (JEM-1400; JEOL, Japan). The ultrastructural characteristics of these corneal stromal cells, the collagen matrix, and the intercellular junctions were analyzed.

Statistical Analysis

The mean \pm standard deviation was used to describe the measurement data. Median and interquartile distance were used to describe the counting data statistically. The normality of the data was analyzed using the Shapiro–Wilk test. The normal data were compared before and after treatment with the paired *t*-test, and the non-normal data were used for the paired rank-sum test. When multiple comparisons were involved, Bonferroni correction was included in the test. The generalized estimation equation was used to compare the repeated measurement data at each time point and within each treatment group. Any $P < 0.05$ was considered statistically significant. SAS software version 9.4 (Cary, NC, USA) was used for statistical analysis.

Results

Clinical manifestations of bacterial keratitis were observed in 48 rabbits after 3 days of intrastromal injection of *S. aureus*, including conjunctival injection, a large number of yellow mucopurulent secretions in the conjunctival cul-de-sac, corneal ulcer, abscess,

infiltration, and opacity. After treatment with TBOR, LEV, and the combination treatment (TBOR + LEV), these clinical signs began to improve (Fig. 2).

On the third and seventh days of treatment, conjunctival injection was significantly improved in the TBOR and the TBOR + LEV groups, as compared to baseline data (all $P < 0.001$). Conjunctival injection in the LEV group was not statistically significantly improved until the 14th day of treatment (Table). Compared to the control group, conjunctival injection was significantly alleviated in the TBOR group and the TBOR + LEV group 14 days after treatment ($Z = -6.37, -5.29$; both $P < 0.001$) (Appendix Table 2). Moreover, a significant difference was observed in comparison to the LEV group ($Z = 3.62, 2.96$; $P = 0.0003, 0.0031$, Appendix Table 2). Between the TBOR group and the TBOR + LEV group, there was no significant difference in conjunctival injection at day 14 ($Z = 0.24, P = 0.813$, Appendix Table 2).

The size of the corneal ulcer began to decrease after 3 days of treatment in the TBOR group and TBOR + LEV group. Compared to baseline, there was a significant reduction of ulcer size at day 7 and day 14 of treatment in these two groups (all $P < 0.001$; Appendix Table 3 and Fig. 2), and no significant difference in the LEV group ($P = 0.610$). Comparing the TBOR group and TBOR + LEV group, the ulcer size was remarkably decreased in the TBOR + LEV group compared to the TBOR group at day 7 ($0.08 \pm 0.07 \text{ cm}^2$ vs. $0.28 \pm 0.32 \text{ cm}^2$), and day 14 ($0.06 \pm 0.08 \text{ cm}^2$ vs. $0.14 \pm 0.19 \text{ cm}^2$), although the difference between the two groups was not statistically significant

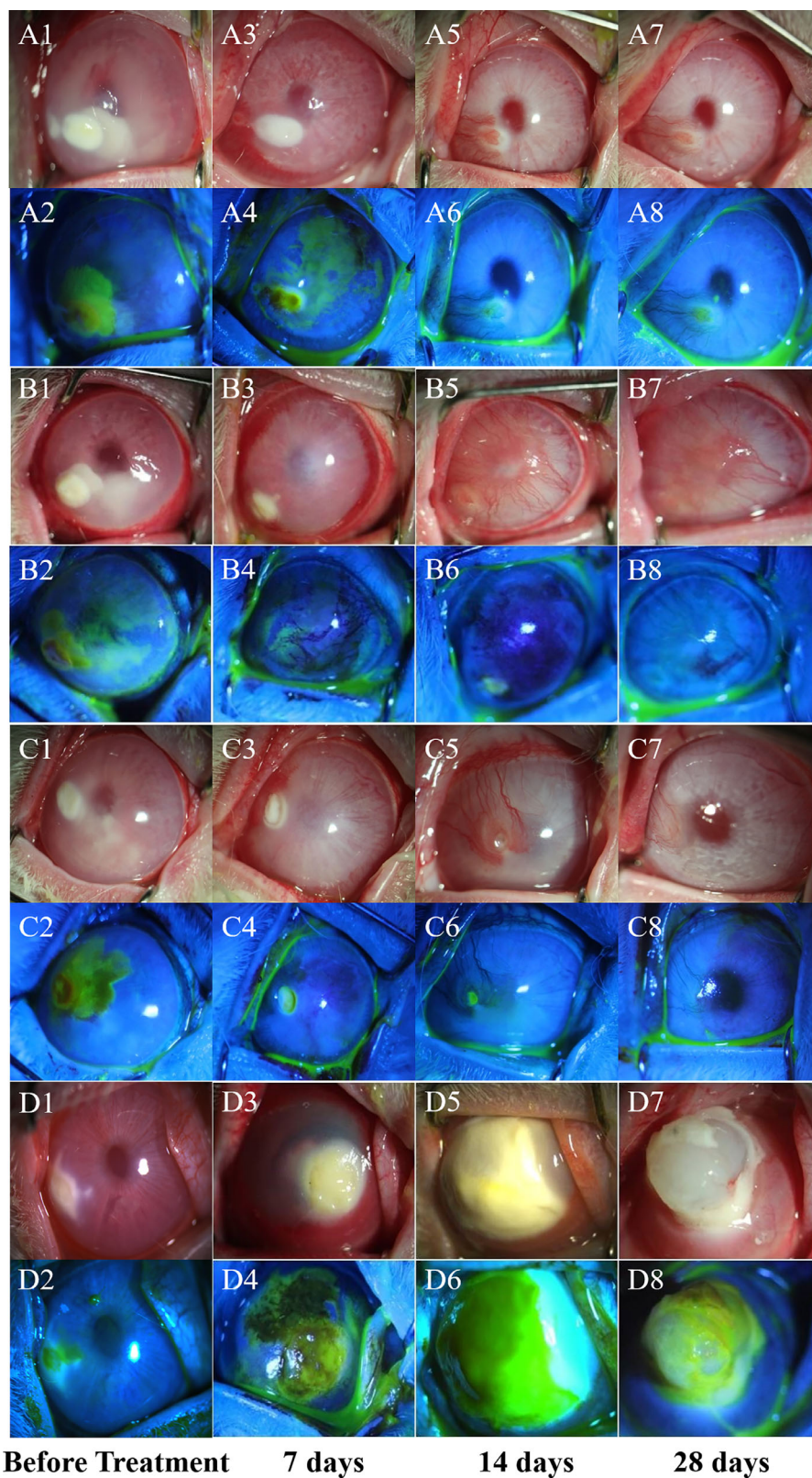


Figure 2. External eye images and epifluorescence photograph of each group before treatment and 7, 14, and 28 days after treatment (A: toluidine blue O and red light (TBOR) group; B: levofloxacin (LEV) group; C: combination toluidine blue O and red and levofloxacin light therapy (TBOR + LEV) group; D: Control group).

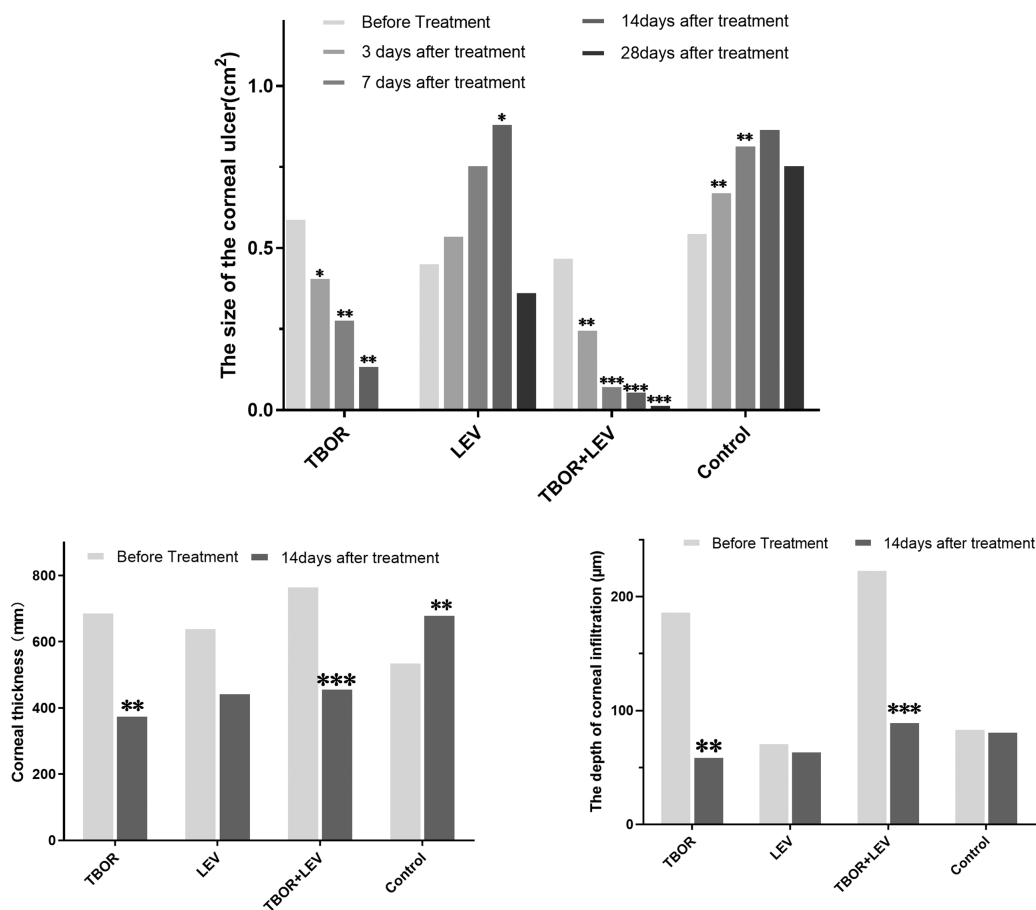


Figure 3. Area of corneal edema, depth of infiltration of the corneal ulcer, and area of the corneal ulcer at various time points. *Statistically significant difference from the control group prior to treatment.

($Z = 0.514$, $P = 0.607$, $Z = -1.20$, $P = 0.230$; Appendix Tables 2 and 3).

The reactive corneal neovascularization increased in each experimental group on the third day after treatment. Following the various interventions, neovascularization in the TBOR and TBOR + LEV groups began to decrease at day 7. The neovascularization score in the TBOR + LEV group was 1 (0–1), and slightly less than the score in the TBOR group 1 (1–1) (Appendix Table 4). At day 14, it had disappeared, and no statistically significant difference was found relative to baseline. However, corneal neovascularization in the LEV group and control group were both aggravated relative to baseline (both $P < 0.0001$; Appendix Table 4). There was a statistically significant difference in neovascularization among the treatment groups (TBOR, LEV, and TBOR + LEV) and the control group ($Z = -5.12$, -3.47 , -6.27 ; all $P < 0.001$; Appendix Table 2). There was no statistically significant difference between the TBOR group and the TBOR + LEV group at day 14 ($Z =$

0.66 , $P = 0.507$; Appendix Table 2). Compared to baseline, the depth of corneal infiltration (Appendix Table 5) on OCT examination had decreased at day 14 after the TBOR and TBOR + LEV treatments ($P = 0.002$, $P < 0.001$).

After intrastromal injection of *S. aureus*, pathologic findings of bacterial keratitis showed epithelial defects, stromal edema, infiltration of a large number of inflammatory cells, and disorganization of collagen fibrils. With TBOR or TBOR + LEV treatment, neutrophils in the stromal layer gradually decreased, and the stromal fibers recovered an ordered appearance. As seen in Figures 4A1 and 4C1, no obvious inflammatory cells were found in the TBOR and TBOR + LEV groups at day 14 after treatment. The corneal epithelium was intact, and the stromal fiber layers were normal. However, the cornea in the LEV and control groups showed a large number of inflammatory cells in the stroma, defective epithelial keratinization, and persistent corneal edema at day 14 (Fig. 3).

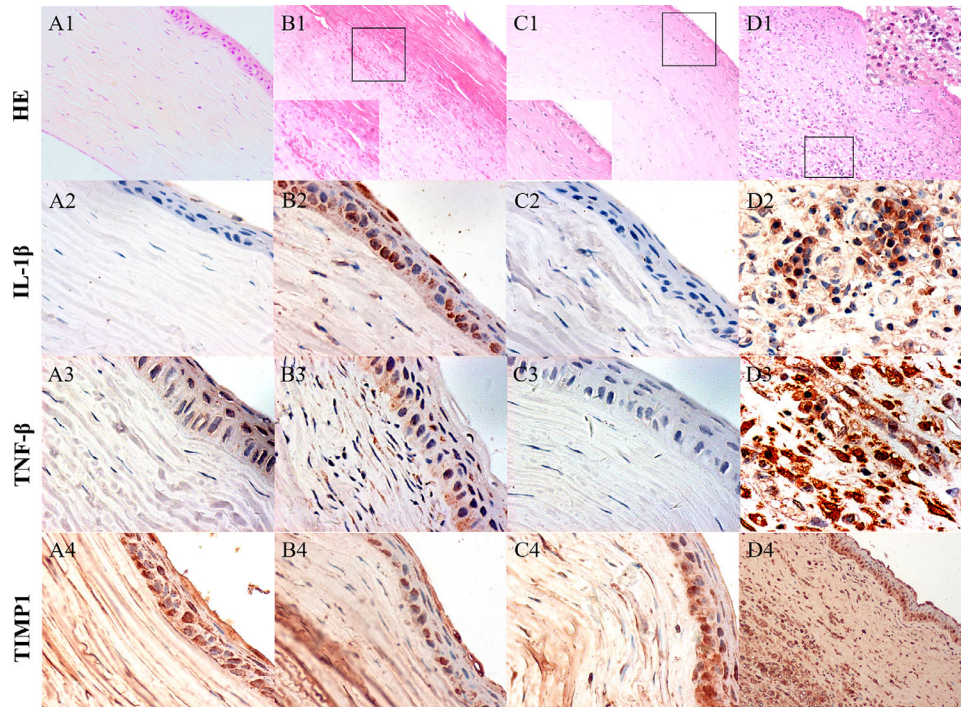


Figure 4. Histopathologic photographs and immunohistochemical photomicrographs of rabbit corneas at day 14 after treatment (A: toluidine blue O and red light (TBOR) group; B: levofloxacin (LEV) group; C: combination toluidine blue O and red and levofloxacin light therapy (TBOR + LEV) group; D: Control group, hematoxylin-eosin staining (HE) \times 400, immunohistochemical (IHC) \times 400). A1 and C1 show that the structure of the cornea is basically restored to normal, the fibrous stromal layer is neatly arranged, the corneal epithelium is intact, and its three layers are clearly visible; B1 shows that the corneal epithelium is absent, and the collagen fibers in the shallow stromal layer are loosely arranged; D1 shows a large number of inflammatory cells (neutrophils), and blood cells can be seen in the subepithelial stroma, D1 shows rupture of the epithelial layer, thickening of the cornea, diffuse inflammatory cells (neutrophils), and a large number of newly formed blood vessels in the subepithelial and stromal layers. IL-1 β and TNF- β are highly expressed in the corneas of the LEV and control groups, but low expression is seen in the TBOR and TBOR + LEV groups. TIMP1 exhibits high expression in all groups.

Immunohistochemical staining showed that IL-1 β and TNF- α were highly expressed in the corneas of the LEV and control groups, but limited expression was observed in the TBOR and TBOR + LEV groups after 14 days. High expression of TIMP1 was noted in all groups at that time point (Fig. 4).

Under TEM, the corneal epithelial cells in the TBOR and TBOR + LEV groups in the infected area were intact at 14 days. Intact, clear corneal epithelium was observed in the TBOR group (Fig. 5A1). The cellular structure was visible, and the stromal fibers were arranged regularly (Fig. 5A2). In the control group, corneal epithelium was missing or edematous, stromal fibers were disordered, and a small number of coccus-like structures could be detected (Fig. 5B1). The control group showed a large number of double-walled structures corresponding to *S. aureus* (Fig. 5B2), and few, but altered, corneal epithelial cells were observed at day 14.

Discussion

Antibacterial photodynamic therapy is a process using a photosensitizer and various light wavelengths to produce cytotoxic ROS and a bactericidal effect.²⁰ Halili et al.²¹ found that Rose Bengal-mediated green light (518 nm) could effectively kill MRSA in vitro when combined with a Bengal red photosensitizer. It has also been reported that blue light at 470 nm can effectively control a MRSA strain.²² Nielsen et al.²³ showed that the in vitro bactericidal effect of TBOR was stronger than that of blue light combined with the same concentration of riboflavin. In the present in vivo study, we were able to demonstrate the bactericidal and therapeutic effect of TBOR on a rabbit model of bacterial keratitis. Compared to the use of antibiotics (LEV), TBOR treatment was more effective in terms of promoting ulcer healing, reducing

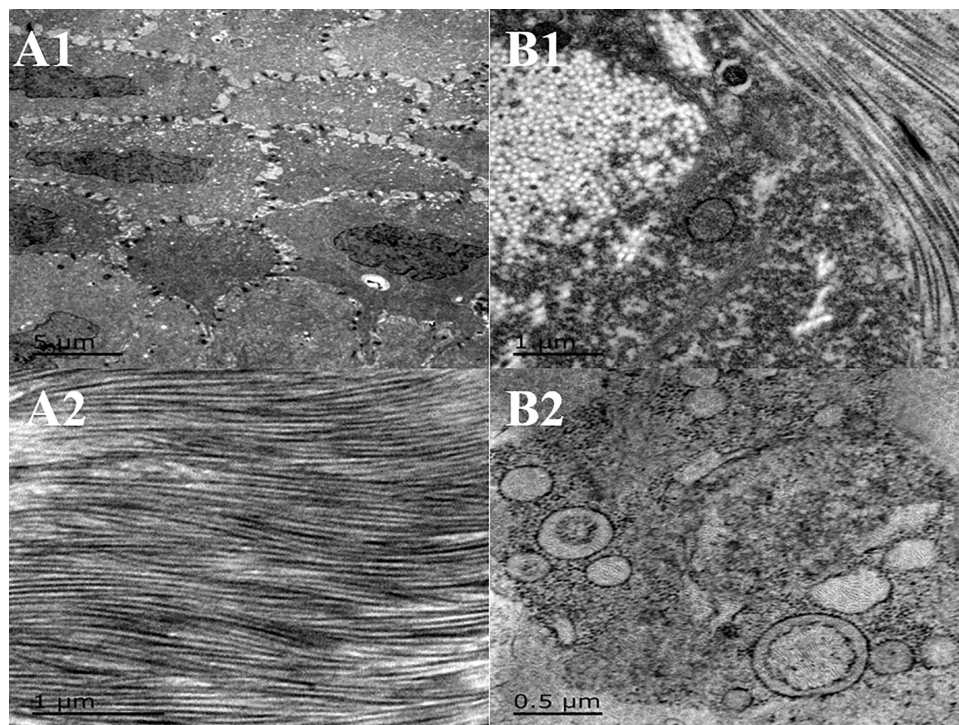


Figure 5. Transmission electron microscopy (TEM) images of rabbit keratitis after 14 days of treatment (A: toluidine blue O and red light (TBOR) group; B: Control group). A1 shows the epithelial structure in the area of the ulcer ($\times 4,000$); A2 the superficial stromal layer, longitudinal direction of collagen fibers ($\times 30,000$); B1 shows longitudinal section and cross section of collagen fibers in the superficial stromal layer. Some collagen fibers show partial depolymerization and denaturation, and are surrounded by round bacteria-like structures ($\times 20,000$); B2 shows many double-walled *S. aureus*-like structures ($\times 40,000$).

neovascularization, and limiting scar formation. The inactivation of bacteria with TBOR treatment depends on the production of ROS, especially singlet oxygen (1O_2), after the interaction between the light and the photosensitizer. Meanwhile, TBOR could effectively inhibit bacterial adhesion, biofilm formation, and bacterial growth.^{16,20,24} Li et al.²⁵ studied the bactericidal effect in vitro of red light of various energies combined with toluidine blue O on *S. epidermis* and found that PDT worked by altering bacterial biofilm formation. Destruction of the bacterial environment through these photodynamic methods might inhibit bacterial growth.

PDT can also promote wound healing. In our study, the size of the corneal ulcer began to decrease after 3 days of TBOR or TBOR + LEV treatment. Several studies have revealed that the photochemical response to PDT can induce the release of these molecules (IL-1, MMPs, and so on)^{26,27} in the corneal stroma and strengthen the rigidity in the anterior corneal stroma. In addition, PDT was described as a way to increase collagen fiber thickness, enhance resistance to stretching and enzymatic degradation, and decrease corneal edema and permeability.²⁸⁻³⁰ PDT may not

only inhibit bacterial growth, but may also contribute to the change in the stromal micro-environment; thus PDT might protect the tissue from bacterial infection or limit bacterial growth. From our results, the combination treatment (TBOR + LEV) was more effective than the individual treatments (TBOR or LEV alone), although the difference in ulcer size and neovascularization scores were not significant. Girollo et al.³¹ demonstrated that PDT with methylene blue could increase membrane permeability in *C. albicans*, which could decrease the resistance of this microorganism to other drugs. Interestingly, PDT could also act as a coadjuvant to conventional antimicrobial drug therapy by improving the antibacterial effects of antibiotics in bacterial keratitis. Yoon et al.³² revealed that PDT generated oxygen free radicals from the interaction of light, oxygen, and the photosensitizer in animal models, which induced damage and thrombus formation, resulting in occlusion of corneal blood vessels. This is in accordance with the results of TBOR, which also show inhibition of corneal neovascularization induced by bacterial keratitis.

These clinical results were also confirmed by histological and immunohistochemical examination. The

corneal epithelial cells were clearly visible in the TBOR and TBOR + LEV groups by day 14, and there were few inflammatory cells in the stromal layer, whereas corneal thickening, epithelial defects, neovascularization, and a large number of inflammatory cells were observed in the LEV and control groups. The inflammatory mediators, IL-1 β and TNF- α , were highly expressed in the LEV and control groups but showed low expression in the TBOR and TBOR + LEV groups, indicating that the corneas in the LEV and control groups were still in a severe inflammatory phase. On TEM examination, the structure of the corneal epithelial cells and stromal fibers began to normalize after 14 days of treatment with TBOR and TBOR + LEV. On the contrary, the epithelial cells in the LEV group and control group were edematous, and the collagen fiber architecture was irregular. In some severe cases, *S. aureus* could be detected. From these results, we found that PDT could shorten the course of bacterial keratitis, and TBOR treatment had a significant effect on rabbit bacterial keratitis from the second week after intervention. Therefore, PDT may be a promising adjuvant therapy for bacterial keratitis.

Thus, with the above analysis of our results, it may be concluded that TBOR might be a supplementary treatment to traditional antibiotics in bacterial keratitis. These results are consistent with the results of Sharma et al.,¹⁶ which demonstrated that TBO combined with red light at 640 nm can effectively kill *S. aureus* and *S. epidermidis*. However, the side effects of red light on other ocular structures, such as the lens or retina, should be studied further. Therefore, further studies on PDT may provide a new therapeutic paradigm for bacterial keratitis.

Acknowledgments

Supported by National Nature Science Foundation of China (Grant No. 81470607).

Disclosure: **G. Su**, None; **Z. Wei**, None; **L. Wang**, None; **J. Shen**, None; **C. Baudouin**, None; **A. Labbé**, None; **Q. Liang**, None

References

1. Song X, Xie L, Tan X, et al. A multi-center, cross-sectional study on the burden of infectious keratitis in China. *PLoS One*. 2014;9:e113843.
2. Wang H, Zhang Y, Li Z, Wang T, Liu P. Prevalence and causes of corneal blindness. *Aust N Z J Ophthalmol*. 2014;42:249–253.
3. Jeng BH, Gritz DC, Kumar AB, et al. Epidemiology of ulcerative keratitis in Northern California. *Arch Ophthalmol*. 2010;128:1022–1028.
4. Collier SA, Gronostaj MP, MacGurn AK, et al. Estimated burden of keratitis—United States, 2010. *MMWR Morb Mortal Wkly Rep*. 2014;63:1027–1030.
5. Haas W, Pillar CM, Torres M, Morris TW, Sahm DF. Monitoring antibiotic resistance in ocular microorganisms: results from the antibiotic resistance monitoring in ocular microorganisms (ARMOR) 2009 surveillance study. *Am J Ophthalmol*. 2011;152:567–574.e563.
6. The antibiotic alarm. *Nature News*. 2013;495.
7. Eurosurveillance Editorial Team. WHO member states adopt global action plan on antimicrobial resistance. *Euro Surveill*. 2015;20:pil: 21137.
8. Jee Y, Carlson J, Rafai E, et al. Antimicrobial resistance: a threat to global health. *Lancet Infect Dis*. 2018;18:939–940.
9. Ray KJ, Prajna L, Srinivasan M, et al. Fluoroquinolone treatment and susceptibility of isolates from bacterial keratitis. *JAMA Ophthalmol*. 2013;131:310–313.
10. Buytaert E, Dewaele M, Agostinis P. Molecular effectors of multiple cell death pathways initiated by photodynamic therapy. *Biochim Biophys Acta Rev Cancer*. 2007;1776:86–107.
11. Wainwright M. Photodynamic antimicrobial chemotherapy (PACT). *J Antimicrob Chemother*. 1998;42:13–28.
12. Wainwright M, Phoenix DA, Gaskell M, Marshall B. Photobactericidal activity of methylene blue derivatives against vancomycin-resistant *Enterococcus* spp. *J Antimicrob Chemother*. 1999;44:823–825.
13. Wainwright M, Phoenix DA, Laycock SL, Wareing DR, Wright PA. Photobactericidal activity of phenothiazinium dyes against methicillin-resistant strains of *Staphylococcus aureus*. *FEMS Microbiol Lett*. 2010;160:177–181.
14. Leonard A, Marta M, Miguel V. Enhanced killing of intracellular multidrug-resistant mycobacterium tuberculosis by compounds that affect the activity of efflux pumps. *J Antimicrob Chemother*. 2007;59:1237–1246.
15. Bhatti M, MacRobert A, Henderson B, Wilson M. Exposure of *Porphyromonas gingivalis* to red light in the presence of the light-activated antimicrobial agent toluidine blue decreases membrane fluidity. *Curr Microbiol*. 2002;45:118–122.
16. Sharma M, Visai L, Bragheri F, Cristiani I, Gupta PK, Speziale P. Toluidine blue-mediated

- photodynamic effects on staphylococcal biofilms. *Antimicrob Agents Chemother.* 2008;52:299–305.
17. Shen J, Liang Q, Su G, et al. In vitro effect of toluidine blue antimicrobial photodynamic chemotherapy on staphylococcus epidermidis and staphylococcus aureus isolated from ocular surface infection. *Transl Vis Sci Technol.* 2019;8:45.
 18. Murphy G. The regulation of connective tissue metalloproteinases by natural inhibitors. *Agents Actions Suppl.* 1991;35:69–76.
 19. Turkcu FM, Cinar Y, Turkcu G, et al. Topical and subconjunctival ranibizumab (lucentis) for corneal neovascularization in experimental rat model. *Cutan Ocul Toxicol.* 2014;33:138–144.
 20. Jori G. Photodynamic therapy of microbial infections: state of the art and perspectives. *J Environ Pathol Toxicol Oncol.* 2006;25:505–519.
 21. Halili F, Arboleda A, Durkee H, et al. Rose bengal- and riboflavin-mediated photodynamic therapy to inhibit methicillin-resistant Staphylococcus aureus keratitis isolates. *Am J Ophthalmol.* 2016;166:194–202.
 22. Enwemeka CS, Williams D, Enwemeka SK, Hollosi S, Yens D. Blue 470-nm light kills methicillin-resistant Staphylococcus aureus (MRSA) in vitro. *Photomed Laser Surg.* 2009;27:221–226.
 23. Nielsen HK, Garcia J, Vaeth M, Schlafer S. Comparison of riboflavin and toluidine blue o as photosensitizers for photoactivated disinfection on endodontic and periodontal pathogens in vitro. *PLoS One.* 2015;10:e0140720.
 24. Zanin IC, Lobo MM, Rodrigues LK, Pimenta LA, Hofling JF, Goncalves RB. Photosensitization of in vitro biofilms by toluidine blue O combined with a light-emitting diode. *Eur J Oral Sci.* 2006;114:64–69.
 25. Li X, Liu Z, Liu H, Chen X, Liu Y, Tan H. Photodynamic inactivation of fibroblasts and inhibition of Staphylococcus epidermidis adhesion and biofilm formation by toluidine blue O. *Mol Med Rep.* 2017;15:1816–1822.
 26. Berger EA, McClellan SA, Barrett RP, Hazlett LD. Testican-1 promotes resistance against Pseudomonas aeruginosa-induced keratitis through regulation of MMP-2 expression and activation. *Invest Ophthalmol Vis Sci* 2011;52:5339–5346.
 27. Carnt NA, Willcox MDP, Hau S, et al. Association of single nucleotide polymorphisms of interleukins-1 β , -6, and -12B with contact lens keratitis susceptibility and severity. *Ophthalmology.* 2012;119:1320–1327.
 28. Spoerl E, Wollensak G, Seiler T. Increased resistance of crosslinked cornea against enzymatic digestion. *Curr Eye Res.* 2004;29:35–40.
 29. Wollensak G, Spoerl E, Seiler T. Stress-strain measurements of human and porcine corneas after riboflavin-ultraviolet-A-induced cross-linking. *J Cataract Refract Surg.* 2003;29:1780–1785.
 30. Wollensak G, Wilsch M, Spoerl E, Seiler T. Collagen fiber diameter in the rabbit cornea after collagen crosslinking by riboflavin/UVA. *Cornea.* 2004;23:503–507.
 31. Giroldo LM, Felipe MP, de Oliveira MA, Munin E, Alves LP, Costa MS. Photodynamic antimicrobial chemotherapy (PACT) with methylene blue increases membrane permeability in Candida albicans. *Lasers Med Sci.* 2009;24:109–112.
 32. Kyung-Chul Y, Kyu Youn A, Eun LS, et al. Experimental inhibition of corneal neovascularization by photodynamic therapy with verteporfin. *Curr Eye Res.* 2006;31:215–224.