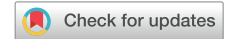

BRIEF REPORT

A novel approach to electrocardiography in the prone patient



José M. Sanchez, MD,* Morteza Farasat, MD,† Andrew E. Levy, MD,†
Ivor S. Douglas, MD,‡ Brian L. Stauffer, MD,† Wendy S. Tzou, MD, FHRS,*
J. Jason West, MD*

From the *Section of Cardiac Electrophysiology, Denver Health and Hospital Authority, University of Colorado School of Medicine, Denver, Colorado, †Division of Cardiology, Denver Health and Hospital Authority, University of Colorado School of Medicine, Denver, Colorado, and ‡Division of Pulmonary & Critical Care, Denver Health and Hospital Authority, University of Colorado School of Medicine, Denver, Colorado.

Prone ventilation has become a standard critical care tool for managing severe acute respiratory distress syndrome and requires face-down positioning for over 16 hours per day.¹ While cardiac injury and arrhythmias are common in critically ill patients, prone ventilation restricts access to the precordium and limits the utility of the standard electrocardiogram (ECG). We propose the prone ECG, and examine its correlation to the standard ECG.

Volunteers were recruited from within the staff at our institution. Standard and prone ECGs were performed and acquired using an FDA-approved ECG recording and electroanatomical mapping system (CARTO 3; Biosense Webster Inc, Diamond Bar, CA). Leads pV₁ and pV₂ were placed overlying the fourth intercostal space to the right and left of the spine, respectively. Lead pV₄ was placed in the fifth intercostal space on the left mid-scapular line. Leads pV₃ and pV₅ were positioned between pV₂-pV₄ and pV₄-pV₆, respectively (Figure). Lead pV₆ and the limb leads remained unchanged from the standard position. Using a morphology matching software contained within the CARTO system (PaSo; Biosense Webster Inc, Diamond Bar, CA), the degree of match between prone and standard QRS complexes was examined and a correlation score reported for each lead (Figure). The term “concordance” is used to describe a correlation score between 0 and +1, while “discordance” is used for a score between 0 and -1. The duration of the QT interval was also measured, and a correlation score for QT interval morphology was obtained. The Colorado Multiple Institutional Review Board approved the protocol, and written informed consent was obtained from all volunteers. The research reported in this paper adhered

to the guidelines from the Helsinki Declaration as revised in 2013.

Twenty participants were enrolled, with mean age of 39.8 ± 10.9 years, mean body mass index of 28 ± 5.9 kg/m², and male predominance (60%). Comparison of the prone QRS to that from a standard ECG yielded a correlation score of 0.59 ± 0.09 (Table). The QRS correlation was higher for the limb leads than precordial leads (0.89 ± 0.11 vs 0.30 ± 0.19, *P* < .05), and for the anterolateral (V₄-V₆) leads than anteroseptal (V₁-V₃) leads. When the anteroseptal leads were excluded, summative concordance increased to 0.88 ± 0.08. The morphology of the prone QT interval compared to the standard ECG was similarly higher in the limb leads than the precordial leads, as well as higher in the anterolateral than the anteroseptal leads. Concordance of the prone QT interval increased to 0.86 ± 0.08 after exclusion of the anteroseptal leads. Finally, there was no significant difference in the measured QT interval duration between prone and standard ECGs (378 ± 23 ms vs 379 ± 26 ms, *P* = NS).

Performing ECGs in critically ill patients, especially in the setting of prone ventilation and when regular assessments of the QT interval are needed, can be technically challenging and difficult to interpret. Furthermore, the effect of prone positioning on the electrocardiographic vectors may affect ECG interpretation. One of the initial descriptions of position- and respiration-related changes on the ECG was described in 1941.² Similar observations have since demonstrated position-associated changes in the QRS complex, ST segment, and T wave following a change from supine to upright posture as well as from the right or left lateral decubitus position.^{3,4} It is also important to note, however, that ECGs with nonstandard lead placement are routinely performed in clinical practice. A torso modified ECG provides helpful information in those where limb lead artifact is an issue.⁵ In addition, Fontaine leads have been studied and demonstrate increased detection of epsilon waves in those suspected for

KEYWORDS Critical care; ECG; Electrocardiography; Prone ventilation; Repolarization (Heart Rhythm 02 2021;2:107-109)

Address reprint requests and correspondence: Dr José M. Sanchez, 777 Bannock St, MC0960, Denver, CO 80209. E-mail address: jose.4.sanchez@cuanschutz.edu.

KEY FINDINGS

- Standard electrocardiograms (ECGs) are technically challenging to perform in prone-ventilated patients.
- Alternate placement of the precordial leads while in the prone position yields a high level of concordance when compared to the standard ECG.
- There is no difference in the measured QT interval while prone. This may provide an opportunity for detection of repolarization abnormalities in critically ill, prone-ventilated patients.

ARVC.^{6,7} Right-sided precordial and posterior leads have been validated as a useful tool for detection of ischemia and infarction.^{8,9} Importantly, nonstandard lead placement allows for assessment of specific myocardial regions that are otherwise not detected by the standard ECG. Consistent lead placement is critical and recommended for standardization and interpretation, and improper lead positioning and labeling can introduce errors in analysis and clinical decision-making.¹⁰

While this study offers insight into the relationship between prone and standard ECGs, it does have some limitations. The ECGs were obtained not using a standard ECG machine, but with an electroanatomic mapping system (CARTO) frequently used to obtain ECGs and guide electrophysiologic procedures in the electrophysiology lab. Despite this, the high-pass and low-pass filter settings used in this study (0.5 Hz and 120 Hz, respectively) were comparable to a standard ECG machine. The morphology matching software utilized in this study was designed and validated for comparison of the QRS complex. Even though the analysis of the QT interval is the same, PaSo has not been validated for this purpose and can be less accurate with lower amplitude vectors. Prone ECG leads pV₃-pV₅ correlate with lead positions that have been previously

Table Morphology correlation of the prone ECG

	QRS morphology correlation, mean (SD)	QT morphology correlation, mean (SD)
12-lead ECG	0.59 (0.09)	0.57 (0.10)
Limb leads	0.89 (0.11)*	0.86 (0.10)*
Precordial leads	0.30 (0.19)	0.28 (0.18)
V ₁ -V ₃	-0.28 (0.31)	-0.30 (0.30)
V ₄ -V ₆	0.87 (0.10) [†]	0.86 (0.10) [†]
ECG (excluding V ₁ -V ₃)	0.88 (0.08) ^{††}	0.86 (0.08) ^{††}
Lead II	0.95 (0.06)	0.92 (0.09)
Lead V ₆	0.97 (0.02)	0.96 (0.03)

ECG = electrocardiogram.

A significant P value (<.05) is denoted as

*for the comparison of limb leads vs precordial leads

[†]for V₄-V₆ vs V₁-V₃, and

^{††}for ECG (excluding V₁-V₃) vs 12-lead ECG in each respective column.

described for 15-lead ECGs.¹¹ However, leads pV₁-pV₂ are in novel positions. While they do not have commonly used corollaries, we speculate they likely serve as the inverse of the standard V₃-V₄ leads based on their anatomic position. Finally, all ECGs were obtained in healthy volunteers who were not acutely ill. Unlike patients with severe acute respiratory distress syndrome, these normal controls have otherwise normal airspace filling and thoracic impedance, which may limit the generalizability of our results. Furthermore, the body mass index range in the cohort was small, and associated changes in airspace filling and thoracic impedance may be most pronounced in prone patients with larger body sizes.

In conclusion, the prone ECG yields a high level of concordance to the standard ECG and may provide important clinical information in critically ill patients undergoing prone ventilation. This novel approach allows for cardiac rhythm monitoring and detection of repolarization abnormalities. However, validation of the prone ECG in critically ill patients is necessary.

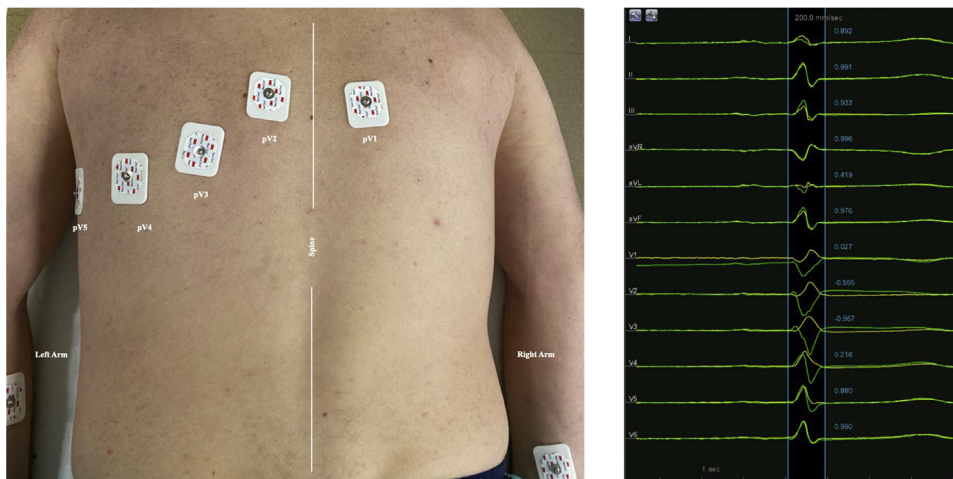


Figure Prone electrocardiogram (ECG) lead placement. Modified placement of prone ECG leads with corresponding QRS complexes (yellow) and standard QRS complexes (green).

Funding Sources

The authors have no funding sources to disclose.

Disclosures

Dr Tzou has served as a consultant for Biosense Webster, Abbott, Biotronik, and Boston Scientific; and has received speaker honoraria for Biosense Webster, Abbott, Biotronik, Boston Scientific, and Medtronic. The remaining authors have nothing to disclose.

Authorship

All authors attest they meet the current ICMJE criteria for authorship.

Patient Consent

Written informed consent was obtained from all volunteers.

Ethics Statement

The research reported in this paper adhered to the guidelines from the Helsinki Declaration as revised in 2013. The Colorado Multiple Institutional Review Board approved the protocol.

References

1. Guérin C, Reignier J, Richard JC, et al. Prone positioning in severe acute respiratory distress syndrome. *N Engl J Med* 2013;368:2159–2168.
2. White PD, Chamberlain FL, Graybiel A. Inversion of the T waves in lead II caused by a variation in position of the heart. *Heart* 1941;3:233–240.
3. Leimdorfer A. The electrocardiographic response to changes of posture during respiratory arrest following deep inspiration or expiration; clinical significance. *Ann Intern Med* 1948;29:1043–1055.
4. Bergman KS, Stevenson WG, Tillisch JH, Stevenson LW. Effect of body position on the diagnostic accuracy of the electrocardiogram. *Am Heart J* 1989; 117:204–206.
5. Khan GM. A new electrode placement method for obtaining 12-lead ECGs. *Open Heart* 2015;2:e000226.
6. Gottschalk B, Gysel M, Barbosa-Barros R, et al. The use of Fontaine leads in the diagnosis of arrhythmogenic right ventricular dysplasia. *Ann Noninvasive Electrocardiol* 2014;19:279–284.
7. Wang J, Yang B, Chen H, et al. Epsilon waves detected by various electrocardiographic recording methods. *Tex Heart Inst J* 2010;37:405–411.
8. Lopez-Sendon J, Coma-Canella I, Alcasena S, Seoane J, Gamallo C. Electrocardiographic findings in acute right ventricular infarction: Sensitivity and specificity of electrocardiographic alterations in right precordial leads V4R, V3R, V1, V2 and V3. *J Am Coll Cardiol* 1985;6:1273–1279.
9. Matetzky S, Freimark D, Chouraqui P, et al. Significance of ST segment elevations in posterior chest leads (V7 to V9) in patients with acute inferior myocardial infarction: Application for thrombolytic therapy. *J Am Coll Cardiol* 1998; 31:506–511.
10. Kligfield P, Gettes LS, Bailey JJ, et al. Recommendations for the standardization and interpretation of the electrocardiogram: Part I: The electrocardiogram and its technology: A scientific statement from the American Heart Association Electrocardiography and Arrhythmias Committee, Council on Clinical Cardiology; the American College of Cardiology Foundation; and the Heart Rhythm Society; endorsed by the International Society for Computerized Electrocardiology. *Circulation* 2007;115:1306–1324.
11. Vogiatzis I, Koulouris E, Ioannidis A, et al. The importance of the 15-lead versus 12-lead ECG recordings in the diagnosis and treatment of right ventricle and left ventricle posterior and lateral wall acute myocardial infarctions. *Acta Inform Med* 2019;27:35–39.