



## CLINICAL ARTICLE

# Use of a Gigli Saw as a Substitute Osteotomy Tool When Oscillating Saw Malfunctions Occur During Hip Arthroplasty

Keyu Kong, MD<sup>#</sup>, Yongyun Chang, PhD<sup>#</sup>, Degang Yu, PhD , Yuanqing Mao, PhD, Yiming Zeng, MD ,  
Mengning Yan, PhD, Zanjing Zhai, PhD , Huiwu Li, PhD

Shanghai Key Laboratory of Orthopaedic Implants, Department of Orthopaedic Surgery, Shanghai Ninth People's Hospital, Shanghai Jiao Tong University School of Medicine, Shanghai, China

**Objective:** The oscillating saw has some inherent disadvantages, such as notch formation and blood splash. The objective is to introduce the Gigli saw as a substitute osteotomy tool when oscillating saw malfunctions occur during surgery.

**Methods:** During our retrospective study, 120 patients (120 hips) who underwent primary total hip arthroplasty (THA) because of femoral neck fracture, femoral head necrosis, developmental hip dysplasia (Crowe I), or primary osteoarthritis between October 2017 and April 2020 at our institute were included. Sixty patients (26 men and 34 women) with a mean age of 67.3 years ( $\pm 15.1$  years) underwent femoral neck osteotomy using a Gigli saw. The other 60 patients (32 men and 28 women) with a mean age of 64.4 years ( $\pm 18.8$  years) underwent femoral neck osteotomy using an oscillating saw. Intraoperative evaluations, including osteotomy time, osteotomy height, number of notch formations, and blood splash generation, were performed. Routine anteroposterior views of the pelvis and proximal femur were obtained for all patients after surgery.

**Results:** The mean osteotomy times were  $26.60 \pm 14.80$  s and  $31.80 \pm 14.20$  s with the oscillating saw and Gigli saw, respectively ( $t = 1.964$ ,  $P = 0.0519$ ). The mean osteotomy heights were  $1.26 \pm 0.22$  cm and  $1.20 \pm 0.14$  cm with the oscillating saw and Gigli saw, respectively ( $t = 1.782$ ,  $P = 0.0773$ ). The use of a Gigli saw did not result in bone notch formation or blood splash generation when multiple blood splashes were generated in the oscillating saw group. Postoperative radiographs showed no prostheses malposition in the Gigli saw and oscillating saw groups.

**Conclusion:** The Gigli saw has various advantages and can be a substitute tool for femoral neck osteotomy during THA when oscillating saw malfunctions occur.

**Key words:** Femoral neck osteotomy; Gigli saw; Oscillating saw; Total hip arthroplasty

## Introduction

Total hip arthroplasty (THA) is a frequently performed and highly successful surgery for patients with end-stage hip disease. It can relieve pain, enhance function, and improve the patient's quality of life.<sup>1,2</sup> Globally, more than 1 million THAs are performed each year, and this number has been increasing annually.<sup>3</sup> Since the pioneering work of

Wiles, Charnley, and others in the mid-20th century, implant technology and instruments have been steadily improved and perfected.<sup>4</sup> The current procedures and devices used for THA have become normalized and routinized. However, complications can occur because of faults with the instruments. For example, the oscillating saw is the first choice as an osteotomy tool during THA. However,

**Address for correspondence** Zanjing Zhai, PhD and Huiwu Li, PhD, Shanghai Key Laboratory of Orthopaedic Implants, Department of Orthopaedic Surgery, Shanghai Ninth People's Hospital, Shanghai Jiao Tong University School of Medicine, Shanghai, 200011, P.R. China. Email: [zanjing\\_zhai@163.com](mailto:zanjing_zhai@163.com) and [huiwu1223@163.com](mailto:huiwu1223@163.com)

<sup>#</sup>Contributed equally.

Co-first authorship: The first two authors contributed equally to this manuscript.

Co-corresponding authorship: The last two authors contributed equally to this manuscript.

Received 13 November 2021; accepted 15 September 2022

machine contamination and power shortages are the main problems associated with oscillating saws. Furthermore, the use of a substitute oscillating saw or batteries in operating rooms could be limited in many regions. This can result in the time-consuming process of repeated sterilization of the oscillating saw or necessitate the acquisition of a new oscillating saw from the medical manufacturer. These situations, although infrequent, do occur, thus placing patients, especially those who are older, at risk because of the extended anesthesia time. We believe that adequate preparation for any undesired situation, regardless of its probability, is important.

The oscillating saw has certain disadvantages. First, it tends to sway because of the strong reverse impact when the saw touches the bone, potentially resulting in cortical bone injury.<sup>5</sup> Second, notch formation can occur in the osteotomy position. The oscillating saw may also lead to soft tissue and greater trochanter damage.<sup>6</sup> Furthermore, the oscillating saw generates a high frequency of blood splash during surgery,<sup>7</sup> which places surgeons at greater risk for disease transmission. Finally, because of the dead zone at the contralateral side of the femoral neck, it is difficult to estimate the osteotomy border, which increases the risk of damage to the soft tissue and acetabulum caused by the oscillating saw.

We aimed to introduce an osteotomy instrument, the Gigli saw, as a substitute tool for THA when the oscillating saw is unavailable. The use of the Gigli saw as a tool for osteotomy is not new in the field of orthopedics and traumatology; however, to the best of our knowledge, no study has previously introduced the application of the Gigli saw for femoral neck osteotomy during hip arthroplasty, which is a special procedure that requires a certain osteotomy position.

This study aimed to describe the use of the Gigli saw as a substitute osteotomy tool during THA when the oscillating saw malfunctions and to verify the practicability and efficiency of the Gigli saw.

## Materials and Methods

### Inclusion and Exclusion Criteria

This retrospective study was approved by the Medical Ethics Committee of Shanghai Ninth People's Hospital, Shanghai

Jiao Tong University School of Medicine (SH9H-2021-T84-1). We randomly and evenly divided 120 patients (120 hips) into two groups (Gigli saw group,  $n = 60$ ; oscillating saw group,  $n = 60$ ). Randomization was conducted using a random number generator and the sort cases function of SPSS 19.0 software (SPSS Inc., Chicago, IL, USA).

The inclusion criteria were as follows: (i) patients undergoing primary THA between October 2017 and April 2020; (ii) patients undergoing primary THA due to femoral neck fracture, femoral head necrosis, developmental dysplasia of hip (Crowe I), or primary osteoarthritis; and (iii) all clinical data, including sex, age, indications, osteotomy time and height, notch formation and blood splash generation, were available in clinical records and recorded during surgery. The exclusion criteria: patients with severe deformity of the femoral neck or hip ankylosis.

### Patient Data

In the Gigli saw group, 60 patients (26 men and 34 women; age,  $67.3 \pm 15.1$  years) underwent femoral neck osteotomy with a Gigli saw (Shanghai Medical Instruments, Shanghai, China). In the oscillating saw group, 60 patients (32 men and 28 women; age,  $64.4 \pm 18.8$  years) underwent femoral neck osteotomy with an oscillating saw (Linvatec; Conmed Co., New York, USA); Detailed demographic data are provided in Table 1.

### Surgical Technique

#### Anesthesia and Approach

All procedures were performed by the same group of surgeons with annual experience equal to the performance of more than 300 THAs in the lateral position using a posterolateral approach under general anesthesia (Fig. 1).

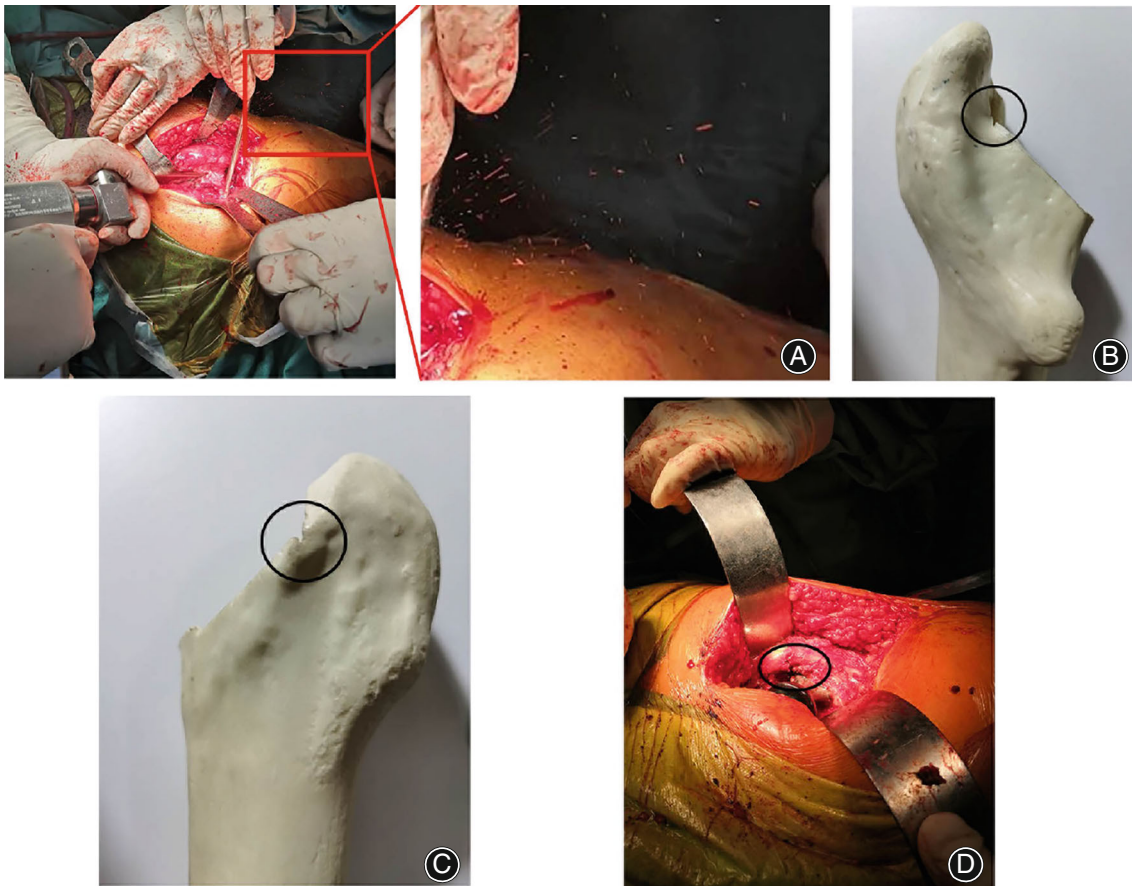#### Femoral Neck Osteotomy

After the head of the femur was dislocated posteriorly, the femoral neck was osteotomized using either a Gigli saw or an oscillating saw (Fig. 2 and Supplemental Video). Before the Gigli saw was used, we used either an osteotome or an electrotoome to create a superficial notch along the lower

TABLE 1 Demographics of the patients in the Gigli saw and oscillating saw groups

Groups	Sex		Age (years), mean $\pm$ SD	Operative side		Indications			
	Male	Female		Left	Right	Femoral neck fracture	FHN	DDH	Primary osteoarthritis
Gigli saw (N = 60)	26	34	$67.3 \pm 15.1$	37	23	8	21	18	13
Oscillating saw (N = 60)	32	28	$64.4 \pm 18.8$	28	32	10	18	23	9
Statistics	$\chi^2 = 1.201$ , $P = 0.2731$		$t = 0.9316$ , $P = 0.3535$	$\chi^2 = 2.719$ ,		$P = 0.0992$	$\chi^2 = 1.790$ , $P = 0.6171$		

Abbreviations: DDH, developmental dysplasia of the hips; FHN, femoral head necrosis; SD, standard deviation.



**Fig. 1** Deficiencies of the oscillating saw. (A) Femoral neck osteotomy using the oscillating saw during surgery. Several blood splashes were generated. (B, C) A notch on the intersecting position of the osteotomy. (D) Damage to the soft tissue and greater trochanter caused by the oscillating saw during the use of the oscillating saw

margin of the femoral neck. Using this method, the Gigli saw was unable to slide along the femoral neck and could not achieve the target cut position.

After reaming, we press-fitted the stem according to the geometry of the native proximal femur. Next, a cementless press-fit cup was implanted. Finally, we sutured the exterior surface as much as possible.

#### **Evaluation Method**

Clinical and radiographic data of all patients were obtained during and after surgery. These data included intraoperative evaluation findings such as osteotomy time, osteotomy height, notch formation, and blood splash generation. Standard radiographs included routine anteroposterior views of the pelvis and proximal femur.

#### **Osteotomy Time**

Osteotomy time was defined as the time between the beginning of osteotomy with either a Gigli saw or an oscillating saw and femoral neck division. The osteotomy time was

measured with a timer and represented the efficiency of the method with either saw.

#### **Osteotomy Height**

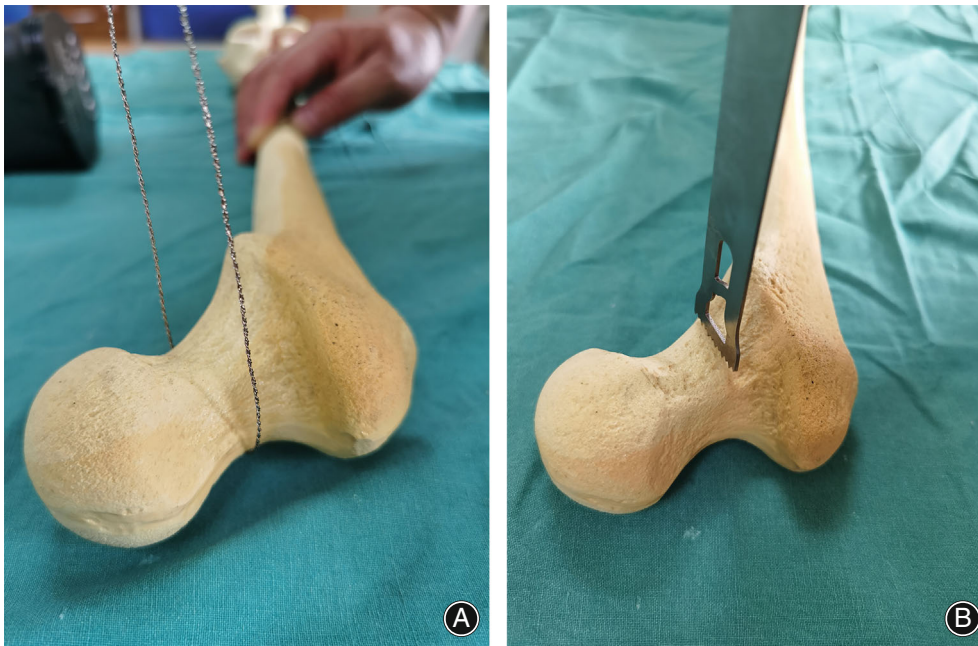
Osteotomy height was defined as the height of the osteotomy measured from the lesser trochanter to the cuneiform plane, which was measured using the postoperative anteroposterior radiograph of the pelvis. The osteotomy height represented the precision of the osteotomy method using either saw.

#### **Notch Formation and Blood Splash Generation**

Notch formation and blood splash generation commonly occur during femoral neck osteotomy with an oscillating saw. Blood splash generation was verified by surgical masks with blood splashes after surgery. The calculation of their occurrence represented the relative safety of the method using either saw.

#### **Statistical Analysis**

Statistical analysis was performed using SPSS 19.0 software (SPSS Inc., Chicago, IL, USA). Student's *t*-test was used to



**Fig. 2** Photographs of a Gigli saw (A) and an oscillating saw (B) as femoral neck osteotomy tool

compare the means of quantitative data with normal distribution. The chi-square test was used to compare the qualitative demographic data.  $P < 0.05$  was considered statistically significant.

## Results

### *Osteotomy Time*

The mean osteotomy times ( $\pm$ standard deviation) for the oscillating saw and Gigli saw groups were  $26.60 \pm 14.80$  s and  $31.80 \pm 14.20$  s, respectively. There were no significant differences in the osteotomy times between the groups ( $t = 1.964$ ;  $P = 0.0519$ ).

### *Osteotomy Height*

The mean osteotomy heights for the oscillating saw and Gigli saw groups were  $1.26 \pm 0.22$  cm and  $1.20 \pm 0.14$  cm, respectively. There were no significant differences in osteotomy heights between the groups ( $t = 1.782$ ;  $P = 0.0773$ ). All procedures resulted in the target osteotomy height of 1.0 to 1.5 cm.

### *Notch Formation and Blood Splash Generation*

In the oscillating saw group, 29 bone notches (29 hips) occurred; however, none occurred in the Gigli saw group. In the Gigli saw group, no blood splash was generated during the femoral neck osteotomy; however, many blood splashes were generated in the oscillating saw group, with blood splashes landing on the masks, glasses, and foreheads of the surgeons and assistants. During our study, four physicians attended each procedure. The intraoperative process was smooth, and postoperative radiographs showed no prostheses malposition in either group (Fig. 3).

## Discussion

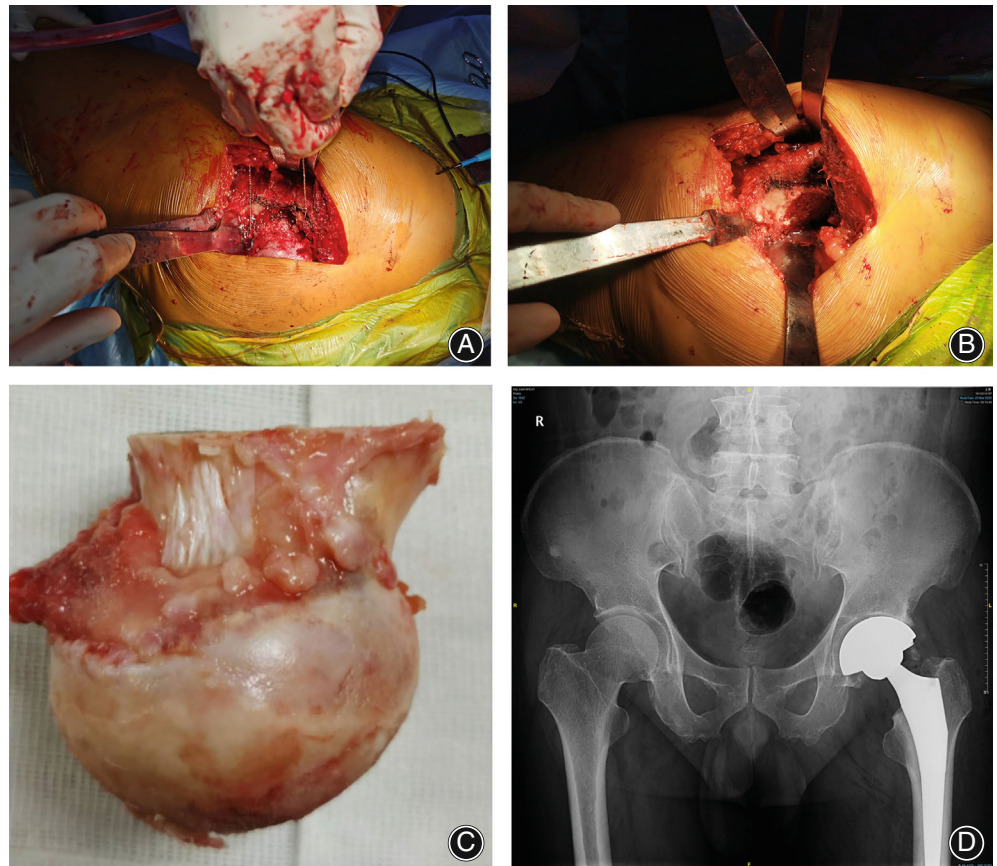
The present study demonstrated that the Gigli saw was an effective femoral neck osteotomy tool. The Gigli saw shows similar practicability and efficiency as oscillating saws with much fewer notch formation and blood splash generation, which makes it an ideal substitute osteotomy tool when oscillating saw malfunctions during THAs.

### *Gigli Saw as a Substitute Osteotomy Tool When the Oscillating Saw Malfunctions*

When the oscillating saw is used for femoral neck osteotomy during THA, a malfunction, power shortage, or contamination can occasionally occur. Repeat sterilization and replacement of the instrument increase costs and can be time-consuming.<sup>8</sup> To the best of our knowledge, this is the first study to introduce the Gigli saw as a substitute osteotomy tool for THA. This study demonstrates the satisfactory osteotomy outcomes as well as distinct advantages associated with the use of the Gigli saw for THA. During our decades of clinical work, we identified the Gigli saw as an ideal substitute tool for femoral neck osteotomy when the oscillating saw malfunctioned during THA. The Gigli saw can be sterilized and stored for long periods; therefore, it is easily accessible as a substitute tool when the oscillating saw is unavailable. Moreover, using a Gigli saw does not involve the risk of notch formation, decreases the risk of soft tissue and greater trochanter damage, and does not generate blood splash despite its high requirement for surgeon's physical strength.

### *Practicability and Efficiency of the Saws*

Operation time is an important factor in the intraoperative safety and postoperative rehabilitation of patients.<sup>9</sup> During



**Fig. 3** Intraoperative photographs and radiographic data of all patients who underwent osteotomy using a Gigli saw were obtained during and after surgery. (A) Osteotomy procedure using a Gigli saw. (B, C) Intraoperative photographs of the Gigli saw group. (D) Radiographs of a patient in the Gigli saw group after surgery

the present study, there were no significant differences in the osteotomy times for the Gigli saw and oscillating saw groups. The Gigli saw was equally efficient as a tool for femoral neck osteotomy and did not prolong the operation time. During our study, the Gigli saw group achieved a satisfactory osteotomy height, which was consistent with the preoperative planning. There were no significant differences in osteotomy heights between the groups. More interestingly, the deviation of the Gigli saw group was lower than that of the oscillating saw group. This might have been related to the saw blade deviation caused by the strong reverse impact when the high-speed saw blade touched the bone.

#### **Advantages of the Gigli Saw**

Notch generation in the femoral neck contributes to high stress concentration during canal preparation and stem implantation, thus increasing the risk of intraoperative periprosthetic femoral fracture.<sup>10-12</sup> During our study, the use of a Gigli saw as the femoral neck osteotomy tool resulted in a smooth osteotomy plane, and notch generation did not occur.

Blood splash occurs frequently when using an oscillating saw for femoral neck osteotomy. This places surgeons and assistants at greater risk for infection with blood-borne diseases transmitted from the patients.<sup>7</sup> Furthermore,

patients are susceptible to infections caused by reverse splashes that can deflect from a surface and contaminate the surgical site.<sup>13,14</sup> A surgical mask cannot provide sufficient protection against blood splash. Many surgeons neglect eye and whole face protection because of discomfort or a foggy field of view.<sup>15</sup> During our study, no blood splash was generated when using the Gigli saw as the femoral neck osteotomy tool, thus demonstrating another advantage of the Gigli saw for this purpose.

#### **Limitations and Strengths**

Our study had some limitations. First, the Gigli saw was used as the osteotomy tool only for patients with a relatively normal femoral neck, such as those with osteonecrosis of the femoral head, femoral neck fracture, hip osteoarthritis, or dysplasia of the hip (Crowe type I). Patients with more severe deformity of the femoral neck or hip ankylosis were not included in the Gigli saw group. Second, after the osteotomy was performed with the oscillating saw, it could not be repeated with the Gigli saw.

However, to our knowledge, this is the first study on the introduction of a Gigli saw as a substitute tool for oscillating saw in THAs. What is more, multiple indications were included in our study, which indicates the wide range of applications of Gigli saw in clinical uses.

### Conclusion

The present study demonstrated that the Gigli saw was an effective femoral neck osteotomy tool with several advantages. When a malfunction, power shortage, and contamination occur during THA with the oscillating saw, the Gigli saw can be an ideal substitute osteotomy tool. What is more, we believe the Gigli saw is also competitive in more complicated cases like hipankylosis. More research should be carried out in the near future to broaden the application range of Gigli saws and find its most suitable indication in clinical practice.

### Acknowledgments

This study was supported by National Natural Science Foundation of China (81672181, 82072397), Shanghai Municipal Education Commission Two-hundred Talent; Shanghai Clinical Medical Center (2017ZZ01023); Shanghai Municipal Key Clinical Specialty (shslczdk00402, shslczdk07001); The Youth Doctor Collaborative Innovation Team Project of Shanghai Ninth People's Hospital,

Shanghai Jiaotong University School of Medicine (QC201903); Project of Biobank (YBKA201911) from Shanghai Ninth People's Hospital, Shanghai Jiao Tong University School of Medicine.

### Author Contributions

Zanqing Zhai, Mengning Yan, Yuanqing Mao, and Huiwu Li contributed to the study design. Keyu Kong and Yongyun Chang performed the data collection and drafted the manuscript. Yiming Zeng and Degang Yu contributed to the statistical data analyses. All authors contributed to interpretation of results and critical revisions of the manuscript. All authors agreed on the final manuscript.

### Supporting Information

Additional Supporting Information may be found in the online version of this article on the publisher's web-site:

**Video S1** Gigli saw used as a femoral neck osteotomy tool during surgery.

### References

- Mellon SJ, Liddle AD, Pandit H. Hip replacement: landmark surgery in modern medical history. *Maturitas*. 2013;75(3):221–6.
- Branson JJ, Goldstein WM. Primary total hip arthroplasty. *AORN J*. 2003;78(6):946–69.
- Ferguson RJ, Palmer AJ, Taylor A, Porter ML, Glyn-Jones S. Hip replacement. *Lancet*. 2018;392(10158):1662–71.
- Learmonth ID, Young C, et al. The operation of the century: total hip replacement. *Lancet*. 2007;370:1508–19.
- Dimitris K, Taylor BC, Steensen RN. Excursion of oscillating saw blades in total knee arthroplasty. *J Arthroplasty*. 2010;25(1):158–60.
- Herregodts S, Verhaeghe M, Paridaens R, et al. Soft-tissue penetration of the oscillating saw during tibial resection in total knee arthroplasty. *Bone Jt J*. 2020;102(10):1324–30.
- Alani A, Modi C, Almedghio S, Mackie I. The risks of splash injury when using power tools during orthopaedic surgery: a prospective study. *Acta Orthop Belg*. 2008;74(5):678–82.
- Cichos KH, Hyde ZB, Mabry SE, et al. Optimization of orthopedic surgical instrument trays: lean principles to reduce fixed operating room expenses. *J Arthroplasty*. 2019;34(12):2834–40.
- Krebs VE, Elmallah RK, Khlopas A, et al. Wound closure techniques for total knee arthroplasty: an evidence-based review of the literature. *J Arthroplasty*. 2018;33(2):633–8.
- Lamb JN, Matharu GS, Redmond A, Judge A, Pandit HG. Risk factors for intraoperative periprosthetic femoral fractures during primary total hip arthroplasty. An analysis from the National Joint Registry for England and Wales. *J Arthroplasty*. 2019;34(12):3065–3073.e1.
- Lamb JN, Matharu GS, Redmond A, Judge A, West RM, Pandit HG. Patient and implant survival following intraoperative periprosthetic femoral fractures during primary total hip arthroplasty: an analysis from the national joint registry for England, Wales, Northern Ireland and the Isle of Man. *Bone Jt J*. 2019;101B(10):1199–208.
- Ferbert T, Jaber A, Gress N, Schmidmaier G, Gotterbarm T, Merle C. Impact of intraoperative femoral fractures in primary hip arthroplasty: a comparative study with a mid-term follow-up. *Hip Int*. 2020;30(5):544–51.
- Singh K. Splash in elective primary knee and hip replacement: are we adequately protected? *J Bone Jt Surg*. 2009;91:1074–7.
- Zhiqing L, Yongyun C, Chu W, et al. Surgical masks as source of bacterial contamination during operative procedures. *J Orthop Transl*. 2018;14:57–62.
- Hirpara KM, O'Halloran E, O'Sullivan M. A quantitative assessment of facial protection systems in elective hip arthroplasty. *Acta Orthop Belg*. 2011;77(3):375–80.