



Since January 2020 Elsevier has created a COVID-19 resource centre with free information in English and Mandarin on the novel coronavirus COVID-19. The COVID-19 resource centre is hosted on Elsevier Connect, the company's public news and information website.

Elsevier hereby grants permission to make all its COVID-19-related research that is available on the COVID-19 resource centre - including this research content - immediately available in PubMed Central and other publicly funded repositories, such as the WHO COVID database with rights for unrestricted research re-use and analyses in any form or by any means with acknowledgement of the original source. These permissions are granted for free by Elsevier for as long as the COVID-19 resource centre remains active.



Surge in testicular torsion in pediatric patients during the COVID-19 pandemic



Lisa B.E. Shields^a, Michael W. Daniels^b, Dennis S. Peppas^c, Jeffrey T. White^c, Ahmad Z. Mohamed^d, Katie Canalicchio^c, Shilo Rosenberg^e, Eran Rosenberg^{c,*}

^a Norton Neuroscience Institute, Norton Healthcare, 210 East Gray Street, Suite 1102, Louisville, KY 40202, USA

^b Department of Bioinformatics & Biostatistics, University of Louisville, Louisville KY 40292 USA

^c Norton Children's Urology, Norton Healthcare, Louisville, KY 40207, USA

^d Department of Urology, University of Louisville School of Medicine, Louisville, KY 40202, USA

^e Department of Urology, Keck School of Medicine of USC, Los Angeles, CA 90033, USA

ARTICLE INFO

Article history:

Received 24 May 2021

Revised 23 June 2021

Accepted 11 July 2021

Keywords:

Pediatric surgery

Pediatric urology

Testicular torsion

COVID-19

Orchiectomy

Abbreviations

2019-nCoV

Novel coronavirus

SARS-CoV-2

Severe acute respiratory syndrome

coronavirus 2

ED

Emergency Department

ABSTRACT

Background: Testicular torsion is a pediatric surgical emergency, and prompt diagnosis and treatment is imperative. During the COVID-19 pandemic, pediatric patients with symptoms of testicular torsion may be reluctant to seek medical care which increases the likelihood of delayed presentation and the need for an orchiectomy. This observational study sought to determine whether there was a higher number of testicular torsion cases during COVID-19.

Methods: As the first patient with COVID-19 was admitted to our facility on March 6, 2020, we identified male children ages 1–18 years with testicular torsion between March 1–December 31, 2020 (during COVID-19) compared to the same time period between 2015 and 2019 (prior to COVID-19). All patients were evaluated at our Institution's Emergency Department by a pediatric urologist.

Results: There were 38 cases of testicular torsion between March 1–December 31, 2020 compared to 15.8 cases on average during the same 10-month period between 2015 and 2019 (a total of 79 cases). There was a statistically significant increase in testicular torsion cases during the COVID-19 pandemic compared to equivalent time periods in 2015–2019 (38 vs. 15.8, $p = 0.05$). Patients with testicular torsion during the COVID-19 pandemic were younger, had a longer duration of symptoms, and had a higher number of orchiectomies (although not statistically significant).

Conclusion: During the COVID-19 pandemic, an escalation in testicular torsion cases was observed. Timely assessment, diagnosis, and surgery are crucial to prevent testicular loss and potential infertility in the future. Further evaluation is needed to elucidate the surge in testicular torsion and possible mechanisms.

© 2021 Elsevier Inc. All rights reserved.

Type of Study: Clinical research paper (observational cohort study)

1. Introduction

Testicular torsion is a pediatric urological emergency involving twisting of the spermatic cord impeding testicular blood flow [1]. Comprising 10–15% of acute scrotal disease in children, testicular torsion affects 3.8 per 100,000 males younger than 18 years annually [2]. Urgent diagnosis and treatment are mandatory as permanent ischemic damage often occurs within 4–8 h of symptom onset [1,2]. A delayed presentation for testicular torsion increases the likelihood of testicular loss or dysfunction due to prolonged ischemic duration. Despite timely surgical intervention, one-third of testes are non-viable and require an orchiectomy [1].

Since the initial report of “pneumonia of unknown etiology” in Wuhan, China on December 29, 2019 which was identified as the novel coronavirus (2019-nCoV) or the severe acute respiratory syndrome coronavirus 2 (SARS-CoV-2) [3], this pandemic has intensified globally and has greatly impacted every aspect of society. National, state, and local mandates were implemented to curtail the rampant spread of COVID-19, including shuttered businesses, school closures, and social distancing. This upheaval has affected both pediatric mental health and medical care [4–7]. The Centers for Medicare & Medicaid Services reported that 69% fewer dental visits, 44% fewer children screening services for physical and cognitive development, 44% fewer outpatient mental health services, and 22% fewer vaccinations under age 2 years were reported between March–May 2020 compared to the same period one year previously [7]. A reluctance to seek pediatric care and a delayed diagnosis of testicular torsion have been reported during the COVID-19 pandemic [4,5]. With the fears associated with COVID-19, patients with symptoms of testicular torsion may be hesitant to un-

* Corresponding author.

E-mail address: dr.rosenberg.e@gmail.com (E. Rosenberg).

dergo evaluation at the Emergency Department (ED), thereby increasing the likelihood of delayed presentation and the need for an orchiectomy.

COVID-19 has been reported to affect multiple organ systems [8,9]. Few studies have investigated whether COVID-19 impacts testicular function, with a heightened concern over spermatogenesis and infertility [8,10–12]. COVID-19 may enter the host cell by binding to the ACE2 receptor, whose expression is highest in the testes. A paucity of studies have addressed the association between COVID-19 and testicular torsion in the pediatric population [13–15].

This study investigated whether there was a significantly higher number of testicular torsion cases during the COVID-19 pandemic. The impact of testicular torsion with respect to the number of cases, patient age, duration and side of symptoms, absence of cremasteric reflex, type of surgery (orchiectomy vs. orchiopexy), and degree of testicular torsion was also analyzed.

2. Materials and methods

As the first patient with COVID-19 was admitted to our facility on March 6, 2020 [16], we identified male children ages 1–18 years with testicular torsion between March 1–December 31, 2020 (during COVID-19) compared to the same time period between 2015 and 2019 (prior to COVID-19). All patients were evaluated at our Institution’s ED by a pediatric urologist who obtained the medical history and performed a physical examination. A pediatric urologist was available at all times to evaluate and treat patients with testicular torsion. Four pediatric urologists are employed at our Institution, and the on-call schedule alternates between all four. A Doppler scrotal US was performed on all patients. There were no changes in the referral pattern over the 6-year period as all pediatric torsion cases in Louisville, KY were performed at the children’s hospital. Numerous metrics were documented including the patient’s age, duration and side of symptoms, absence of cremasteric reflex, type of surgery (orchiectomy vs. orchiopexy), and degree of testicular torsion.

2.1. Statistical analysis

Counts (%), mean (sd), and median [IQR] for each appropriate metric were summarized in characteristic tables for the COVID-19 time period versus previous equivalent annual time periods (March 1–December 31) as well as a full yearly summary. A Mann-Kendall Trend Test for Time Series evaluated the monthly testicular torsions from 2015 to 2020. Fisher’s Exact Test contrasted symptoms and surgery types (orchiectomy vs orchiopexy) between the two time periods, and the Wilcoxon Rank Sum Test evaluated the number of cases, age, duration of symptoms, and degrees of torsion. Fisher’s Exact test and Kruskal-Wallis Test on Ranks deciphered any

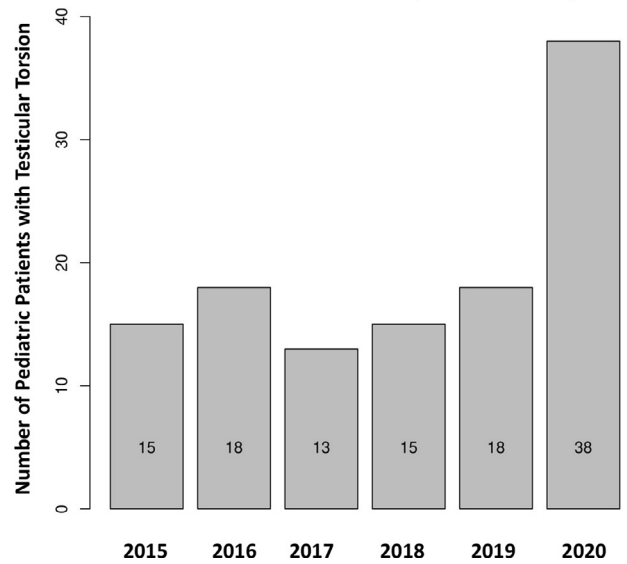


Fig. 1. The number of testicular torsion cases were tabulated within the COVID-19 10-month time frame (March 1–December 31) for each year (2015–2020).

yearly differences and presented as the second p-value. All analyses were performed using R software 4.0.0 including ‘tableone’, ‘kendall’, and ‘lubridate’ packages [17]. A p-value ≤ 0.05 was statistically significant.

3. Results

Characteristics of Patients with Testicular Torsion by Time Period (March 1–December 31, 2020 Versus the Same Months in 2015–2019)

There were 38 cases of testicular torsion between March 1–December 31, 2020 compared to 15.8 cases on average during the same 10-month period between 2015 and 2019 (a total of 79 cases) (Table 1). There was a statistically significant increase in testicular torsion cases during the COVID-19 pandemic compared to equivalent time periods in 2015–2019 (38 vs. 15.8, p = 0.05) (Table 1). Patients with testicular torsion during the COVID-10 pandemic were younger (13 vs. 14 years), had a longer duration of symptoms (16 vs. 8 h) and had a higher number of orchiectomies (50% vs. 38%), although not statistically significant (Table 2).

Characteristics of Patients with Testicular Torsion by Individual Year (March 1–December 31, 2020 Versus the Same Months in 2015–2019)

Fig. 1 depicts the number of testicular torsion cases (March 1–December 31) for each year (2015–2020). The patient age, dura-

Table 1
Characteristics of patients with testicular torsion at our institution by time period (March 1–December 31, 2020 versus same period 2015–2019).

Characteristics	Pre-COVID-19 (March 1–December 31, 2015–2019) N = 79	COVID-19 (March 1–December 31, 2020) N = 38	P-Value
Number of cases on average during this 10-month time period	15.8 (2.2)	38	0.05
Age (Years)	14 [12,15]	13 [12,14]	0.12
Duration of symptoms (Hours)	8 [5,48]	16 [5,48]	0.70
Absent cremasteric reflex = Yes	26 (33%)	10 (26%)	0.52
Side of torsed testicle			0.31
Both	2 (3%)	0 (0%)	
Left	39 (49%)	24 (63%)	
Right	38 (48%)	14 (37%)	
Orchiectomy performed	30 (38%)	19 (50%)	0.24
Degrees of torsion	360 [360,720]	360 [360,540]	0.60

Table 2
Characteristics of patients with testicular torsion at our institution by individual year (March 1–December 31, 2020 versus same period 2015–2019).

Characteristics	2015 N = 15	2016 N = 18	2017 N = 13	2018 N = 15	2019 N = 18	2020 N = 38	P-Value
Age (Years)	15 [13,16]	13 [12,14]	13 [12,14]	14 [12,15]	14 [13,16]	13 [12,14]	0.18
Duration of symptoms (Hours)	10 [6,34]	19 [5,72]	8 [6,12]	8 [4,60]	8 [5,39]	16 [5,48]	0.86
Absent cremasteric reflex = Yes	6 (40%)	2 (11%)	6 (46%)	4 (27%)	8 (44%)	10 (26%)	0.18
Side of torsed testicle							0.65
Both	0 (0)	1 (6%)	0 (0%)	0 (0%)	1 (6%)	0 (0%)	
Left	8 (53%)	7 (39%)	6 (46%)	9 (60%)	9 (50%)	24 (63%)	
Right	7 (47%)	10 (56%)	7 (54%)	6 (40%)	8 (44%)	14 (37%)	
Orchiectomy performed	5 (33%)	10 (56%)	6 (46%)	3 (20%)	6 (33%)	19 (50%)	0.27
Degrees of torsion	360 [360,540]	540 [315,720]	360 [180,540]	360 [315,720]	540 [360,720]	360 [360,540]	0.45

tion and side of symptoms, absence of cremasteric reflex, type of surgery (orchietomy vs. orchiopexy), and degree of testicular torsion were not statistically different between the COVID-19 period and pre-COVID-19 by year.

4. Discussion

COVID-19 may enter the host cell by binding to the ACE2 receptor [8,18]. While the ACE2 receptor is found in various cell types including the lungs, heart, intestines, and kidneys, its expression is highest in the testes, in particular the Sertoli and Leydig cells and spermatogonia [8,9,11,12,18]. There is significant evidence regarding testis involvement in severe COVID-19 infection causing death. In Yang and colleagues' study 12 patients with COVID-19 who underwent postmortem examinations, the testes demonstrated significant seminiferous tubular and Sertoli cell injury, reduced Leydig cells, and mild lymphocytic inflammation [19]. In Ma and colleagues' study of 81 males with moderate-severe COVID-19 compared with age-matched healthy men, there was a statistically significantly elevated serum LH and decreased T/LH ratio in men with COVID-19, reflecting primary hypogonadism with impaired steroidogenesis resulting from testicular failure involving the Leydig cells [20]. Furthermore, COVID-19-associated inflammation may affect the blood-testis barrier integrity altering spermatogenesis and testosterone release [9,11]. It has been reported that testicular abnormalities may be caused by either direct testicular damage by COVID-19 or by indirect inflammatory/immune response in the testes [10]. These studies suggest that COVID-19 may result in spermatogenic failure and male reproductive dysfunction in men with severe infections [11,12,21].

Although there is a delay in patients' going to their pediatrician or ED and a delay due to COVID-19 concerns, these reasons do not fully explain the reason for the higher number of testicular torsion cases. COVID-19 may directly attack vascular endothelial cells and disrupt the vascular barrier, resulting in disseminated intravascular coagulation and inflammatory cell infiltration [22]. While coagulopathy has been reported in COVID-19 which may predispose patients to hypercoagulability-related disorders such as thrombosis [23], it is uncertain whether hypercoagulability is related to the rise in testicular torsion cases. While there is a vascular effect of COVID-19 and the higher expression of ACE2 receptors in the testes, the mechanism of testicular torsion is mechanical (twisting of the testes) and not intravascular. Further investigation of the possible mechanisms between COVID-19 and testicular torsion are needed.

Several anecdotal reports and studies have described testicular pain/edema in patients with pulmonary symptoms [24–27] or who lacked respiratory symptoms [28]. Gagliardi and colleagues described epididymoorchitis in a 14-year-old boy with COVID-19 without respiratory symptoms [29]. Few studies have reported the association between COVID-19 and testicular torsion in the pediatric population [13–15]. Nelson and colleagues identified 94 cases

of testicular torsion in patients > 1 year old, with 77 pre-COVID-19 (1/1/2018– 2/29/2020) and 17 during COVID-19 (3/1/2020– 5/31/2020) [15]. The number of torsion cases per week increased significantly during COVID-19 compared to pre-COVID-19 (1.3 versus 0.6 cases/week, respectively; $p=0.021$). In Littman and colleagues' study of 78 boys ages 1–18 years from March 15–May 4, 2020 compared to the same time window from 2015 to 2019, they determined that there was no delay in presentation to a medical facility and no higher rate of orchiectomy during the COVID-19 period [14]. Holzman and colleagues conducted a study of 221 patients aged 2 months to 18 years, comparing the COVID-19 period (March–July 2020) and pre-COVID-19 (January 2019– February 2020) [13]. These authors determined a significantly longer time from testicular torsion symptom onset to presentation during COVID-19 compared to pre-COVID-19 (17.9 h vs 7.5 h, $p=0.04$) and a higher proportion of patients who reported a delay in presentation (46 vs 33%). These authors encouraged more patient education in managing testicular torsion during COVID-19.

Similar to Nelson and colleagues' study, the present study reported a statistically significant increase in the number of cases of testicular torsion during a 10-month period during COVID-19 compared to the same time period in the 5 years before COVID-19. While our study revealed a higher number of orchiectomies during the COVID-19 pandemic compared to pre-COVID-19, this finding was not statistically significant. Similarly, the 3 previous studies of testicular torsion and COVID-19 did not report a higher rate of orchiectomies during COVID-19. The most important aspect of the current study is the long observation period of 10 months during the COVID-19 pandemic compared to the 3 previous studies in the literature. In this respect, we were able to confirm the significant elevation of testicular torsion cases over a longer period of time.

4.1. Strengths and limitations

Our 6-year study of testicular torsion emphasizes a significantly increased number of cases of testicular torsion paralleling the COVID-19 pandemic. There was a significant rise in testicular torsion cases during the first 10 months of COVID-19 compared to the same months in the previous 5 years. We also observed an increase in the duration of symptoms, higher number of orchiectomies, and younger patient age during COVID-19. The referral pattern of patients to our pediatric urologists did not contribute to this startling surge. We reported a large number of patients in our study who were evaluated for testicular torsion by our pediatric urologists over the 6-year period. Additionally, we assessed numerous metrics associated with testicular torsion. Our study represents a cautionary warning to other communities to be alert to the possible increase in the number of testicular torsion cases. Furthermore, our study highlights the need for the entire team, including anesthesiologists, who treat these patients to be cognizant of the possible association between COVID-19 and testicular torsion. The

results of our study may be generalized to other community-based medical practices.

Limitations of the current study are its retrospective nature and that patients did not undergo electron microscopy testing or histologic testing for COVID-19. Additionally, not all patients underwent testing for COVID-19 either by detection of IgM and IgG antibodies in the blood or nasopharyngeal swabs.

5. Conclusion

Our study demonstrated an increase in testicular torsion cases in the hospital during the COVID-19 pandemic compared to the same months of the previous 5 years, however, we are unable to attribute these findings directly to COVID-19. Being cognizant of the symptoms of testicular torsion during COVID-19 is of critical importance. Prompt assessment, diagnosis, and surgical intervention are crucial to prevent testicular loss and potential infertility in the future. Further evaluation is needed to evaluate the association between COVID-19 and testicular torsion and the mechanism of injury.

Declaration of Competing Interest

None.

Funding source

None.

Ethical disclosure

The University of Louisville Institutional Review Board (IRB Number 20.0778) determined that our study was exempt according to 45 CFR 46.101(b) under Category 4.

Acknowledgement

We acknowledge Norton Healthcare for their continued support.

Supplementary materials

Supplementary material associated with this article can be found, in the online version, at doi:10.1016/j.jpedsurg.2021.07.008.

References

- [1] Dajusta DG, Granberg CF, Villanueva C, et al. Contemporary review of testicular torsion: new concepts, emerging technologies and potential therapeutics. *J Pediatr Urol* 2013;9:723–30.
- [2] Sharp VJ, Kieran K, Arlen AM. Testicular torsion: diagnosis, evaluation, and management. *Am Fam Phys* 2013;88:835–40.
- [3] Li Q, Guan X, Wu P, et al. Early transmission dynamics in Wuhan, China, of novel coronavirus-infected pneumonia. *N Engl J Med* 2020;382:1199–207.
- [4] Ciacchini B, Tonioli F, Marciano C, et al. Reluctance to seek pediatric care during the COVID-19 pandemic and the risks of delayed diagnosis. *Ital J Pediatr* 2020;46:87.
- [5] Lynn RM, Avis JL, Lenton S, et al. Delayed access to care and late presentations in children during the COVID-19 pandemic: a snapshot survey of 4075 paediatricians in the UK and Ireland. *Arch Dis Child* 2021;106:e8.
- [6] Santoli JM, Lindley MC, DeSilva MB, et al. Effects of the COVID-19 Ppndemic on routine pediatric vaccine ordering and administration - United States, 2020. *MMWR Morb Mortal Wkly Rep* 2020;69:591–3.
- [7] Wyckoff A.S. Delayed care: AAP responds to report on drop in pediatric visits in Medicaid, CHIOP. <https://www.aappublications.org/news/2020/09/28/delayedcare092820>. Accessed June 23, 2021.
- [8] La Marca A, Busani S, Donno V, et al. Testicular pain as an unusual presentation of COVID-19: a brief review of SARS-CoV-2 and the testis. *Reprod Biomed Online* 2020;41:903–6.
- [9] Lundholm MD, Poku C, Emanuele N, et al. SARS-CoV-2 (COVID-19) and the endocrine system. *J Endocr Soc* 2020;4:bvaa144.
- [10] Illiano E, Trama F, Costantini E. Could COVID-19 have an impact on male fertility? *Andrologia* 2020;52:e13654.
- [11] Verma S, Saksena S, Sadri-Ardekani H. ACE₂ receptor expression in testes: implications in coronavirus disease 2019 pathogenesis. *Biol Reprod* 2020;103:449–51.
- [12] Wang Z, Xu X. scRNA-seq profiling of human testes reveals the presence of the ACE2 receptor, a target for SARS-CoV-2 infection in spermatogonia, Leydig and Sertoli cells. *Cells* 2020;9:920.
- [13] Holzman SA, Ahn JJ, Baker Z, et al. A multicenter study of acute testicular torsion in the time of COVID-19. *J Pediatr Urol* 2021.
- [14] Littman AR, Janssen KM, Tong L, et al. Did COVID-19 affect time to presentation in the setting of pediatric testicular torsion? *Pediatr Emerg Care* 2021;37:123–5.
- [15] Nelson CP, Kurtz MP, Logvinenko T, et al. Timing and outcomes of testicular torsion during the COVID-19 crisis. *J Ped Urol* 2020;16:841.e1–841.e5.
- [16] Shields LBE, Hester ST, Schulz PS, et al. Healthcare system approach to managing COVID-19 in a metropolitan community in Kentucky. *Med (Baltim)* 2020;99(38):e22254.
- [17] R. Core Team. R: a language and environment for statistical computing. r foundation for statistical computing. <https://www.R-project.org>. Accessed June 23, 2021.
- [18] Wang S, Zhou X, Zhang T, et al. The need for urogenital tract monitoring in COVID-19. *Nat. Rev.* 2020;17:314–15.
- [19] Yang M, Chen S, Huang B, et al. Pathological findings in the testes of COVID-19 patients: clinical implications. *Eur Urol Focus* 2020;6:1124–9.
- [20] Ma L, Xie W., Li D., et al. Effect of SARS-CoV-2 upon male gonadal function: a single center-based study. medRxiv. <https://doi.org/10.1101/2020.03.21.20037267>. Accessed June 23, 2021.
- [21] Shoar S, Khavandi S, Tabibzadeh E, et al. A late COVID-19 complication: male sexual dysfunction. *Prehosp Disaster Med* 2020;35:688–9.
- [22] COVID-19 and vascular disease. *EBioMedicine* 2020;58:102966.
- [23] Shi W, Lv J, Lin L. Coagulopathy in COVID-19: focus on vascular thrombotic events. *J Mol Cell Cardiol* 2020;146:32–40.
- [24] Boyd C. Coronavirus could affect your testicles: man, 37, suffers swelling and 'discomfort' in his scrotum as well as the typical cough and fever before testing positive for covid-19. <https://www.dailymail.co.uk/news/article-8682245/Coronavirus-affect-testicles-Man-37-suffers-swelling-discomfort-scrotum.html>. Accessed June 23, 2021.
- [25] Ediz C, Tavukcu HH, Akan S, et al. Is there any association of COVID-19 with testicular pain and epididymo-orchitis? *Int J Clin Pract* 2020;75:e13753.
- [26] Lee B.Y. What do testicles have to do with COVID-19 coronavirus? <https://www.forbes.com/sites/brucelee/2020/04/30/what-do-testicles-have-to-do-with-covid-19-coronavirus/?sh=2b7888da1690>. Accessed June 23, 2021.
- [27] Thompson A. Man with coronavirus develops testicular swelling in unusual complication. <https://sports.yahoo.com/coronavirus-covid19-testicles-genitals-pain-symptoms-094148967.html>. Accessed June 23, 2021.
- [28] Kim J, Thomsen T, Sell N, et al. Abdominal and testicular pain: an atypical presentation of COVID-19. *Am J Emerg Med* 2020;38:1542.
- [29] Gagliardi L, Bertacca C, Centenari C, et al. Orchiepididymitis in a boy with COVID-19. *Pediatr Infect Dis J* 2020;39:e200–2.