



## Case report

# Successful treatment of ischemic stroke associated with brachiocephalic artery stenosis using alteplase

Yuta Mitani<sup>1</sup>, Zen Kobayashi<sup>1</sup>, Eijiro Hattori<sup>2</sup>, Yoshiyuki Numasawa<sup>3,4</sup>,  
Shoichiro Ishihara<sup>1</sup>, Hiroyuki Tomimitsu<sup>1</sup>, and Shuzo Shintani<sup>1</sup>

<sup>1</sup>Department of Neurology, JA Toride Medical Center, Japan

<sup>2</sup>Department of Cardiology, JA Toride Medical Center, Japan

<sup>3</sup>Department of Internal Medicine, New Tokyo Hospital, Japan

<sup>4</sup>Aozora Clinic, Japan

## Abstract

**Introduction:** Brachiocephalic artery stenosis rarely causes right hemispheric infarction with associated left hemiparesis. To date, there have been no reported cases of stroke associated with brachiocephalic artery stenosis that were successfully treated with recombinant tissue-type plasminogen activator (rt-PA), alteplase.

**Case Report:** An 80-year-old woman presented with left hemiparesis. Brain computed tomography showed no hemorrhage, and computed tomography angiography demonstrated brachiocephalic artery stenosis. Alteplase was administered based on a diagnosis of ischemic stroke. Brain magnetic resonance imaging showed multiple acute infarctions. Thereafter, the blood pressure of the right arm was found to be lower than that of the left arm. The patient's neurological deficits gradually improved; she was eventually able to walk again and was thus discharged home.

**Conclusion:** While the combination of left hemiparesis and a decrease in blood pressure in the right arm are well known in patients with stroke associated with Stanford type A aortic dissections, it may also occur in patients with stroke due to brachiocephalic artery stenosis. Unlike stroke associated with Stanford type A aortic dissections, stroke due to brachiocephalic artery stenosis may be treated with alteplase.

**Key words:** alteplase, brachiocephalic artery, common carotid artery, subclavian artery

(J Rural Med 2021; 16(2): 123–125)

## Introduction

The brachiocephalic artery is the first branch of the aortic arch and divides into the right subclavian artery and the right common carotid artery (CCA). Although rare, brachiocephalic artery stenosis causes left-sided hemiparesis due to right hemispheric infarction<sup>1–3</sup>. To date, there have been no reported cases of stroke associated with brachiocephalic artery stenosis that were successfully treated with recombinant tissue-type plasminogen activator (rt-PA), alteplase.

Here, we report the case of an 80-year-old woman with stroke associated with brachiocephalic artery stenosis who was successfully treated with alteplase.

## Case Report

An 80-year-old woman presenting with ambulatory difficulty was brought to our hospital by ambulance conduction. She was last known well at 14:00 and arrived at the hospital at 16:49. Her medical history included previous myocardial infarction, diabetes mellitus, hypertension, and dyslipidemia; she had been consulting our hospital's Department of Cardiology for these conditions and was taking aspirin, clopidogrel, nicorandil, azilsartan, carvedilol, atorvastatin, ezetimibe, voglibose, and mitiglinide. She had a history of smoking until the age of 40. She had no history of atrial fibrillation, Takayasu arteritis, or alcohol consumption.

Her vital signs upon arrival were as follows: body temperature, 36.6 °C; blood pressure, 203/92 mmHg on the left

Received: December 16, 2020

Accepted: January 5, 2021

Correspondence: Zen Kobayashi, Department of Neurology, JA Toride Medical Center, 2-1-1 Hongo, Toride, Ibaraki 302–0022, Japan  
E-mail: kobayashiz112@yahoo.co.jp

This is an open-access article distributed under the terms of the Creative Commons Attribution Non-Commercial No Derivatives

(by-nc-nd) License <<http://creativecommons.org/licenses/by-nc-nd/4.0/>>.



arm and 188/152 mmHg on the right; and a pulse of 93 beats/min with a regular rhythm. Her National Institutes of Health Stroke Scale (NIHSS) score was 8; there was complete left hemianopia (2 points), left arm weakness (2 points), left leg weakness (2 points), and marked left-sided inattention (2 points).

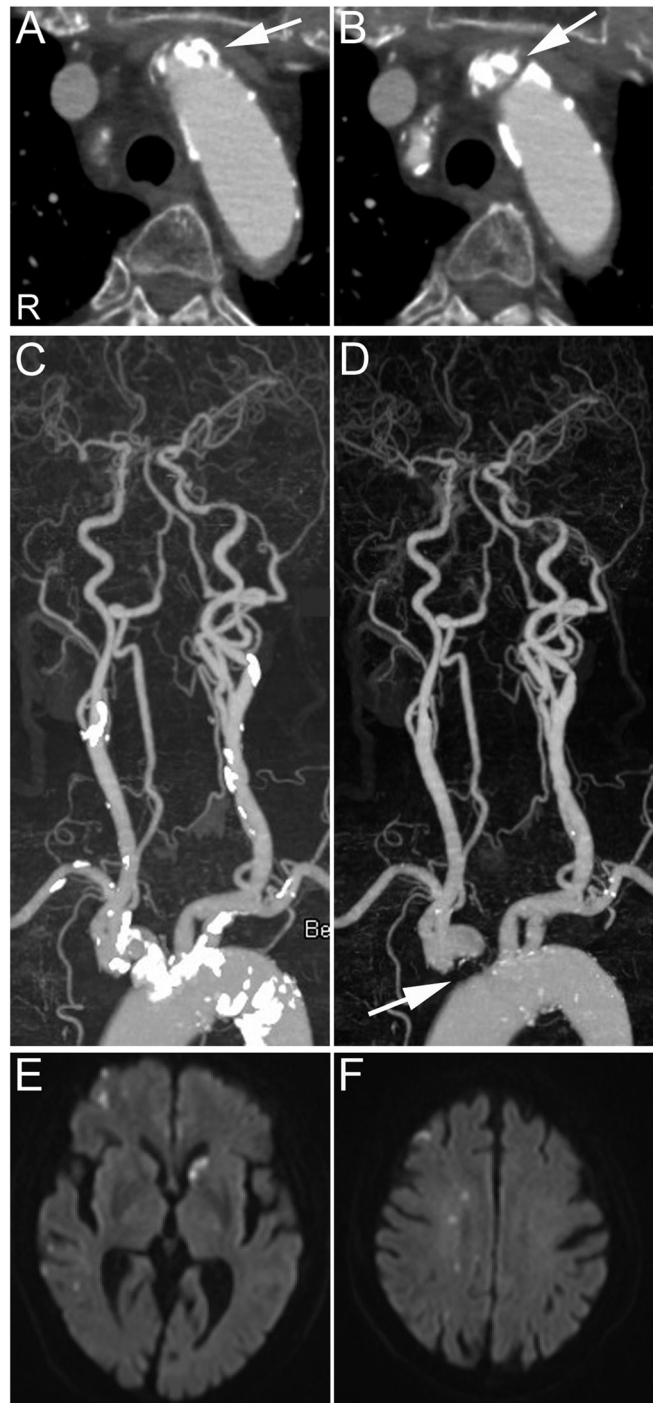
Blood tests showed a white blood cell count of 5,650/ $\mu\text{L}$ , a hemoglobin level of 11.3 g/dL, a platelet count of  $24.8 \times 10^4/\mu\text{L}$ , a prothrombin time-international normalized ratio (PT-INR) of 0.85, an activated partial thromboplastin time (APTT) of 21.1 seconds, a D-dimer of 2.46  $\mu\text{g}/\text{mL}$  (reference range:  $<1.0 \mu\text{g}/\text{mL}$ ), a low-density lipoprotein cholesterol (LDL-C) level of 61 mg/dL, a blood sugar level of 210 mg/dL, and a hemoglobin A1c of 7.1% (reference range:  $<6.0\%$ ).

Brain computed tomography (CT) showed no hemorrhage, and CT angiography demonstrated calcifications in the aortic aorta, brachiocephalic artery, bilateral subclavian arteries, bilateral CCAs, and bilateral internal carotid arteries (ICAs) (Figure 1). Severe stenosis of the brachiocephalic artery was demonstrated after the calcifications were removed from the CT angiography images (Figure 1). No significant stenosis was demonstrated in the CCAs or ICAs. Hypoplasia of the origin of the left anterior cerebral artery (ACA) was observed, suggesting that the left ACA territory was supplied by the right ACA<sup>4</sup>.

After decreasing the patient's blood pressure through intravenous administration of nicardipine, alteplase was administered based on a diagnosis of ischemic stroke. Thereafter, the blood pressure of the right arm (range, 120–140 mmHg) was found to be lower compared to that of the left arm (range, 180–200 mmHg). Brain magnetic resonance imaging (MRI) demonstrated multiple acute infarctions in the right middle cerebral artery (MCA) and left ACA territories (Figure 1).

Transthoracic echocardiography and Holter electrocardiography were performed two days after admission and showed no marked abnormalities. The patient's stroke was considered to be due to plaque rupture in the brachiocephalic artery. Carotid ultrasonography five days after admission demonstrated hyperechoic plaques in the bilateral CCAs and ICAs but with no significant stenosis. The peak systolic velocities of the right CCA and ICA were decreased to 25.8 and 47.0 cm/s, respectively, while those of the left CCA and ICA were within normal limits (97.5 and 70.1 cm/s, respectively). Furthermore, the flow of the right vertebral artery (VA) was reversed. These findings could be explained by brachiocephalic artery stenosis<sup>5</sup>. Thoracic MR angiography demonstrated severe stenosis of the brachiocephalic artery, similar to the findings of the CT angiography.

Surgical intervention for brachiocephalic artery stenosis was withheld due to the absence of subclavian steal syndrome and right upper limb symptoms. The patient's neurological deficits gradually improved after the administration



**Figure 1** A, B: Axial CT angiography images showing severe stenosis and calcifications at the origin of the brachiocephalic artery (arrows). The letter “R” indicates the right side. C: Three-dimensional computed tomography angiography showing calcifications at the aortic aorta, brachiocephalic artery, bilateral subclavian arteries, bilateral CCAs, and bilateral ICAs. D: After removing the calcifications from the CT angiography images, severe stenosis of the brachiocephalic artery can be seen (arrow). E, F: Diffusion-weighted brain magnetic resonance image showing multiple acute infarctions in the right MCA and left ACA territories.

of alteplase; she was eventually able to walk again and was discharged 72 days after admission.

## Discussion

This is the first reported case of ischemic stroke associated with brachiocephalic artery stenosis that was successfully treated with alteplase. The patient's blood pressure in the upper limbs initially exhibited slight laterality, and the laterality became evident after the administration of nicardipine. Severe stenosis of the brachiocephalic artery, as was demonstrated on CT angiography, suggested that plaque rupture from the brachiocephalic artery was the cause of stroke in our patient. The infarction on the left ACA territory could be explained by an artery-to-artery embolism as this territory is considered to be supplied by the right ACA.

Although we could not evaluate the brachiocephalic artery itself using ultrasonography, carotid ultrasound showed indirect findings suggestive of brachiocephalic artery stenosis<sup>5</sup>. Namely, there was a decrease in the flow velocity of the

right CCAs and ICAs, as well as reflux of the VA.

Patients who develop stroke due to Stanford type A aortic dissections may present with a combination of left hemiparesis and a decrease in the blood pressure of the right arm in association with involvement of the brachiocephalic artery<sup>6, 7</sup>. Koga et al. reported that left hemiparesis and upper limb systolic blood pressure laterality ( $\geq 20$  mmHg) were demonstrated in 74% and 71%, respectively, of patients with stroke associated with Stanford type A aortic dissection<sup>7</sup>.

In contrast, there have been few reports describing the combination of left hemiparesis and a decrease in blood pressure of the right arm in patients with stroke due to brachiocephalic artery stenosis<sup>8</sup>. Unlike cases of stroke associated with Stanford type A aortic dissection, which is a contraindication to alteplase administration, stroke due to brachiocephalic artery stenosis may be treated with alteplase.

**Conflict of interest:** The authors report no disclosures relevant to the manuscript.

## References

1. Youn SW, Yu SW, Lee NJ, *et al.* Neurological picture. Acute middle cerebral artery stroke and an innominate steal from a ruptured brachiocephalic trunk atheroma. *J Neurol Neurosurg Psychiatry* 2009; 80: 492–493. [Medline] [CrossRef]
2. Nakajima M, Yasaka M, Minematsu K. Mobile thrombus from a ruptured plaque in the brachiocephalic artery. *J Stroke Cerebrovasc Dis* 2008; 17: 423–425. [Medline] [CrossRef]
3. Ikenouchi H, Washida K, Yoshimoto T, *et al.* Balloon-like Mobile Plaque in the Innominate Artery: Ultrasonographic and Pathological Perspectives of Repetitive Embolism. *J Stroke Cerebrovasc Dis* 2019; 28: e95–e97. [Medline] [CrossRef]
4. Roh JK, Kang DW, Lee SH, *et al.* Significance of acute multiple brain infarction on diffusion-weighted imaging. *Stroke* 2000; 31: 688–694. [Medline] [CrossRef]
5. Grant EG, El-Saden SM, Madrazo BL, *et al.* Innominate artery occlusive disease: sonographic findings. *AJR Am J Roentgenol* 2006; 186: 394–400. [Medline] [CrossRef]
6. Iguchi Y, Kimura K, Sakai K, *et al.* Hyper-acute stroke patients associated with aortic dissection. *Intern Med* 2010; 49: 543–547. [Medline] [CrossRef]
7. Koga M, Iguchi Y, Ohara T, *et al.* Acute ischemic stroke as a complication of Stanford type A acute aortic dissection: a review and proposed clinical recommendations for urgent diagnosis. *Gen Thorac Cardiovasc Surg* 2018; 66: 439–445. [Medline] [CrossRef]