



# Recurrent primary malignant melanoma of the urinary bladder; a case report

Negar Behtash<sup>a</sup>, Fateme Guitinavard<sup>a</sup>, Navid Ahmadi<sup>b,\*</sup>, Soroor Bizhanzadeh<sup>c</sup>

<sup>a</sup> Urology Research Center, Tehran University of Medical Sciences, Tehran, Iran

<sup>b</sup> Students' Scientific Research Center, Tehran University of Medical Sciences, Tehran, Iran

<sup>c</sup> Imam Ali Hospital, Andimeshk, Iran

## ARTICLE INFO

### Keywords:

Urinary bladder  
Melanoma  
Primary malignant melanoma  
Recurrent primary malignant melanoma  
TURBT

## ABSTRACT

Primary malignant melanoma (PMM) of the urinary bladder is a rare disease. Symptoms include gross hematuria and irritative LUTS. The diagnosis is made with cystoscopy and TURBT. Treatment options include TURBT and adjuvant therapies. We present a 61-year-old female who was referred with persistent irritative LUTS without gross or microscopic hematuria. After undergoing cystoscopy, TURBT, and extensive workup, she was diagnosed with PMM of the urinary bladder. Due to her past medical history, recurrent PMM of the urinary bladder was the final diagnosis. She refused to receive further treatment or refer for follow-up.

## 1. Introduction

Primary malignant melanoma of the bladder is a rare entity, with only 30 cases reported.<sup>1</sup> Melanoma of the genitourinary tract is mostly secondary, presenting itself as a metastasis from other primary sites, mostly cutaneous origin. PMM accounts for 0.2% of all melanomas.<sup>1</sup> In the genitourinary tract penis and urethra are the most common sites of primary malignant melanoma.<sup>2</sup> Most common symptoms include gross hematuria; however, the disease can also cause irritative LUTS such as dysuria, nocturia, and frequency. The diagnosis is made using cystoscopy and TURBT. Due to its rare incidence and lack of data, risk factors are still to be found. Treatment is based on the local staging of the tumor but TURBT and adjuvant immunotherapy are considered to be the standard treatment for most patients.<sup>3</sup> However, determining the best possible treatment plan requires further study. We present a 61-year-old female who presented herself with irritative symptoms and no hematuria and was later diagnosed with recurrent primary malignant melanoma of the bladder. To our knowledge, this is the second case of recurrent primary malignant melanoma of the bladder and the thirty-first case of reported primary malignant melanoma.

## 2. Case presentation

A 61-year-old female was referred with a complaint of persistent

irritative LUTS without frank hematuria, for at least 5 months. She had no history of smoking, alcohol consumption, or comorbidities. She had a negative family history of malignancies. She had a history of transurethral resection (TUR) of a bladder mass, later diagnosed as primary malignant melanoma, two years ago, with no follow-up or further treatment due to her poor adherence.

Initial lab tests such as urine analysis (U/A) and urine culture (U/C) were normal. She didn't have a history of gross hematuria and U/A was negative for RBCs. On ultrasound exam, two sessile masses were seen at the base of the bladder. In cystoscopy, two separate masses with a brown-black appearance were seen above the trigon, near the mid-line. The masses were resected and sent for microscopic evaluation. The pathologist reported them as "urothelial mucosa with predominantly melanin pigment and sheets of proliferation neoplastic spindle cells with hyperchromatic oval nuclei" (Fig. 1), which is compatible with malignant melanoma. Regrettably, no immunohistochemistry studies were done. An exhaustive investigation was performed to exclude other primary sites of melanoma. Dermatologic, ophthalmologic, and gastrointestinal studies were negative. CT scan of brain, chest, and abdominopelvic was negative. Hence, the final diagnosis was recurrent primary malignant bladder melanoma. Unfortunately, the patient refused to receive any adjuvant therapy and didn't attend any of the follow-up sessions. Fortunately, the patient is still alive 30 months after the first TURBT.

\* Corresponding author.

E-mail addresses: [Negarbehtash@gmail.com](mailto:Negarbehtash@gmail.com) (N. Behtash), [f\\_guitynavard@gmail.com](mailto:f_guitynavard@gmail.com) (F. Guitinavard), [navidahmadi726@gamil.com](mailto:navidahmadi726@gamil.com) (N. Ahmadi), [SoroorBizhanzadeh61@gmail.com](mailto:SoroorBizhanzadeh61@gmail.com) (S. Bizhanzadeh).

<https://doi.org/10.1016/j.eucr.2022.102026>

Received 26 December 2021; Accepted 4 February 2022

Available online 5 February 2022

2214-4420/© 2022 The Authors.

Published by Elsevier Inc.

This is an open access article under the CC BY-NC-ND license

(<http://creativecommons.org/licenses/by-nc-nd/4.0/>).

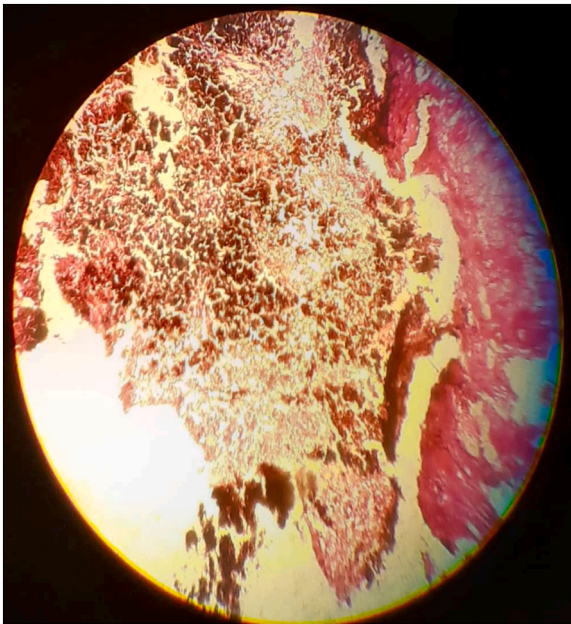


Fig. 1. Section of tumor mass, showing pigmented malignant melanocytes.

### 3. Discussion

There have been 30 cases of primary malignant melanoma of the bladder to date.<sup>1</sup> It is mostly seen as a metastatic lesion from a cutaneous origin. Only 0.2% of all melanomas are PMM of the bladder.<sup>1</sup> It involves patients from 34 to 82 years old and typically presents itself in patients older than 50<sup>1</sup>. It slightly affects men more than women. This disease typically presents itself with gross hematuria, which is seen in patients with more advanced diseases. Other symptoms include irritative LUTS like dysuria, frequency, nocturia, and urgency. It's also possible to accidentally discover asymptomatic PMM on imaging studies for other conditions.<sup>4</sup> Patients' symptoms are based on the severity of the disease, size, and location of the tumor inside the bladder. The main method of diagnosis includes cystoscopy and TURBT. In cystoscopy, the tumor has a darkly pigmented appearance. Microscopically, malignant melanoma of the bladder can mimic high-grade urothelial carcinoma but mostly contains spindle cells with necrosis and abnormal melanocytes.<sup>1,2,5</sup> Varying range of morphology makes the diagnosis challenging. Immunohistochemistry studies can solve this problem. Immunohistochemistry studies show that PMM is positive for Melan-A, S100, and hmb45, but it has been reported that bladder melanoma doesn't have vimentin or keratin markers.<sup>5</sup> It has been stated in some studies that BRAF mutation has an association with PMM.<sup>4</sup>

Distinguishing primary from metastatic bladder melanoma is crucial

since they have different prognoses and treatment plans. Metastatic bladder melanoma is more common than PMM of the bladder. The following criteria is used to distinguish the two; 1. no evidence of regression of a primary cutaneous lesion, 2. no cutaneous lesion suggesting a skin primary, 3. no evidence of visceral melanoma, 4. pattern of recurrence should be consistent with a recurrent melanoma at a primary site and seeing atypical melanocytes at tumor margin in microscopic evaluation.<sup>2</sup>

Bladder melanoma has a poor prognosis. Nearly two-thirds of patients lose their life within 3 years of diagnosis.<sup>1</sup> Treatment of bladder PMM is based on invasiveness of the tumor, patients' tolerance to the treatment plan, and their comorbidities. According to Pfail et al., in non-muscle invasive tumors, the gold standard treatment is TURBT plus intravesical BCG.<sup>3</sup> Other treatment options include radiotherapy, chemotherapy, radical or partial cystectomy; however, it has been reported that radical cystectomy doesn't significantly affect the survival rate.<sup>3,5</sup> Other choices for immunotherapy include ipilimumab, interleukin 2, and targeting the PD1/PDL1 axis.<sup>3</sup> Further investigations are needed to identify the best treatment plan.

### 4. Conclusion

Recurrent PMM of the urinary bladder is extremely rare. Symptoms include hematuria and irritative LUTS. Diagnosis is made with cystoscopy and TURBT. Tumor markers can be identified with immunohistochemistry studies. The main treatment plan is resection via TURBT plus adjuvant therapies. Due to its rare incidence and lack of data, risk factors and the ideal treatment are yet to be found.

### Funding

The authors did not receive grant from funding agencies for this paper.

### Declaration of competing interest

The authors have no conflict of interest to declare.

### References

1. Snajdar E, Ajo AR, Rosen K, et al. Primary malignant melanoma of the urinary bladder. *Cureus*. 2021;13(3), e14067.
2. Singh V, Gupta K, Dewana S, et al. Spotting the pigmented 'Monster': primary melanoma in urinary bladder. *BMJ Case Rep*. 2019;12(12), e231950.
3. Pfail JL, Katims AB, Alerasool P, et al. Immunotherapy in non-muscle-invasive bladder cancer: current status and future directions. *World J Urol*. 2021;39(5): 1319–1329.
4. Karabulut YY, Erdogan S, Sayar H, et al. Primary malignant melanoma of the urinary bladder: clinical, morphological, and molecular analysis of five cases. *Melanoma Res*. 2016;26(6):616–624.
5. Venyo AK. Melanoma of the urinary bladder: a review of the literature. *Surg Res Pract*. 2014;2014:605802.