

Comparative Evaluation of Three Different Materials: Mineral Trioxide Aggregate, Triple Antibiotic Paste, and Abscess Remedy on Apical Development of Vital Young Permanent Teeth

Abstract

Aims: The aim of the study is to compare the success rate of mineral trioxide aggregate (MTA), Triple antibiotic paste, and Abscess remedy in apical development of vital young permanent teeth.

Subjects and Methods: A total of 60 children aged 6–14 years were selected and were randomly divided into three groups, each comprising of 20 children. Group I, Group II, and Group III in which MTA (Pro root), triple antibiotic paste (3Mix MP), and Abscess remedy (Product Dentaire, Switzerland) was used pulpotomy medicament. The children were recalled 1, 6, 9, 12, 18, and 24 months for clinical and radiographic evaluation and were designed as single-blinded randomized clinical trial. **Statistical Analysis Used:** Chi-square test. **Results:** The follow-up evaluations revealed that 56 teeth appeared to be clinically and radiographically successful at 24 months' postoperative evaluation. Four teeth treated with Abscess remedy reported pain and periapical lesion.

Conclusions: Overall success rate for all the material was 93%, MTA and Triple antibiotic paste have shown 100% success rate, and Abscess remedy has shown 80% success rate.

Keywords: Abscess remedy, apical development, mineral trioxide aggregate, pulpotomy, triple antibiotic paste, vital young permanent teeth

Introduction

Dental trauma and caries pose the greatest challenge to the integrity of the developing teeth which untreated may result in irreversible pulpal damage, eventually causing necrosis of the pulp or arrested root development as a result of which long-term tooth retention in the oral cavity will be affected.^[1-4] Although vital pulp capping and pulpotomy procedures of carious and traumatically exposed pulps in mature permanent teeth remain controversial, it is universally accepted that vital pulp therapy is the treatment of choice for immature teeth (incompletely developed apices). Pulpotomy is one of the most widely used techniques in vital pulp therapy for primary and young permanent teeth with carious and traumatic pulp exposure.

The primary objective in the management of exposed vital pulp of immature teeth is to create an environment to maintain the vitality and subsequently continue the root development and apical closure termed as

Apexogenesis. Preservation of pulp vitality is of paramount importance because vital functioning pulp is capable of initiating several reparative mechanisms to protect the tooth from bacterial invasion.^[5]

Historically, a number of materials have been advocated to induce normal root development. Since decades calcium hydroxide has been used to maintain the pulp vitality but, there are some undesirable side-effects associated with this medicament.^[6]

Hence, various alternative materials were introduced to overcome the disadvantages of calcium hydroxide which includes Ledermix paste, mineral trioxide aggregate (MTA), Pulpotec and Calcium enriched mixture, and MTA (Proroot). Currently, it is one of the most commonly used material for pulpotomy in immature teeth. As it has excellent antimicrobial properties, good compressive strength, biocompatible with adjacent tissues, excellent marginal adaptation, and sealing ability.^[7]

Triple antibiotic paste and Abscess remedy (Produits Dentaire) are the upcoming

Hanmanth Reddy Eppa, Ravindar Puppala¹, Balaji Kethineni¹, Sunitha Banavath², Pratej Kiran Kanumuri³, Gangamolu Venkateshwara Sai Kishore

Pedodontics and Preventive Dentistry, Meghna Institute of Dental Sciences, Nizamabad, ¹Pedodontics and Preventive Dentistry, SVS Institute of Dental Sciences, Mahabubnagar, ²Pedodontics and Preventive Dentistry, Balaji Dental College, Ranga Reddy, ³Pedodontics and Preventive Dentistry, Panineeya Institute of Dental Sciences, Hyderabad, Telangana, India

Address for correspondence:
Prof. Pratej Kiran Kanumuri,
Panineeya Institute of
Dental Sciences, Hyderabad,
Telangana, India.
E-mail: pratejkiran@gmail.com

Access this article online

Website:

www.contempclindent.org

DOI: 10.4103/ccd.ccd_587_17

Quick Response Code:



How to cite this article: Eppa HR, Puppala R, Kethineni B, Banavath S, Kanumuri PK, Kishore GV. Comparative evaluation of three different materials: Mineral trioxide aggregate, triple antibiotic paste, and abscess remedy on apical development of vital young permanent teeth. *Contemp Clin Dent* 2018;9:158-63.

This is an open access journal, and articles are distributed under the terms of the Creative Commons Attribution-NonCommercial-ShareAlike 4.0 License, which allows others to remix, tweak, and build upon the work non-commercially, as long as appropriate credit is given and the new creations are licensed under the identical terms.

For reprints contact: reprints@medknow.com

materials which are available for disinfection of root canals. Triple antibiotic paste is the combination of ciprofloxacin, minocycline, and metronidazole; it has been used to disinfect canals in revascularization procedures.^[8] Abscess remedy (Cresol, Polyoxymethylene, Oil of cinnamon, and Excipient ad) is a new radiopaque bactericidal paste; it is indicated in the treatment of 4th degree caries (lesions involving the pulp) and temporary filling of the infected root canal. Literature regarding the use of triple antibiotic paste and Abscess remedy as pulpotomy agents in immature teeth is scanty.

The objective of this study is to evaluate the success rate of triple antibiotic paste and Abscess remedy and MTA as pulpotomy agents of immature vital young permanent teeth.

Subjects and Methods

This study was conducted on children who had attended the outpatient Department of Pedodontics and Preventive Dentistry, Sri Venkata Sai Institute of Dental Sciences, College and Hospital, Mahabubnagar, Andhra Pradesh. A total of 60 children aged between 6 and 14 years were selected based on the following criteria: vital teeth with Deep caries, absence of spontaneous pain, absence of tenderness, absence of swelling, and hemorrhage from the amputation site controlled with wet cotton pellet ≤ 5 min. Radiographically, incomplete development of roots, no furcal and periapical radiolucency (Open apices). The samples were divided into three groups Group I, Group II, and Group III Which were treated with three different medicaments.

Triple antibiotic paste composition

Powder

- Ciprofloxacin 200 mg
- Metronidazole 500 mg
- Minocycline 100 mg.

Liquid

- Macrogol
- Propylene glycol.

Preparation of 3 mix paste

- Removed sugar coating on tablets and capsules were opened
- Crushed individually in separate mortars and mixed in equal amounts, i.e., 1:1:1

- 3Mix Powder is mixed with Macrogol and propylene glycol in 7:1 ratio to make it into the paste form.

After ethical committee approval and taking consent form from parents, we have done electric pulp tester to know the vitality of tooth. The test cavity preparation was made by drilling through the enamel-dentine junction using slow speed handpiece without water coolant in unanesthetized tooth with good isolation; then, tooth was anesthetized with 2% lidocaine with 1:800,000 epinephrine was administered. Access opening done with a diamond burs. Coronal pulp was excavated using spoon excavator and gently irrigated with normal saline and cotton pellet soaked in saline was applied to achieve the hemostasis, then respective medicaments were placed in the coronal orifices of root canal in all three groups. Teeth were sealed with intermediate restorative material, and postoperative radiographs were taken. Patients were recalled after 1 week, clinical signs and symptoms were checked. Intermediate restorative material was replaced by Fuji 9 Glass ionomer cement, and a semi-permanent restoration was done with stainless steel crowns. Patients were recalled at 1, 6, 9, 12, 18, and 24 months interval for clinical and radiographic examination.

Findings were noted, tabulated, and subjected to statistical analysis using Chi-square test.

Results

Evaluation of success was based on clinical and radiographic criteria. Clinically, teeth were considered to be successful in the absence of pain, swelling or abscess, draining fistula mobility and tenderness. Recall after 1, 3, 6, 9, 12, 18, and 24 months showed no failures except four cases in Group III (Abscess remedy) reported with pain and tenderness.

Radiographically, teeth were considered to be successful when there is the presence of continual dentinal deposition, root growth, apical closure, and absence of periapical radiolucency. Recall after 24 months showed no failures except four cases in Group III (Abscess remedy) showed periapical radiolucency [Figure 1a-c]. Root growth was observed after 3 months only in Group I (MTA); and after 24 months of follow-up, root growth was significant for Group I (MTA) [Figure 2a-c], and it was also seen in all

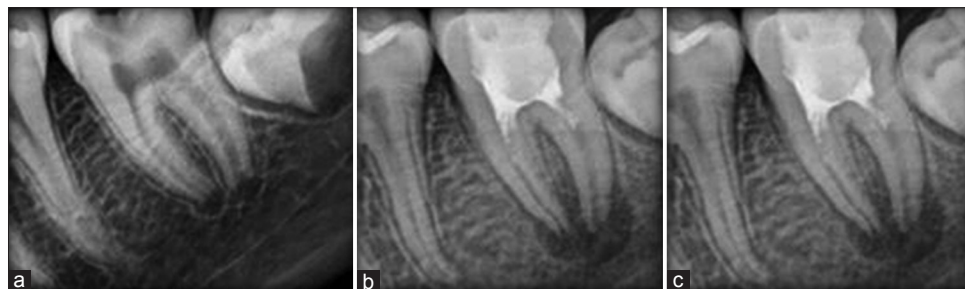

Figure 1: (a-c) Failure of Abscess remedy

cases of Group II (Triple Antibiotic Paste) [Figure 3a-c], and 16 out of 20 cases of Group III (Abscess Remedy group) [Figure 4a-c].

The clinical success rates of Group I (MTA) and Group II (triple antibiotic paste) at 24 months was 100% and the Abscess Remedy group showed a clinical success rate of 80%. The radiographic success rates of Group I (MTA) and Group II (Triple Antibiotic Paste) at 24 months was 100%, and the Abscess remedy group showed a clinical success rate of 80%. Statistical analysis revealed a significant difference between Group I and Group II with Group III regarding clinical and radiographic success. $P = 0.127$ ($P < 0.05$) [Tables 1 and 2].

Discussion

Young permanent molars are more prone to dental caries and anterior teeth are prone to trauma in an active young child. Pulpal exposures to trauma or dental caries require prompt and suitable treatment to ensure viability and vitality of pulp and periradicular cells. Pulpotomy in a young permanent tooth with open apices is a procedure aimed

at removing the coronal pulp and maintaining the vital radicular pulp to ensure a normal root end development and to ensure a root to crown ratio that supports the functional load on the tooth in treatment. Various materials have been tried to treat vital teeth with open apices, with the aim of introducing material that does not damage radicular pulp and allow the continuation of root development.

It is well established that dental pulp healing is directly related to the properties of the capping material. These include sealability, antimicrobial activity, and more significantly induction of dentine formation, i.e., bioregeneration.^[6] In the present study, 60 immature teeth were selected in children aged between 6 and 14 years according to the clinical and radiographic criteria based on previous studies.^[9-12]

Isolation of teeth to prevent contamination plays a key role in the success of any pulp treatment;^[9] hence, all cases were performed after isolation with rubber dam. As pulpotomy is indicated in vital teeth vitality test was done using electric pulp tester, and test cavity preparation was made on

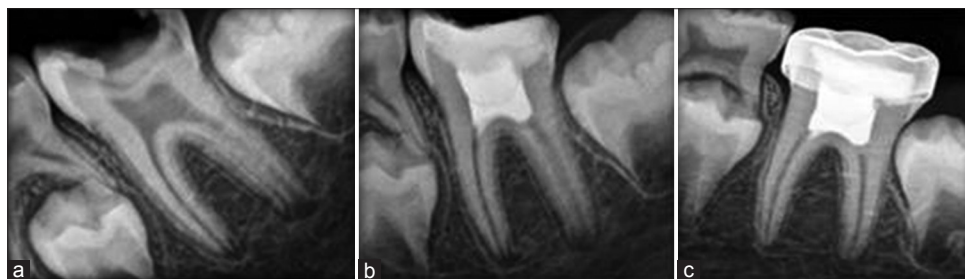


Figure 2: (a-c) Group I mineral trioxide aggregate

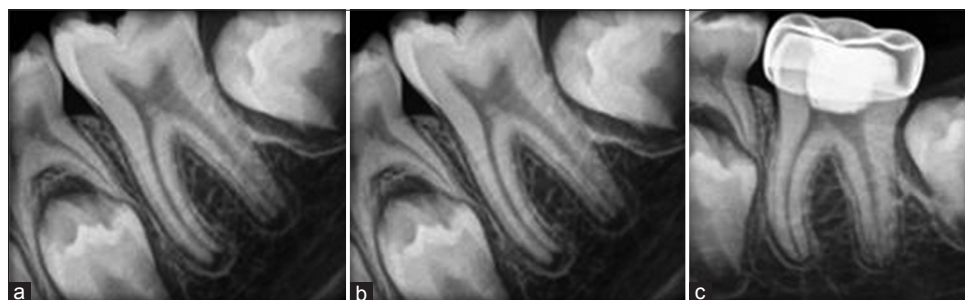


Figure 3: (a-c) Group II Triple Antibiotic paste

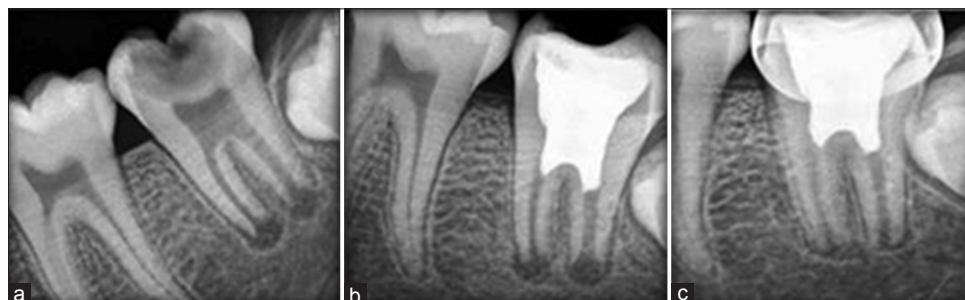


Figure 4: (a-c) Group III: Abscess remedy paste

Table 1: Postoperative overall clinical evaluation

	1 month		3 months		6 months		9 months		12 months		18 months		24 months		Grand total	
	n	Success in percentage	n	Success in percentage	n	Success in percentage	n	Success in percentage	n	Success in percentage	n	Success in percentage	n	Success in percentage	n	Success in percentage
Group I	20	100	20	100	20	100	20	100	20	100	20	100	20	100	20	100
Group II	20	100	20	100	20	100	20	100	20	100	20	100	20	100	20	100
Group III	20	100	16	80	16	100	16	100	16	100	16	100	16	100	20	80

P=0.127 (P<0.05)

Table 2: Postoperative overall radiographic evaluation

	3 months		6 months		9 months		12 months		18 months		24 months		Grand total	
	n	Success in percentage	n	Success in percentage	n	Success in percentage	n	Success in percentage	n	Success in percentage	n	Success in percentage	n	Success in percentage
Group I	20	100	20	100	20	100	20	100	20	100	20	100	20	100
Group II	20	100	20	100	20	100	20	100	20	100	20	100	20	100
Group III	20	80	16	100	16	100	16	75	16	100	16	100	20	80

P=0.127 (P<0.05)

unanesthetized tooth.^[13] Hemostasis in <5 min after coronal pulp amputation is considered a significant variable in the results of pulpotomies in primary molars.^[14] We selected those teeth in which hemostasis was achieved <5 min. After achieving hemostasis MTA, triple antibiotic paste and Abscess Remedy were placed over the radicular pulp stumps according to the manufacturer’s instructions in the teeth allocated to respective groups. After placement of the material, all pulpotomized teeth were restored with intermediate restorative material.^[15]

In the subsequent visit, intermediate restorative material was replaced with Type 9 Glass ionomer cement followed by stainless steel crown (extracoronary restoration)^[16,17] which has good sealing properties, high compressive strength, and that impart adequate retention compared to normal restoration.

Postoperative radiographs were taken in the same appointment as a reference. The patients were recalled on 1st, 3rd, 6th, 9th, 12th, and 24th month intervals and pulpotomized teeth were clinically and radiographically evaluated based on previous studies.^[18]

According to study done by El-Meligy and Avery, pulpotomy in immature permanent teeth followed for 1 year^[19] clinically and radiographically showed significant results. Thus, 24 months’ follow-up (clinically and radiographically) was considered for the present study.

MTA has shown 100% clinical and radiographic success rates in apexogenesis as it has excellent antimicrobial activity and capability of forming the dentin bridge.^[20] Triple antibiotic paste and abscess remedy maintain the aseptic environment as they have antimicrobial activity and cresol present in Abscess remedy acts as a fixative, so by considering the advantages, these two materials were chosen and compared with MTA.

In the present study, MTA and triple antibiotic paste showed 100% clinical success, as all the teeth included in these two groups did not show any clinical signs and symptoms during 24 months intervals. Whereas the Abscess remedy group has shown 80% success rate and four teeth (20%) developed pain and tenderness. Radiographic follow-up examinations revealed that changes in apex were seen in all the cases treated by MTA, triple antibiotic paste, and sixteen of twenty cases of Abscess Remedy groups. However, amount of the root development varied, it was more significant for MTA group. Remaining four teeth in Abscess Remedy group developed the periapical radiolucency.

In MTA group, there was high clinical and radiographic success rate which is correlating with the previous studies. Aeinehchi *et al.* evaluated the use of MTA and calcium hydroxide as pulp capping materials in immature maxillary third molars of patients 20–25 years old. Histological examination after extraction indicated that teeth treated

with MTA had less inflammation and necrotic pulp and thicker dentin walls compared to calcium hydroxide.^[21]

El-Meligy and Avery, compared calcium hydroxide and MTA as a pulpotomy agents in young permanent teeth in which 100% success rate was seen in MTA group and 87% in calcium hydroxide group.^[19]

The success rate in triple antibiotic paste group was also 100% that could be because of its excellent antimicrobial property and the lesion sterilization and tissue repair activity. A good seal after placing the medicament was obtained with glass ionomer cement which was followed by stainless steel crown. Hence, the high success of triple antibiotic paste could be attributed to its excellent antimicrobial property and the good seal obtained by a semi-permanent restoration.

Abscess remedy has also shown good success rate which is comparable to MTA and triple antibiotic paste. Root growth was seen in sixteen out of twenty cases of this group, remaining four cases developed periapical lesion. There could be two reasons for the failure in these four cases, one is inaccurate diagnosis at the time of the treatment and second reason could be the absence of a standardized pressure application for the medicament which could have led to the diffusion of the material into the radicular pulp. However, the usage of Abscess Remedy is advisable when compared to formocresol because of the minimal concentration of formaldehyde as recent research about formaldehyde metabolism, pharmacokinetics, and carcinogenicity indicate that formaldehyde is probably a potent human mutagen.^[22]

Conclusions

The three materials MTA, triple antibiotic paste, and Abscess Remedy showed successful results both clinically and radiographically. When certain factors such as cost of the medicament, ease of manipulation of the material were considered triple antibiotic paste appeared to be superior to MTA and Abscess Remedy. Abscess remedy also shown good success rate which is comparable to MTA and triple antibiotic paste but limited pressure should be applied over the medicament as the consistency of the material is thin.

On the basis of the present study, the three materials MTA, triple antibiotic paste, and Abscess remedy were found to be comparable in the overall success rate in pulpotomized teeth. There was statistically significant difference between Group I and Group II with Group III. In further endeavors, lot of research is needed to confirm the success of triple antibiotic paste and Abscess remedy as a pulpotomy agent for which long-term follow-up over a larger sample size has to be evaluated.

Financial support and sponsorship

Nil.

Conflicts of interest

There are no conflicts of interest.

References

- Robertson A, Andreasen FM, Andreasen JO, Norén JG. Long-term prognosis of crown-fractured permanent incisors. The effect of stage of root development and associated luxation injury. *Int J Paediatr Dent* 2000;10:191-9.
- Rabie G, Trope M, Tronstad L. Strengthening of immature teeth during long-term endodontic therapy. *Endod Dent Traumatol* 1986;2:43-7.
- Katebzadeh N, Dalton BC, Trope M. Strengthening immature teeth during and after apexification. *J Endod* 1998;24:256-9.
- Cvek M. Prognosis of luxated non-vital maxillary incisors treated with calcium hydroxide and filled with gutta-percha. A retrospective clinical study. *Endod Dent Traumatol* 1992;8:45-55.
- Cohen S, Bums RC, editors. *The Role of Endodontics After Dental Traumatic Injuries in Pathways of the Pulp*. 9th ed. St.Louis: Mosby; 2005. p. 616-8.
- Accorinte Mde L, Holland R, Reis A, Bortoluzzi MC, Murata SS, Dezan E Jr, *et al.* Evaluation of mineral trioxide aggregate and calcium hydroxide cement as pulp-capping agents in human teeth. *J Endod* 2008;34:1-6.
- Rao A, Rao A, Shenoy R. Mineral trioxide aggregate – A review. *J Clin Pediatr Dent* 2009;34:1-7.
- Miller EK, Lee JY, Tawil PZ, Teixeira FB, Vann WF Jr. Emerging therapies for the management of traumatized immature permanent incisors. *Pediatr Dent* 2012;34:66-9.
- Kabaktchieva R, Gateva N. Vital pulpotomy in primary teeth with mineral trioxide aggregate (MTA). *JIMAB* 2009;2:102-8.
- Ghoddusi J, Shahrani F, Alizadeh M, Kianoush K, Forghani M. Clinical and radiographic evaluation of vital pulp therapy in open apex teeth with MTA and ZOE. *N Y State Dent J* 2012;78:34-8.
- Agamy HA, Bakry NS, Mounir MM, Avery DR. Comparison of mineral trioxide aggregate and formocresol as pulp-capping agents in pulpotomized primary teeth. *Pediatr Dent* 2004;26:302-9.
- Inoue H, Muneyuki H, Izumi T, Taguchi K, Nishigawa Y, Watanabe K, *et al.* Electron microscopic study on nerve terminals during dentin bridge formation after pulpotomy in dog teeth. *J Endod* 1997;23:569-71.
- Gopikrishna V, Pradeep G, Venkateshabu N. Assessment of pulp vitality: A review. *Int J Paediatr Dent* 2009;19:3-15.
- Tunç ES, Saroğlu I, Sari S, Günhan O. The effect of sodium hypochlorite application on the success of calcium hydroxide pulpotomy in primary teeth. *Oral Surg Oral Med Oral Pathol Oral Radiol Endod* 2006;102:e22-6.
- Guelmann M, McIlwain MF, Primosch RE. Radiographic assessment of primary molar pulpotomies restored with resin-based materials. *Pediatr Dent* 2005;27:24-7.
- Moretti AB, Sakai VT, Oliveira TM, Fornetti AP, Santos CF, Machado MA, *et al.* The effectiveness of mineral trioxide aggregate, calcium hydroxide and formocresol for pulpotomies in primary teeth. *Int Endod J* 2008;41:547-55.
- Naik S, Hegde AH. Mineral trioxide aggregate as a pulpotomy agent in primary molars: An *in vivo* study. *J Indian Soc Pedod Prev Dent* 2005;23:13-6.
- Caicedo R, Abbott PV, Alongi DJ, Alarcon MY. Clinical, radiographic and histological analysis of the effects of mineral trioxide aggregate used in direct pulp capping and pulpotomies of primary teeth. *Aust Dent J* 2006;51:297-305.

19. El-Meligy OA, Avery DR. Comparison of mineral trioxide aggregate and calcium hydroxide as pulpotomy agents in young permanent teeth (apexogenesis). *Pediatr Dent* 2006;28:399-404.
20. Okiji T, Yoshida K. Reparative dentinogenesis induced by mineral trioxide aggregate: A review from the biological and physicochemical points of view. *Int J Dent* 2009;2009:464280.
21. Aeinehchi M, Eslami B, Ghanbariha M, Saffar AS. Mineral trioxide aggregate (MTA) and calcium hydroxide as pulp-capping agents in human teeth: A preliminary report. *Int Endod J* 2003;36:225-31.
22. Milnes AR. Is formocresol obsolete? A fresh look at the evidence concerning safety issues. *J Endod* 2008;34:S40-6.