

Original Article

Is “mini-invasive” technique for iliac crest harvesting an alternative to cervical cage implant? An overview of a large personal experience

Aldo Spallone^{1,2}, Chiara Izzo¹, Stefania Galassi³, Massimiliano Visocchi⁴

¹Section of Neurosurgery, Departments of Clinical Neurosciences, N.C.L. Neurological Center of Latium, ²Biopathology, Institute of Anatomical Pathology, Tor Vergata University of Rome, ³Ospedale Pediatrico Bambino Gesù, IRCCS, Department of Diagnostic Imaging, Unit of Neuroradiology, ⁴Institute of Neurosurgery, Catholic University of Rome, Italy

E-mail: *Aldo Spallone - segreteria1@nclroma.it; Chiara Izzo - chiara.izzo@nclroma.it; Stefania Galassi - stefaniagalassi@gmail.com; Massimiliano Visocchi - massimiliano.visocchi@rm.unicatt.it

*Corresponding author:

Received: 18 June 13 Accepted: 10 September 13 Published: 17 December 13

This article may be cited as:

Spallone A, Izzo C, Galassi S, Visocchi M. Is "mini-invasive" technique for iliac crest harvesting an alternative to cervical cage implant? An overview of a large personal experience. *Surg Neurol Int* 2013;4:157.

Available FREE in open access from: <http://www.surgicalneurologyint.com/text.asp?2013/4/1/157/123202>

Copyright: © 2013 Spallone A. This is an open-access article distributed under the terms of the Creative Commons Attribution License, which permits unrestricted use, distribution, and reproduction in any medium, provided the original author and source are credited.

Abstract

Background: Autograft bone provides an excellent substrate for multilevel arthrodesis after anterior discectomy and is inexpensive. However, the use of tricortical bone could increase the discomfort for the patient.

Methods: We reviewed cases of cervical disc diseases operated on by a single neurosurgeon (AS), within the period June 2000-December 2011. A total of 221 patients were considered for the present study; 109 female, 112 male, averaging 49 years of age. Only patients who could be followed up for at least one year were included in the present study. The grafts obtained with the technique described are bi- (and not tri-) cortical, and always of sufficient size in order to fit two spaces if necessary.

Results: The technique is not associated with long-term significant donor site pain except for a striking minority of patients, it shortens the hospital stay, it offers comparable results to the published surgical series in which cage and/or modern implants are used.

Conclusions: Autograft bone can be reasonably considered as one of the possible alternatives to be used in the surgical management of cervical disk disease.

Key Words: Autograft, anterior cervical approach, cervical cage, donor site pain

**Access this article
online****Website:**

www.surgicalneurologyint.com

DOI:

10.4103/2152-7806.123202

Quick Response Code:

INTRODUCTION

The recent introduction of new prosthetic material has raised the problem about the best policy option to performing a cervical fusion. The major argument against the use of autografts is pain at the donor site, which would affect up to one-third of the patients undergoing a tricortical bone graft harvesting.^[28] The cause was attributed to a combination of several factors, including

emotional instability and muscular and/or periosteal stripping.^[12]

In contrast, we must be aware that the world economy is changing and that the global financial crisis is progressively impairing the health organization systems efficiency and reducing the related expenses worldwide. Nowadays, as matter of fact, to promote cost-saving strategies has become a topic of utmost importance.

Therefore our effort was to develop a safe and painless “mini-invasive” technique for harvesting iliac crest bone to be used for anterior interbody fusion. This technique, which has been previously described by our group, provides bicortical autografts of sufficient size to be used in multilevel cervical fusion procedures.^[35] We report our experience with 221 consecutive patients undergone cervical interbody fusion by using this technique.

PATIENTS AND METHODS

Clinical material

We reviewed cases of cervical disc disease operated on by a single neurosurgeon (AS), within the June 2000-December 2011 period. Only patients who could be followed up for at least one year were included in the present study.

A total of 221 patients were considered for the present study; 109 female, 112 male, averaging 49 years of age (24-84 years). All of them failed conservative treatment, consisting, as a rule, of neck immobilization and sessions of careful neck traction. Most patients showed symptoms and signs of radicular dysfunction, refractory to conservative management. Ninety-two patients presented with severe cervical spinal stenosis and related myelopathy. Cases necessitating surgery for posttraumatic cervical myelopathy were only occasional. Most cases were two-level cases. One-level fusion was performed in a minority of cases (67 patients), as a rule, in those in whom removal of significant osteophytic spurs had made subsequent fusion mandatory. Three-level fusion was performed only occasionally along with plating; for this specific reason these cases were excluded from the present study. [Table 1] summarizes the operated levels (345 levels in 221 patients).

Surgical technique

The surgical technique has been extensively reported in our previous paper.^[35] A standard microsurgical Smith–Robinson anterior cervical discectomy is performed.^[33] Great care is taken in removing the osteophytes up to both neural foramina in each operated interspace by a high-speed drill. Bicortical bone grafts are harvested by using a limited skin incision (+5 cm); careful dissection of the muscles from the posterior aspect of the ilium and oblique bone cuts leaving the anterior thigh musculo-tendineous attachments undisturbed are performed [Figure 1]. The skin incision is made parallel and 2 cm superior to the edge of the crest, in order to zero the possibility of injuring the ilioinguinal nerve and a careful dissection of the subcutaneous tissue is then performed in order to visualize properly the tendineous attachments of the iliac muscle. Subsequently, the fascia is incised, properly held open by using four sutures, which can be stapled firmly in the sterile area out of the operative field; the underneath muscle is dissected

Table 1: Operated interspaces

Level	N	%
C3-C4	43	12.5
C4-C5	66	19.1
C5-C6	147	42.6
C6-C7	84	24.4
C7-T1	5	1.4
Total	345	100

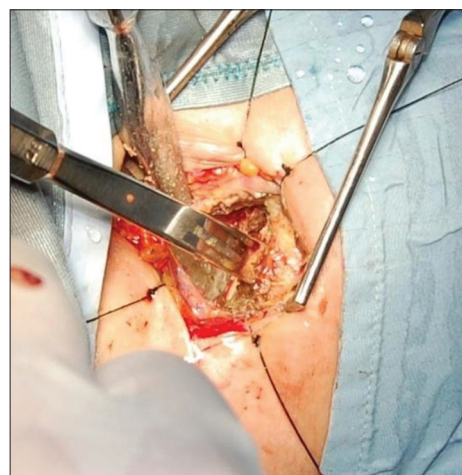


Figure 1: Iliac crest harvesting. An obliquely directed osteotome is used for completing the bone dissection, while an assistant holds away from the bone the iliac muscle using a curved osteotome. The anterior musculo-ligamentous attachments are not disturbed

only from the posterior aspect of the iliac crest using a periosteal elevator. Only bipolar cautery is used during the entire surgical procedure. An assistant holds the iliac muscles away from the bone by using a curved periosteal elevator; when the iliac bone is properly exposed and the field is dry, an obliquely directed sequential drilling is performed within the iliac crest in a posterior-to-anterior direction, which draws almost a rectangle in the posterior surface of the ilium. Great care is taken not to traumatize the anterior musculo-tendineous attachments of the crest. Occasionally, a particularly hypertrophic iliac muscle requires further dissection in order to visualize the minimum required space of the crest; also this maneuver is performed using the bipolar cautery. When the sequential drilling is completed, a straight osteotome (Stille®) is used for completing the bone dissection within the iliac crest and the graft is gently elevated from the iliac bone in order to avoid undue fracturing. The grafts obtained in this manner are bi- (and not tri-) cortical, and always of sufficient size in order to fit two spaces if necessary. In such a case, the graft is divided in two pieces using a hand-held minisaw, and appropriately shaped using either a drill or a small osteotome [Figure 2], in order to fit conveniently for the operated interspaces, under fluoroscopic guidance. We attempted to correct kyphosis, as much as possible, when

present preoperatively and, as a rule, to increase only slightly the disc height in the cases while maintaining the physiological lordosis [Figure 3a and b]. The latter maneuver was conceived as a possible preventive measure against the risk of adjacent space disease due to over distraction of operated space. Extra-time for autograft extraction, preparation, and plugging averaged 18 minutes.

Evaluation of surgical results

Objective evaluation was based on both clinical and radiological criteria. Examination of the patients was conducted by two authors (CI and MV) who had not been directly involved in the management of the present cases, using either the clinical charts (available in all the cases) or examining directly the patients (102 cases). A preoperative and 3 and 12 months postoperative Prolo scale [Table 2] was used for comparative evaluation in each patient. Postoperative results were rated as excellent, good, fair, or poor according to Prolo scale scoring.^[25] In addition, we also recorded the working capacity following surgery.

Table 2: Prolo scale

Points outcome
E1 Complete invalid
E2 No gainful occupation
E3 Able to work, but not at previous occupation
E4 Working at previous occupation on part-time or limited status
E5 Able to work at previous occupation with no restrictions of any kind
F1 Total incapacity (or worse than before operation)
F2 Mild-to-moderate level of neck pain and/or brachialgia
F3 Low level of pain and able to perform all activities except sports
F4 No pain, but patient has had one or more recurrence of neck pain and/or brachialgia
F5 Complete recovery, no recurrent episodes of neck pain, able to perform all previous sports activities

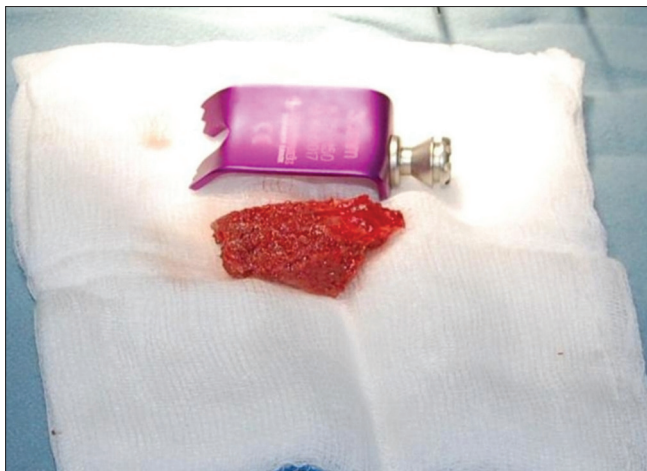


Figure 2: The harvested graft is divided in two pieces and appropriately shaped using either a small osteotome or a drill

At least two postoperative X-ray films, one early (average 3 days) and one late (average 2.7 months), were available for evaluation and comparison with the preoperative ones in all the patients. These films were reviewed blindly by one author (SG), unaware of the clinical situation of the patient. Kyphosis was evaluated using the sagittal angle measurement method as described by Steinmetz *et al.*^[36] Disc height was also measured as described by Payer *et al.*^[23] We did not measure the cross-sectional foraminal area, as this method would not indicate reliably the real space that would accommodate cervical roots following an anterior surgical procedure.^[26] Fusion was considered to be achieved when bony trabeculae were observed at the 3-month radiographic control. Failure to observe fusion at this postoperative interval was the reason for recommending the patient to prolong the rigid collar regime, as well as a later control X-ray imaging. In these cases, films were obtained at an average interval of 10.5 months. Failure to observe bony trabeculae as well as motion of the interspaces operated at a late flexion-extension X-rays follow-up, led us to diagnose postoperative lack of fusion.

Evaluation of the donor site pain

The patients were evaluated at discharge, at the first follow-up control (one month postoperatively), and either by a further clinical follow-up or by telephone interview. This latter was performed at an average interval of 46 months following surgery (range 12-72 months). The visual analogue scale (VAS) was used for scoring subjective pain from 1 (no pain) to 10 (pain requiring narcotic analgesics as defined by the authors).^[20]

Statistical analysis

Pre- and postoperative data were compared using a paired Students test. A $P < 0.05$ was considered statistically significant. Postoperative clinical and radiological data

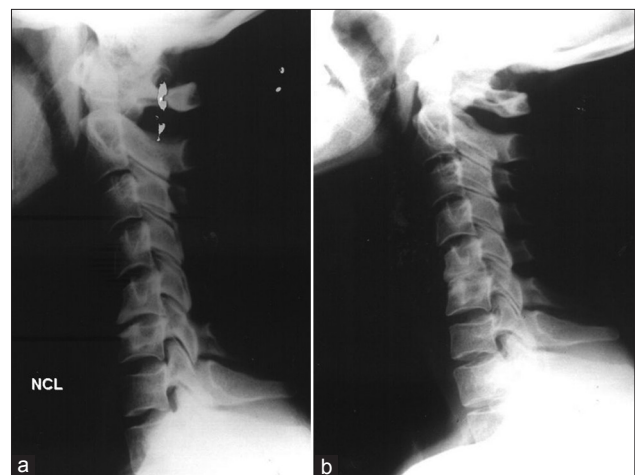


Figure 3: (a) Preoperative X-rays of a patient submitted to C5-C6-discectomy. Autografting was performed due to significant osteophytes removal. (b) Postoperative 2.5 months control shows improved spine alignment

were also matched using the Chi-square test (χ^2) for statistical significance.

RESULTS

All patients were ambulant within 24 hours from surgery. They were discharged, as a rule, in the fifth postoperative day, only to check for possible local wound complications. Our present day routine has been changed afterward. None was readmitted for iliac crest wound complications.

Clinical results

No patient exhibited immediate postoperative worsening. One case presented postoperative hoarseness, which regressed after 4 months. There were two cases (C5-C6 and C6-C7 fusion) of graft anterior dislodgement diagnosed at the early postoperative X-ray control.

One patient was asymptomatic and was not reoperated. The two operated segments fused later with some kyphosis, however, the patient remained asymptomatic for almost 2 years after surgery. The other case required surgical revision for dysphagia. The malposition of the lower graft compressing the esophagus is shown in [Figure 4]. The patient subsequently recovered. One case showed signs of increased myelopathy and neck pain at an 8-month follow-up following an initial satisfactory clinical course after a C5-C6, C6-C7 interbody fusion. Another patient submitted to C3-C4, C4-C5 procedure complained of long-term postoperative neck pain, which subsided following revision surgery with plating 10 months later, when lack of fusion and instability was considered to be the cause of its problem. Control plain X-rays showed graft subsidence with an increased kyphosis at the upper operated segment [Figure 5a]; in this case, a definite improvement followed reoperation with anterior plating [Figure 5b]. Another patient, who had been submitted to a two-level interbody fusion, underwent

further surgery (2 years later) for symptomatic cervical disc disease occurring to adjacent previously nonoperated level. Interestingly, a neck trauma was the common feature and symptoms reoccurred after an apparently successful initial surgery in both cases. The mean interval between the operations was 16 months.

Average Prolo scale spanned from 4.5 (SD + 1.2) preoperative to 7.1 (SD + 1.48) 3 months postoperative ($P < 0.05$). The 12-month postoperative Prolo scale averaged 8.2 (SD + 1.55), a value similar to the earlier follow-up scoring ($P > 0.1$). Out of the 172 patients working before operation, 159 (92.4%) resumed their jobs following surgery the remaining 49 patients were already retired at the time of surgery.

Late postoperative results were rated excellent in 132 cases (59.7%), good in 59 cases (26.7%), and fair in 30 cases (13.6%). There were no poor results.

X-ray evaluation

The sagittal angle spanned from -6.1° (SD + 1.2°) preoperative to 5.6° (SD + 1.3°) early postoperative. A total of 194 (87.8%) of patients maintained and/or recovered the physiological lordosis while 24 (10.9%) appeared to have a kyphotic cervical spine in the late postoperative X-ray control. Only three (1.3%) showed postoperatively, an angle of almost 0° . Disc height increased from 3.1 mm (SD + 0.4 mm) preoperatively to 4.1 mm (SD + 0.2 mm) early postoperatively and late postoperative data did not show relevant changes: 3.8 mm (SD + 0.1 mm). Fusion [Figure 6a-c] occurred in 213 cases (96.4%). Late fusion was noted in 16 (7.2%) cases at a later X-rays control (average 10.5 months). Lack of fusion was diagnosed in eight patients (3.6%) – all smokers – three of whom underwent reoperation. We did not find any statistical correlation between unsatisfactory postoperative radiographic appearance and postoperative

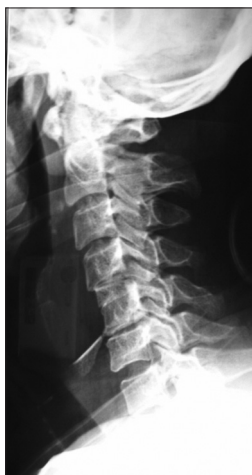

Figure 4: Early postoperative X-ray control of a patient undergoing C4-C5, C5-C6 interbody fusion. The lower graft is totally extruded. This was removed at revision surgery

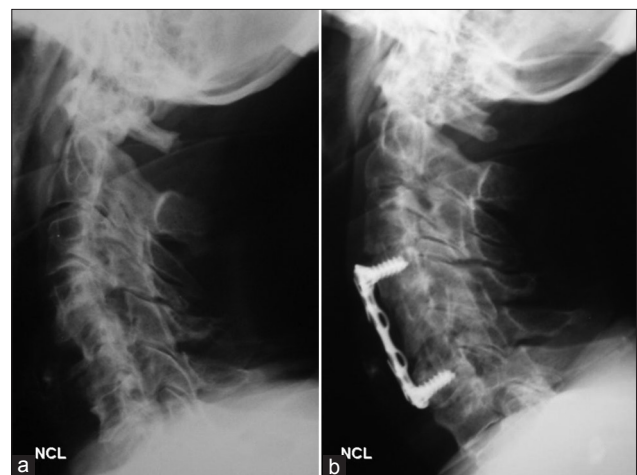


Figure 5: (a) Late (7.5 months) postoperative X-rays of a patient submitted to C5-C6, C6-C7 interbody fusion. The lower graft did not fuse, causing instability. (b) Following reoperation with anterior plating, a good alignment has been obtained

clinical results (χ^2 test $P > 0.1$).

Table 3 summarizes the dynamics in the evaluation of the clinical symptoms and plain X-ray investigations.

Donor site pain

In most of the patients, donor site pain disappeared within a week of surgery. There was one case of asymptomatic linear ilium fracture, which was treated with bandage restraining, and one case of late (3 weeks postoperative) femoral neuropathy occurring in an old lady who had complained in the past of several episodes of local tendonitis. The cause was attributed to subfascial blood infiltration, which would have later interfered with the femoral nerve vascularization. The symptoms of neuropathy regressed completely within 2 months. Interestingly, this lady had almost no pain following surgery.

In summary, at discharge, at an average of 5 days after surgery, 58 patients were pain-free at the donor site and average VAS was 2.6 (range 1-7, SD \pm 0.7). At the first follow-up control (average: 6 weeks postoperatively), 188 patients denied pain, while 197 (89.1%) declared to be pain-free at the telephone interview 12-72 months, average 46 months. The improvement in the VAS is

Table 3: Clinical and radiological results

Prolo scale* P<0.05	Preoperative		Postoperative			
			3 month		12 month	
	E	F	E	F	E	F
	3.3	1.2	3.6	3.5	4.1	4.1
	4.5 SD+1.2		7.1 SD+1.48		8.2 SD+1.55	
Cervical and/or radicular pain	N	%	N	%	N	%
	221	100.00	68	30.77	32	14.48
Mielopathy	92	41.63	84	38.01	70	31.67
Disk height	3.1 mm SD+0.4		4.1 mm SD+0.2		3.8 mm SD+0.1	

*Prolo Scale is illustrated in Table 2. SD: Standard deviation

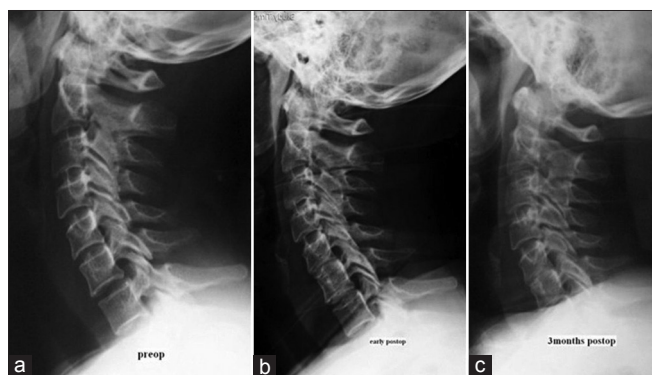


Figure 6: (a) Preoperative, (b) Early postoperative and (c) 3 months postoperative X-ray images of a patient submitted to C5-C6 interbody fusion. The spine alignment is maintained following operation. Fusion is eventually obtained

statistically significant ($P < 0.05$). Average VAS at the last follow-up was 1.3 (range 1-6, SD + 0.9). Only five patients scored 6 in their later donor site postoperative pain.

DISCUSSION

Anterior approach for the treatment of cervical degenerative disease has become very popular in the past five decades. The introduction of the operating microscope as well as the microtechniques has refined the technique originally described by Smith and Robinson.^[26,33] This has allowed achievement of satisfactory results in the vast majority of patients. However, great debate has always existed as to whether or not fusion would be necessary,^[1,3,8,13,24,31,32,34,37] and in the case fusion was considered necessary, which would be the best material for obtaining interbody fusion, whether autografts or allografts.^[5,6,18,19,21,27,32]

Cervical interbody fusion

The introduction of cage technology,^[2,18,23,29,30,36] and dynamic implants^[30,36] has appeared to allow the potential for solving most of the problems encountered with previous interbody fusion techniques.^[6,19,22] A recent study has indeed reported that persistent pain at the donor site when using iliac crest autografts (by far the most widely used autologous grafting material in spinal fusion surgery until few years ago) was not at all negligible, at least when using the traditionally recommended technique for obtaining a tricortical bone graft.^[7,16] This would be seen as a strong argument for promoting the use of cage and/or modern bioimplants technology in the treatment of surgery-requiring cervical discogenic disease,^[29,36] although significant new fusion technology cost should cause caution before considering it the gold standard. Moreover, there is evidence of possible long-term, not negligible complications when implementing disc prostheses.^[15,17] We want to stress that the relatively long length of stay following surgery in the present case material was only a precaution measure, which was not used in subsequently operated, more recent cases. Routine plating could have helped in reducing the risk of graft-related complications, as well as in shorting the postoperative wearing-collar period for the patient. However, this would have increased the costs of the procedure, rendered them practically equivalent to those of the cages, and cost reduction is one, although not the main one, clear advantage of the technique adopted in the present patients. In any case, the complications rate was definitely low in the present case material and the rate of ultimate fusion was high.

Graf harvesting technique

We previously described a “mini-invasive” technique for harvesting iliac crest transplants.^[35] The grafts obtained in this way were bicortical and of relatively small size;

however, large enough to fit conveniently in at least two cervical interspaces. Bicortical iliac grafts proved to be adequate as far postoperative fusion occurred in the early cases in which this technique was used. Therefore we introduced as a routine this “mini-invasive” harvesting technique and routine plating was considered unnecessary, as explained before.

Present case material

An obvious shortcoming of the present study lies in its retrospective nature and lack of direct comparison with other techniques for interbody fusion. However, the clinical results achieved in the present patients appeared to be comparable to those of most recent studies published in the literature where cage and/or modern plating technology had been used^[5,18,19,21,23,30,32,36] Unsatisfactory surgical results were reported in a striking minority of cases (12.7%) and a significant long-term donor site pain was a very minor issue (2.3% of present cases), as a likely result of the less traumatic technique used for graft harvesting. We observed graft extrusion in two cases, only one of which required removal of the extruded graft. Reoperation was also required in another case for symptomatic graft reabsorption and consequent spine subsidence. Another patient suffered from long-term postoperative neck pain, most likely due to lack of fusion and related instability, and underwent revision surgery 10 months later. This occurred early in the series and it was likely due to technical mistake. In reoperating these patients we used anterior plating in addition to iliac crest autotransplant in order to minimize the chance of subsequent, recurring, subsidence of the graft.

Another patient, after additional trauma, required additional surgery for disc extrusion at an adjacent level 2 years after an apparently successful two-level interbody fusion and was again reoperated successfully. In a large case material of patients submitted to cervical interbody fusion^[3] Kaiser *et al.*^[14] observed two cases of novel disc extrusion at another level, which required reoperation.

Radiological results would appear to be a little less comparable with published case material in which cage technology had been used.^[27] This can be also due to the cage radio lucency. However, the rate of fusion was high (96.4%) and the incidence of graft subsidence was consequently negligible. Moreover, all the eight nonfusion patients were smokers. Smoke is a well-known negative factor for bone grafting fusion.^[4,30] It should be stressed, as stated in the results section, that no statistical relationship was found between radiological and clinical results.

Economical aspect

In 2009, Epstein *et al.*^[10] analyzed the cost of implanted versus explanted devices utilized to perform 87 single-level anterior discectomy at a single institution. The total cages cost to the hospital was \$38,821 (range \$1720-\$7928), while obviously there was no device

associated cost with 14 iliac crest autografts. The high device cost was also associated with the surgeons learning curve, as demonstrated in a subsequent research by the same group, in which the device-failure-related redo surgery decreased significantly (from 45.5% to 16%) with increasing surgical team’s experience.^[9] In the restricted economic environment, we all are facing with in the world, a surgical technique which proves to be effective with less costs, needs to be considered a wise alternative to, though more largely used, techniques based on prosthetic technology. Such a philosophy, strongly suggested in developed countries, would be an almost obligatory strategy in developing countries, since the time consumed by surgery is definitely less important than the cost of the devices.^[11]

CONCLUSIONS

Autograft bone provides an excellent substrate for arthrodesis after anterior discectomy and is inexpensive. The use of tricortical bone could increase the discomfort for the patient. The graft harvesting technique described in the present paper is not associated with long-term significant donor site pain except for a striking minority of patients, it shortens the hospital stay, it offers comparable results to the published surgical series in which cage and/or modern implants and it can be reasonably considered as one of the possible alternatives to be used in the surgical management of cervical disk disease.

REFERENCES

- Abbott A, Halvorsen M, Dederig A. Is there a need for cervical collar usage post anterior cervical decompression and fusion using interbody cages? A randomized controlled pilot trial. *Physiother Theory Pract* 2013;29:290-300.
- Akula M, Taha M, Mathew B, O'Reilly G. The Plate cage Benezech implant as an alternative to discectomy bone graft in the treatment of cervical spondylosis: Clinical and functional outcome *Br J Neurosurg* 2008;22:542-5.
- Arts MP, Brand R, Van Den Akker E, Koes BW, Peul WC. The Netherlands Cervical Kinematics trial. Cost-effectiveness of anterior cervical discectomy with or without interbody fusion and arthroplasty in the treatment of cervical disc herniation; a double-blind randomised multicenter study. *BMC Musculoskelet Disord* 2010;11:122.
- Behrend C, Prasarn M, Coyne E, Horodyski M, Wright J, Rehtine GR. Smoking Cessation Related to Improved Patient-Reported Pain Scores Following Spinal Care. *J Bone Joint Surg Am* 2012;94:2161-6.
- Bose B. Anterior cervical fusion using Caspar plating: Analysis of results and review of the literature. *Surg Neurol* 1998;49:25-31.
- Buttermann GR, Glazer PA, Bradford DS. The use of bone allografts in the spine. *Clin Orthop Relat Res* 1996;324:75-85.
- Clark K. Anterior Operative Approach for Benign Extradural Cervical Lesions. In: Youmans JR, editor. *Neurological Surgery*. Vol. 2. Philadelphia, London, Toronto: WB Saunders Company; 1973. p. 1213-28.
- Dowd JC, Wirth FP. Anterior cervical discectomy: Is fusion necessary? *J Neurosurg* 1999;90 (1 Suppl):S8-12.
- Epstein NE, Schwall GS, Hood DC. Reducing the cost and frequency of explantations associated with single-level anterior discectomy and fusion at a single institution through education. *Spine* 2012;37:414-7.
- Epstein NE, Schwall GS, Hood DC. The incidence and cost of devices explanted during single-level anterior cervical discectomy/fusions. *Surg Neurol Int* 2011;2:23.

11. Epstein NE. Iliac crest versus alternative constructs for anterior cervical spine surgery: Pros, cons, and costs. *Surg Neurol Int* 2012;3 (Suppl 3):S143-56.
12. Fasolis M, Boffano P, Ramieri G. Morbidity associated with anterior iliac crest bone graft. *Oral Surg Oral Med Oral Pathol Oral Radiol* 2012;114:586-91.
13. Hauerberg J, Kosteljanetz M, Bøge-Rasmussen T, Dons K, Gideon P, Springborg JB, et al. Anterior cervical discectomy with or without fusion with ray titanium cage: A prospective randomized clinical study. *Spine* 2008;33:458-64.
14. Kaiser MG, Haid RW, Subach BR, Barnes B, Rodts GE Jr. Anterior cervical plating enhances arthrodesis after discectomy and fusion with cortical allograft. *Neurosurgery* 2002;50:229-38.
15. Korovessis P, Repantis T, Vitsas V, Vardakastanis K. Cervical spondylodiscitis associated with oesophageal perforation: A rare complication after anterior cervical fusion. *Eur J Orthop Surg Traumatol* 2012. [In Press].
16. Kurtz LT, Garfin SR, Booth RE Jr. Harvesting autogenous iliac bone grafts. A review of complications and techniques. *Spine* 1989;14:1324-31.
17. Leung C, Casey AT, Goffin J. Clinical significance of heterotopic ossification in cervical disc replacement: A prospective multicenter clinical trial. *Neurosurgery* 2005;57:759-62.
18. Lied B, Roenning PA, Sundseth J, Helseth E. Anterior cervical discectomy with fusion in patients with cervical disc degeneration: A prospective outcome study of 258 patients (181 fused with discectomy bone graft and 77 fused with a PEEK cage. *BMC Surg* 2010;10:10.
19. Lind BI, Zoega B, Rosén H. Autograft versus interbody fusion cage without plate fixation in the cervical spine: A randomized clinical study using radiostereometry. *Eur Spine J* 2007;16:1251-6.
20. Loeffler BJ, Kellam JF, Sims SH, Bosse MJ. Prospective observational study of donor-site morbidity following anterior iliac crest bone-grafting in orthopaedic trauma reconstruction patients. *J Bone Joint Surg Am* 2012;94:1649-54.
21. Martin GJ Jr, Haid RW Jr, MacMillan M, Rodts GE Jr, Berkman R. Anterior cervical discectomy with freeze-dried fibula allograft: Overview of 317 cases and literature review. *Spine* 1999;24:852-9.
22. Odate S, Shikata J, Kimura H, Soeda T. Hybrid decompression and fixation technique versus plated three-vertebra corpectomy for four-segment cervical myelopathy: Analysis of 81 cases with a minimum 2-year follow-up. *J Spinal Disord Tech* 2012. [In Press].
23. Payer M, May D, Revendrín A. Implantation of an empty carbon fiber composite frame cage after single-level anterior cervical discectomy in the treatment of cervical disc herniation: Preliminary results. *J Neurosurg* 2003;98:143-8.
24. Pointillart V, Cernier A, Vital JM, Senegas J. Anterior discectomy without Interbody fusion for cervical disk herniation. *Eur Spine J* 1995;4:45-51.
25. Prolo DJ, Oklund SA, Butcher M. Toward uniformity in evaluating resulting of lumbar spine operation: A paradigm applied to posterior interbody fusion. *Spine* 1986;11:601-6.
26. Robinson RA, Walker AE, Ferlic DC. The results of anterior Interbody fusion of the cervical spine. *J Bone Joint Surg* 1962;44:1569-87.
27. Samartzis D, Shen FH, Goldberg EJ, An HS. Is autograft the gold standard in achieving radiographic fusion in one-level anterior cervical discectomy and fusion with rigid anterior plate fixation? *Spine* 2005;30:1756-61.
28. Sasso RC, LeHuec JC, Shaffrey C. Iliac crest bone graft donor site pain after anterior lumbar interbody fusion: A prospective patient satisfaction outcome assessment. *Spine Interbody Research Group. J Spinal Disord Tech* 2005;18 Suppl: S77-81.
29. Sawin PD, Ceola W, Mummaneni PV, Praveen V, Stachniak J. Cervical disc arthroplasty with the prestige ST cervical disc: Preliminary results from a multicenter randomized controlled trial. *Neurosurgery* 2005;57:421-2.
30. Scholz M, Reyes PM, Schleicher P, Sawa AG, Baek S, Kandziara F, et al. A new stand-alone cervical anterior interbody fusion device: Biomechanical comparison with established anterior cervical fixation devices. *Spine* 2009;34:156-60.
31. Setzer M, Eleraky M, Johnson WM, Aghayev K, Tran ND, Vrionis FD. Biomechanical comparison of anterior cervical spine instrumentation techniques with and without supplemental posterior fusion after different corpectomy and discectomy combinations: Laboratory investigation. *J Neurosurg Spine* 2012;16:579-84.
32. Sheth JH, Patankar AP, Shah R. Anterior cervical microdiscectomy: Is bone grafting and *in-situ* fusion with instrumentation required? *Br J Neurosurg* 2012;26:12-5.
33. Smith GV, Robinson RA. The treatment of cervical-spine disorders by anterior removal of the intervertebral disc and interbody fusion. *J Bone Joint Surg Am* 1958;40-A: 607-24.
34. Sonntag VK, Klara P. Controversy in spine care. Is fusion necessary after anterior cervical discectomy? *Spine* 1996;21:1111-3.
35. Spallone A. A less invasive technique for harvesting discectomy iliac crest grafts for cervical Interbody fusion. *Technical Note. Surg Neurol* 2007;67:160-2.
36. Steinmetz M, Warbel A, Whitfield M, Bingaman W. Preliminary experience with the DOC dynamic cervical implant for the treatment of multilevel cervical spondylosis. *J Neurosurg* 2002;97 (3 Suppl):S330-6.
37. Van Limbeek J, Jacobs WC, Anderson PG, Pavlov PW. A systematic literature review to identify the best method for a single level anterior cervical Interbody fusion. *Eur Spine J* 2000;9:129-36.