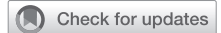

Successful surgical closure of an isolated traumatic atrial septal defect after a device closure failure



Mijoo Kim, MD,^a Si Wan Choi, MD, PhD,^a Jonghee Han, MD,^b Jae Hyeon Yu, MD, PhD,^b and Jae-Hyeong Park, MD, PhD,^a Daejeon, Korea

From the ^aDivision of Cardiology, Department of Internal Medicine, and ^bDepartment of Thoracic and Cardiovascular Surgery, Chungnam National University Hospital, Chungnam National University School of Medicine, Daejeon, Korea.

Disclosures: The authors reported no conflicts of interest.

The *Journal* policy requires editors and reviewers to disclose conflicts of interest and to decline handling or reviewing manuscripts for which they may have a conflict of interest. The editors and reviewers of this article have no conflicts of interest.

Received for publication Feb 8, 2022; revisions received March 24, 2022; accepted for publication April 11, 2022; available ahead of print June 22, 2022.

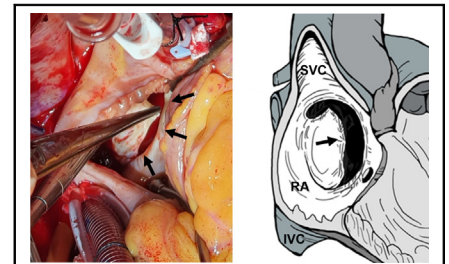
Address for reprints: Jae-Hyeong Park, MD, PhD, Department of Cardiology in Internal Medicine, Chungnam National University, Chungnam National University Hospital, 282 Munhwa-ro, Jung-gu, Daejeon, 35015, Korea (E-mail: jaehpark@cnu.ac.kr).

JTCVS Techniques 2022;14:104-6

2666-2507

Copyright © 2022 The Author(s). Published by Elsevier Inc. on behalf of The American Association for Thoracic Surgery. This is an open access article under the CC BY-NC-ND license (<http://creativecommons.org/licenses/by-nc-nd/4.0/>).

<https://doi.org/10.1016/j.jtc.2022.06.006>



Intraoperative findings showed a separated interatrial septum with irregular boundary.

CENTRAL MESSAGE

An atypically shaped ASD, with a history of chest trauma, should be considered a traumatic ASD and be repaired by surgery rather than by device closure after multidisciplinary discussion.

▶ Video clip is available online.

Isolated traumatic atrial septal defect (ASD) is rare and usually follows blunt chest trauma (BCT).¹ It is difficult to suspect and treat a hemodynamically stable isolated traumatic ASD without suspecting a previous chest injury. Device closure is the standard method for repairing typical secundum ASDs with favorable shapes and sizes.² Surgical repair is considered in some cases of large ASDs and multiple rim deficiency. We recently identified a patient with a traumatic ASD after BCT. We surgically repaired the traumatic ASD after failure of device closure.

CLINICAL SUMMARY

A 63-year-old man presented to our emergency department with postural hypotension and dizziness. Six months previously, he had a motor vehicle accident and had undergone surgeries at another hospital due to multiple injuries, including hepatic rupture, hemoperitoneum, hemopneumothorax, multiple rib fractures, fracture of both femurs, and subdural hemorrhage. He experienced persistent dizziness and lowered blood pressure during rehabilitation. His blood pressure and heart rate were 80/60 mm Hg and 80 beats per minute, respectively, on admission to our hospital. Troponin-I and N-terminal-pro B type natriuretic peptide levels were 216.7 pg/mL and 4106 pg/mL, respectively.

His electrocardiogram showed T-wave inversion in leads I, aVL, and V3~V6, and chest radiographs revealed fixation of multiple rib fractures.

Transthoracic echocardiography showed an ASD with a significant left-to-right shunt and an enlarged right ventricle. Transesophageal echocardiography revealed an elongated, oval-shaped, ASD of approximately 27 × 10 mm (Figure 1, Video 1). The interatrial septum showed excessive fluttering, and there was no sufficient rim near the aortic valve. After the transthoracic echocardiography and transesophageal echocardiography examinations, we concluded this ASD to be an atypical form of secundum ASD with only aortic rim deficiency. We chose device closure without having a multidisciplinary team discussion, and tried closing the defect with a 33 mm-sized Figulla Flex II occluder (Occlutech GmbH). However, the device could not be positioned successfully because of the insufficient and redundant rims.

During repeated attempts to position the device, the patient had cardiac tamponade due to atrial rupture by a wire. After an emergency pericardiocentesis, emergency surgery was performed to repair the cardiac perforation.

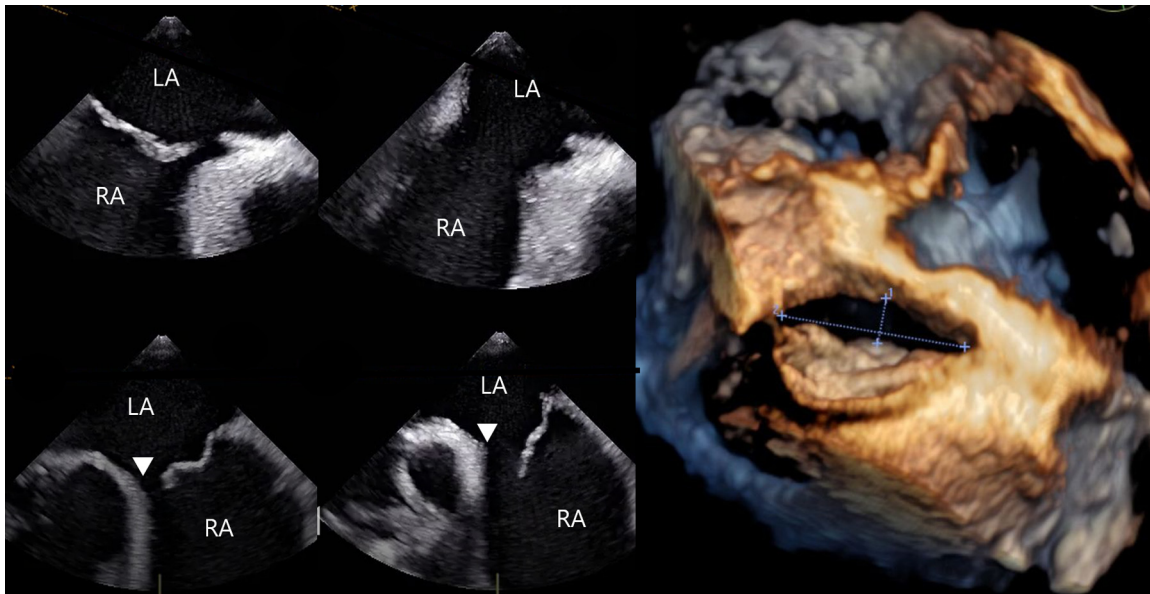
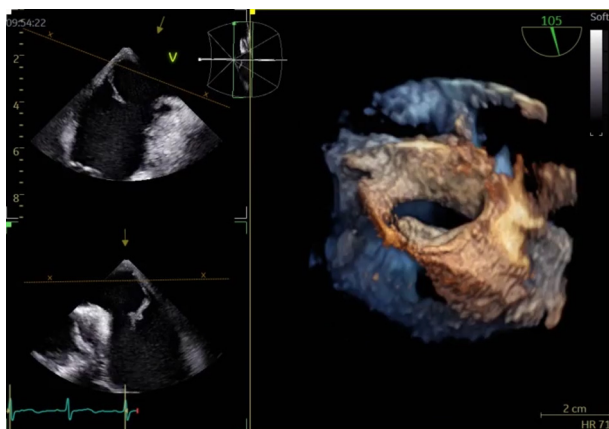


FIGURE 1. Transesophageal echocardiography revealing an elongated and oval atrial septal defect having no aortic rim. LA, Left atrium; RA, right atrium.

During the surgery, a traumatic ASD with a separated interatrial septum and an irregular boundary was found between the anterior atrial rim and the fossa ovalis, suggesting a tear (Figure 2). The traumatic ASD was successfully repaired with a direct suture to the fossa ovalis and anterior rim without a patch after the median sternotomy. The patient was discharged without any postoperative complications.

Written informed consent for this publication was obtained from the patient. Thus, the institutional review board waived approval of this case report.



VIDEO 1. Transesophageal echocardiography demonstrates about 27 × 10-mm sized elongated oval-shaped defect with irregular border that is well-demonstrated in the 3-dimensional reconstructed image. Video available at: [https://www.jtcvs.org/article/S2666-2507\(22\)00359-5/fulltext](https://www.jtcvs.org/article/S2666-2507(22)00359-5/fulltext).

DISCUSSION

Traumatic ASD may occur mainly at the fossa ovalis. Differentiating from congenital ASDs without suspecting a previous traumatic injury may be difficult. Because patients with traumatic ASD are associated with other cardiac injuries, surgery treatment is the main treatment option in most cases.^{3,4} However, if the diagnosis is delayed, it is more likely to be overlooked. In this case, ASD was not found immediately after the injury. It was discovered 6 months later. If the patient had undergone an extended focused assessment with sonography for trauma immediately after the motor vehicle accident, or we had considered the trauma history, the traumatic ASD could have been diagnosed earlier.

Transcatheter device closure is widely used for secundum ASDs because it is less invasive, with a success rate comparable with surgical repair.⁵ However, not all secundum ASDs are suitable for device closure. Usually, a surgical closure is chosen for ASDs with large size and unfavorable morphology for device closure. An attending physician can determine a suitable closure technique based on the anatomical features and defect types.

In this case, without focusing on the history of BCT, we chose device closure despite the ASD having an unusual morphology suggestive of a traumatic injury. If we had considered the ASD to have a traumatic and not a congenital cause, we would have selected surgical closure over the device closure to avoid the associated complication and the need for emergent surgery. Moreover, we can do the surgery with a minimally invasive strategy. Another imaging study, including computed tomography with 3-dimensional reconstruction, might be

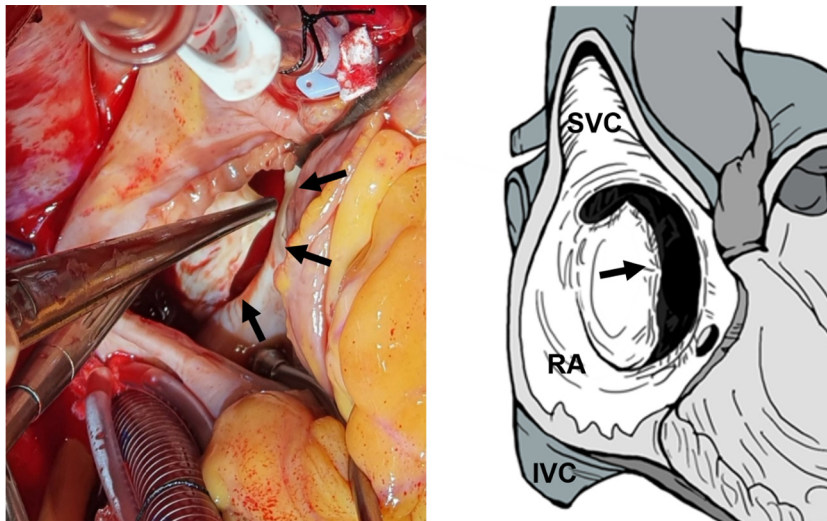


FIGURE 2. The operative finding reveals a separated interatrial septum between the anterior atrial rim and the fossa ovalis with an irregular boundary (arrows), which is shown in the illustration (arrow). SVC, Superior vena cava; RA, right atrium; IVC, inferior vena cava.

helpful in choosing the proper treatment option. A previous discussion with a multidisciplinary team, including cardiac surgeons, imaging specialists, and interventional cardiologists, would have given a better outcome.

CONCLUSIONS

When an ASD with atypical morphology is found in a patient with a history of chest trauma, traumatic ASD should be considered. Surgical closure is the best solution in this case.

References

1. Pretre R, Chilcott M. Blunt trauma to the heart and great vessels. *N Engl J Med.* 1997;336:626-32.
2. Du Z-D, Koenig P, Cao Q-L, Waight D, Heitschmidt M, Hijazi ZM. Comparison of transcatheter closure of secundum atrial septal defect using the Amplatzer septal occluder associated with deficient versus sufficient rims. *Am J Cardiol.* 2002;90:865-9.
3. End A, Rödler S, Oturanlar D, Domanig E, Havel M, Kassal H, et al. Elective surgery for blunt cardiac trauma. *J Trauma.* 1994;37:798-802.
4. Ortiz Y, Waldman AJ, Bott JN, Carlan SJ, Madruga M. Blunt chest trauma resulting in both atrial and ventricular septal defects. *Echocardiography.* 2015;32:592-4.
5. Berger F, Vogel M, Alexi-Meskishvili V, Lange PE. Comparison of results and complications of surgical and Amplatzer device closure of atrial septal defects. *J Thorac Cardiovasc Surg.* 1999;118:674-80.