



CT findings in two cats with broncholithiasis

Patrick Byrne¹, James S Berman¹, Graeme Sutcliffe Allan², Jennifer Chau¹ and Vanessa R Barrs¹

Journal of Feline Medicine and Surgery
Open Reports
 1–6

© The Author(s) 2016
 Reprints and permissions:
sagepub.co.uk/journalsPermissions.nav
 DOI: 10.1177/2055116916676176
jfmsopenreports.com

This paper was handled and processed by the European Editorial Office (ISFM) for publication in *JFMS Open Reports*



Abstract

Case series summary Chronic inflammatory airway disease with secondary broncholithiasis was diagnosed in two cats from CT and bronchoalveolar lavage cytological findings. In one cat with progressively worsening lower respiratory tract signs, more than 80 discrete, highly attenuating endobronchial opacities were detected on thoracic CT. The bronchololiths were distributed throughout the right middle, and left and right caudal lung lobes, and the caudal part of the left cranial and accessory lobes. In the other cat broncholithiasis was an incidental finding on thoracic radiographs taken during diagnostic investigation of inappetence. On thoracic CT, 25 calcified endobronchial opacities were detected in the left caudal lung lobe in secondary and tertiary bronchi. CT features of chronic inflammatory airway disease were present in both cases, including bronchiectasis, atelectasis, flattening of the diaphragm and bronchial wall thickening.

Relevance and novel information This is the first report to document CT features of broncholithiasis in cats. Feline broncholithiasis should be considered as a differential diagnosis in any case where calcified endobronchial material is evident on thoracic radiographs or CT.

Accepted: 3 October 2016

Introduction

Broncholithiasis, the presence of mineralised material within the bronchial lumen, is a well-documented condition in humans and was first reported by Aristotle (384–322 BC), who described the ‘spitting of stones’ (lithoptysis).¹ In humans, bronchololiths are formed from extrusion of a calcified lymph node through an eroded bronchial wall into the bronchial lumen.^{1–3} In contrast, feline broncholithiasis has only been described in two cats.^{2,4} The proposed aetiology of the bronchololiths in both cases was dystrophic mineralisation of intraluminal bronchial secretions secondary to chronic inflammatory airway disease. In this report, we describe two further cases in cats, as well as the CT features of feline broncholithiasis.

Case series description

Case 1

A 9-year-old, male, neutered Cornish Rex was referred to the Valentine Charlton Cat Centre (VCCC) for a 3 month history of inappetence, weight loss and progressively worsening respiratory signs, including cough and dyspnoea. A short course of oral prednisolone had been prescribed by

the referring veterinarian 2 months before referral, after which there was a transient improvement in signs.

On physical examination at referral the cat weighed 4.88 kg and was in good body condition (body condition [BCS] score 3/5). Heart rate (HR; 180 beats per min [bpm]), respiratory rate (RR; 28 breaths per min) and rectal temperature (37.5°C) were normal, but there was increased inspiratory effort. On auscultation lung sounds were moderately increased over all lung fields, and a grade IV/VI left parasternal systolic heart murmur was detected. Three-view thoracic radiographs were performed (Figure 1). Several calcific aggregations were

¹Faculty of Veterinary Science, School of Life and Environmental Sciences, University of Sydney, Sydney, Australia

²Veterinary Imaging Associates, St Leonards, Australia

Corresponding author:

Vanessa Barrs BVSc, PhD, MVetClinStud, FANZCVS, Faculty of Veterinary Science, University of Sydney, NSW 2006, Australia
 Email: vanessa.barrs@sydney.edu.au



Creative Commons Non Commercial CC-BY-NC: This article is distributed under the terms of the Creative Commons

Attribution-NonCommercial 3.0 License (<http://www.creativecommons.org/licenses/by-nc/3.0/>) which permits non-commercial use, reproduction and distribution of the work without further permission provided the original work is attributed as specified on the SAGE and Open Access pages (<https://us.sagepub.com/en-us/nam/open-access-at-sage>).

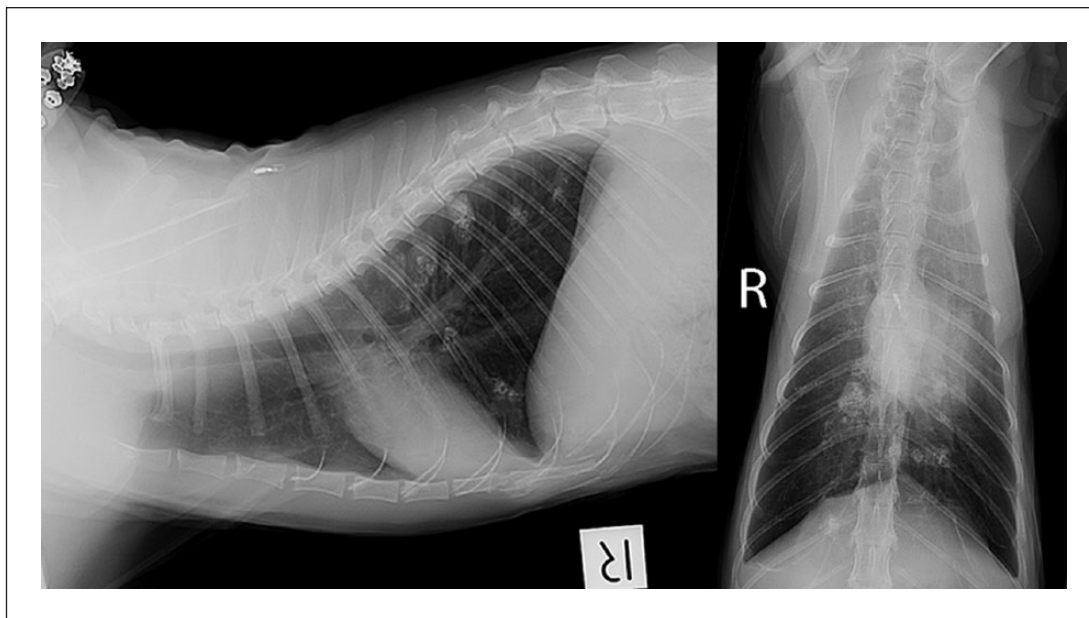


Figure 1 Case 1: lateral and ventrodorsal view thoracic radiographs. There is a reticular interstitial pattern with increased opacity of the bronchial walls. Multiple mineralised soft tissue nodules with irregular margins are present within the caudal lung fields, the largest of which lies within the dorsal right caudal lung lobe

present within the right middle and both caudal lung lobes. Clearly margined soft tissue opacities surrounded 5/8 larger aggregates, with diameters ranging from 6–18 mm. The diameter of the calcific material itself ranged between 1 and 12 mm. Calcification appeared to be within the bronchial walls in some places. It was difficult to determine definitively whether intraluminal calcifications were also present. A reticular interstitial pattern of the remaining pulmonary parenchyma and bronchiectasis of the right cranial lobar bronchus was evident. Pulmonary vasculature was normal. On echocardiography there was evidence of mild left ventricular free wall hypertrophy in diastole, and there was mild tricuspid valve regurgitation (peak velocity 2.5 m/s). All other parameters, including atrial size, were within reference limits. Systolic blood pressure was normal (130 mmHg, Doppler method).

Thoracic CT was performed under general anaesthesia using contiguous 0.8 mm helical slices (Philips Brilliance, 16 Slice; Philips Medical Systems). There was a generalised increase in opacity of bronchial walls throughout the thorax. Approximately 80 discrete 2–9 mm diameter, ellipsoid-to-linear mineralised endobronchial concretions were present embedded in soft-tissue opacity intraluminal bronchial material, generally adjacent to the bronchial wall (Figure 2). Opacity of the concretions ranged from 981–1850 HU. There was minimal to no enhancement (10–20 HU) post-contrast administration. Broncholiths were predominantly distributed throughout the right middle, left and right caudal lung

lobes, and, to a lesser extent, in the caudal part of the left cranial and accessory lobes. The bronchial lumen diameter in affected lung lobes was greater than that of accompanying pulmonary vessels. Bronchiectasis was present in the right cranial lung lobe. Flattening of the diaphragm was apparent in the sagittal projections.

Cytological preparations of bronchoalveolar lavage (BAL) fluid collected by unguided BAL comprised 77% neutrophils, 15% eosinophils and 8% macrophages. Circular aggregates of mineralised spicules were present throughout the sample. No infectious agents were detected. Cytological findings were consistent with chronic, active airway inflammation with mineralised airway deposits. A presumptive diagnosis of chronic feline bronchial disease with secondary broncholithiasis was made. Empirical treatment using doxycycline 5 mg/kg q12h and prednisolone 2mg/kg q24h (both PO), was initiated pending culture and susceptibility results from the BAL.

A very light mixed bacterial growth on aerobic culture was consistent with contamination by oropharyngeal flora. At a recheck examination 1 week later, the owner reported a marked reduction in the frequency of coughing. Treatment was commenced with a metered dose inhaler (MDI) containing salbutamol (25 µg) and fluticasone (125 µg) twice daily (Seretide; GlaxoSmithKline Australia). The prednisolone dose was tapered over 5 days and then discontinued.

The cat returned to the primary care veterinarian for follow-up care. At a recheck examination, 4 years after

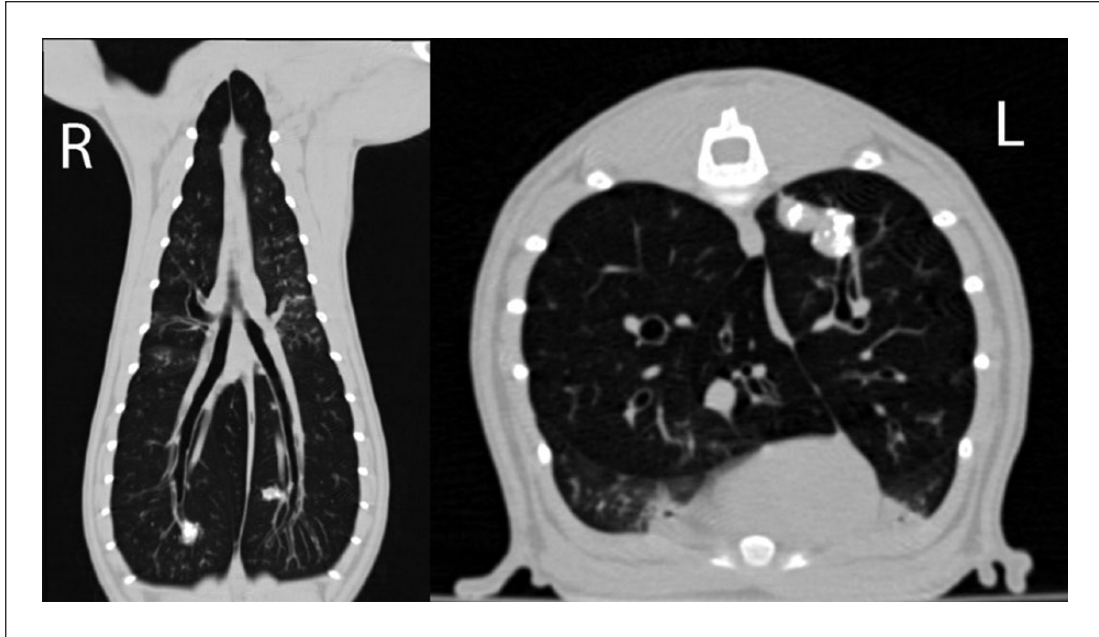


Figure 2 CT images of case 1 reformatted as a maximum intensity projection in dorsal plane and single-slice image in transverse plane displayed in a bone window (window level -300 , window width 1500). In the dorsal plane there are mineral attenuating foci in the right and left caudal lung lobes that are associated with the segmental branches of the caudal main stem bronchi. These mineral-attenuating foci are surrounded by a small region of soft tissue attenuation. In the transverse plane the focal area of mixed mineral and soft tissue attenuation in the left caudal lung lobe is arranged in a tubular shape that is confluent with the lobar bronchus. There is mild generalised thickening of the bronchial walls

initial presentation, the owner reported that there was improvement in respiratory signs following initial treatment, but that sporadic episodes of dyspnoea and coughing still occurred. Compliance with MDI therapy had been low. Physical examination findings included body weight 4.48 kg, tachycardia (HR 240 bpm) and a grade III/VI systolic heart murmur, mild tachypnoea (RR 36 breaths per min) with normal respiratory effort, and mild-to-moderately increased lung sounds in all lung fields on thoracic auscultation. Haematology was unremarkable and serum biochemistry revealed mild elevations in urea (17.7 mmol/l; reference interval [RI] 5 – 15 mmol/l) and creatinine (0.24 mmol/l; RI 0.08 – 0.2 mmol/l) and a normal total thyroxine (T₄; 23 nmol/l; RI 10 – 60 nmol/l). Urine specific gravity was 1.018 , urine sediment was benign and there was no proteinuria (urine protein:creatinine ratio 0.1), and systolic blood pressure was normal (130 mmHg). The cat was diagnosed with IRIS stage II chronic kidney disease (CKD) and referred back to the primary care veterinarian for ongoing management of CKD and inflammatory airway disease, with a recommendation to re-institute MDI therapy using fluticasone/salmeterol.

Case 2

A 14-year-old, female, spayed domestic shorthair cat was presented to the VCCC for further investigation of several mineralised discrete miliary nodules that were

detected on routine thoracic radiographs taken 3 weeks previously when the cat had presented for acute onset lethargy and inappetence. There was no history of respiratory signs.

The owner, a veterinarian, had performed a complete blood count and serum biochemistry, which were unremarkable. Serology for feline immunodeficiency virus antibody and feline leukaemia virus antigen was negative. Thoracic radiographs revealed several discrete mineralised miliary nodules in the left caudal lung lobe (Figure 3). An unguided BAL was performed to further investigate this finding. On cytology of BAL fluid there were 58% macrophages, 5% lymphocytes and 37% eosinophils. No microorganisms were detected, and bacterial culture was negative.

On physical examination at referral the cat weighed 3.57 kg and was in good body condition (BCS $3.5/5$). HR (196 bpm), RR (36 breaths per min) and rectal temperature (38.6°C) were normal. Increased tracheal sensitivity was noted on palpation. Both thyroid lobes were mildly enlarged and rounded (left 4 mm, right 5 mm diameter) on palpation. Total T₄ was high normal (52 nmol/l; RI 6 – 52 nmol/l) and in-house heartworm antigen test was negative.

Three-view thoracic radiographs were performed. Associated with consolidation of the left caudal lung lobe were approximately 25 linearly distributed mineral opacities measuring up to 2 mm, which followed the line

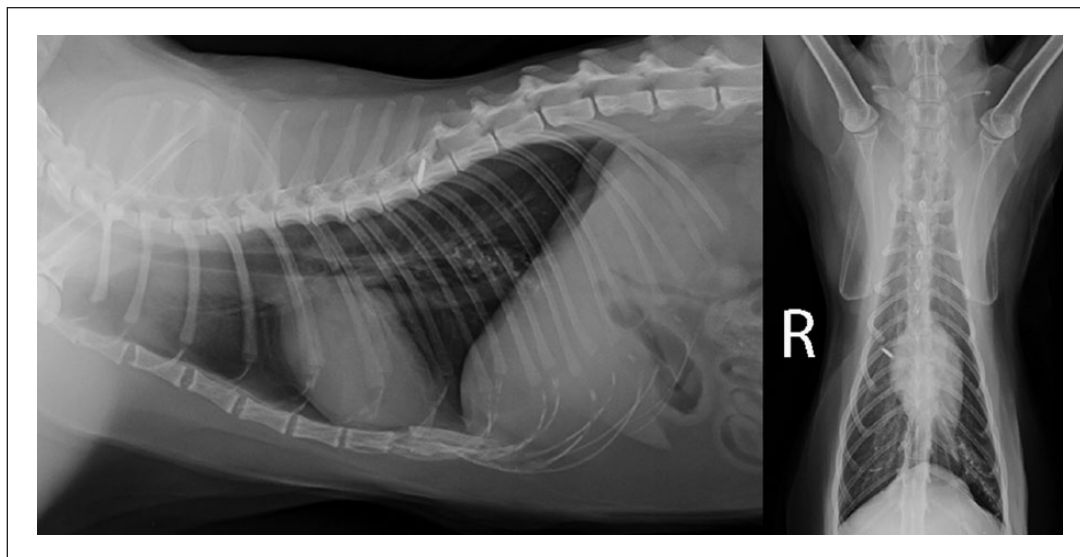


Figure 3 Case 2: lateral and ventrodorsal view thoracic radiographs. There are multifocal, somewhat linearly distributed mineral opacities within the left caudal lung lobe along the line of the main lobar bronchus. Linear soft tissue margins are associated with the mineralised opacities, and there is a generalised increase in bronchial wall opacity

of the main lobar bronchus (Figure 3). Linear soft tissue margins were associated with the mineralised opacities and there was a generalised increase in bronchial wall opacity. Thoracic CT, performed as for case 1, revealed mixed mineralised and soft tissue attenuating material linearly distributed within the lumen of the ventral branches of the left caudal bronchi, with hyperattenuation of surrounding pulmonary parenchyma (Figure 4). Circular, nodular mineral opacities (954–2187 HU) up to 4 mm in diameter were present within the bronchial lumen of secondary and tertiary bronchi. Affected bronchi were air-filled and expanded with peripheral branches measuring up to 8 mm in diameter. There was bronchiectasis and failure of tapering of the right middle lung lobe with the bronchus measuring 3 mm in diameter peripherally with no associated abnormality of the pulmonary parenchyma. Some degree of flattening of the diaphragm was present.

A presumptive diagnosis of chronic inflammatory airway disease with secondary broncholithiasis was made based on CT and BAL cytology. The cat was prescribed MDI therapy with salbutamol (25 µg) and fluticasone (125 µg) q12h (Seretide; GlaxoSmithKline Australia) and doxycycline 5 mg/kg q12h PO for 3 weeks. Repeat serum total T4 was recommended, as concurrent hyperthyroidism was suspected. Frequency of MDI therapy was reduced to q24h 1 month post-discharge. At last contact by telephone, 3 years after initial presentation, the cat had no respiratory signs and at the time of writing is maintained on MDI therapy. Hyperthyroidism had been confirmed on a repeat total T4 and treatment with radioiodine was curative.

Discussion

The two cats in this report had evidence of chronic inflammatory airway disease on thoracic radiographs, CT and BAL cytology. Dystrophic mineralisation of inspissated airway exudates was the likely cause of broncholithiasis in both cases, similar to the mechanism described in the only other two cases of broncholithiasis reported in cats.^{2,4} Consistent with this putative mechanism, in one of our cases aggregates of mineralised material were detected on BAL cytology. Unlike humans with broncholithiasis, where pulmonary tuberculosis and histoplasmosis are the most common causes of bronchial lymph node calcification and extrusion, there was no evidence of bacterial or mycotic pneumonia in any of the feline cases.⁵⁻⁷

While not proven, the presence of broncholithiasis is likely suggestive of a chronic time course for the inflammatory airway disease in these two cats. Interestingly, respiratory signs had only been detected by the owner in the 3 months before presentation in case 1, and not at all in case 2, in which broncholiths were an incidental radiological finding. However, clinical signs can go unnoticed by owners, even in cats with severe respiratory disease, as evidenced in a series of feline pyothorax cases where 40% of owners of affected cats did not notice respiratory signs before presentation for acute respiratory decompensation.⁸ Thus, chronic inflammatory airway disease and broncholithiasis cannot be excluded, even in cats with no history of lower respiratory tract disease.

By contrast, it is possible that broncholithiasis as an incidental finding is not clinically relevant in cases where

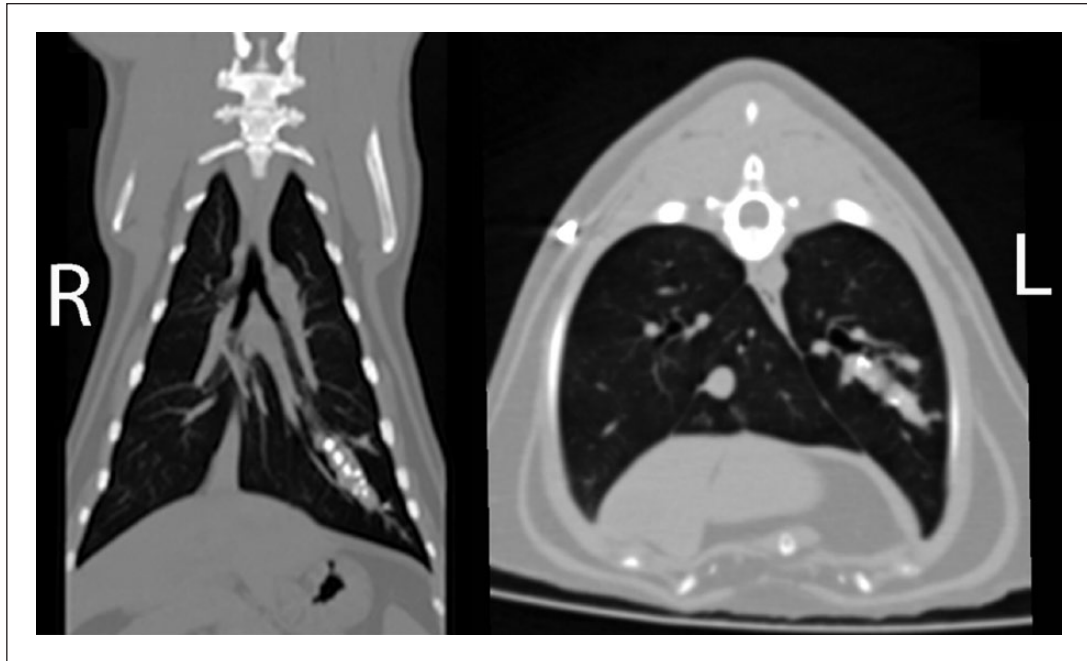


Figure 4 CT images of case 2 reformatted as a maximum-intensity projection in dorsal plane and transverse plane displayed in a bone window (window level -250 , window width 1600). In the dorsal plane, the periphery of the left caudal main stem bronchus contains multiple mineral-attenuating foci surrounded by soft tissue attenuation. In the transverse plane, obstruction of the bronchial lumen with mixed mineral and soft tissue attenuation is evident. The bronchial wall is mildly thickened and irregular, compatible with regional bronchiectasis

cats have no lower respiratory tract signs historically or on physical examination. A recent study comparing thoracic CT findings in cats with and without respiratory signs found 77% of asymptomatic cats had abnormalities of thoracic structures,⁹ with 24% of these cats having evidence of bronchial disease. Bronchial changes were mainly wall thickening and mucus plugging. Interestingly, broncholiths were noted in one cat; however, no details were provided and it was not clear if this cat had respiratory signs or was asymptomatic. Given the suspected pathogenesis of feline broncholithiasis, their presence likely suggests the presence of lower airway inflammation and investigation for this would be prudent, even in an asymptomatic cat.

The two previously reported cases of feline broncholithiasis were confirmed at necropsy where broncholiths were present alongside intraluminal plugs of eosinophilic² or mucopurulent⁴ and cellular debris. The CT findings in our cases were also consistent with this finding, with mineralised opacities embedded in soft tissue opacity intraluminal bronchial material. The distribution of the broncholiths was linear, following the arboreal pattern of the bronchi in both left and right lung lobes, and reflecting areas of bronchial secretion accumulation. In the previously reported cases, histological findings at necropsy showed evidence of severe diffuse chronic inflammatory airway disease with bronchiectasis,

atelectasis, pulmonary fibrosis, goblet cell hyperplasia, bronchial gland hyperplasia and hypertrophy, and lymphocytic inflammation of affected bronchial lamina propria.^{2,4} In our cases, there was CT and radiographic evidence of diffuse lower respiratory tract airway involvement. Evidence of chronic inflammatory airway disease included bronchiectasis of the right cranial lung lobe (case 1) or the right middle lung lobe (case 2), atelectasis, flattening of the diaphragm and bronchial wall thickening.

Neutrophilic and/or eosinophilic inflammation in BAL fluid is typical but not pathognomonic for feline chronic inflammatory airway disease.^{10,11} A limitation in the current study was the absence of comprehensive testing for heartworm and lungworm, which was declined by the owners, but could result in similar cytological findings.

The clinical significance of broncholithiasis in cats is uncertain, with both cats in this report alive 4 years after diagnosis. Bronchoscopic broncholithectomy was not performed in either cat owing to the relative inaccessibility of many affected small airways. In human broncholithiasis, conservative management is indicated if clinical signs are minimal.⁵ If more severe signs are present, such as bronchiectasis, haemoptysis or broncho-oesophageal fistulae, or where there is uncertainty about the diagnosis, surgery or bronchoscopy is indicated.^{3,5}

Conclusions

Broncholithiasis in cats can occur secondarily to chronic inflammatory airway disease. Radiographic features of nodular mineralisation and bronchial changes are seen. Definitive diagnosis can be readily established on thoracic CT to confirm the location of mineralised material within the bronchial lumen and presence of features of chronic inflammatory airway disease such as bronchiectasis, flattening of the diaphragm, atelectasis and bronchial wall thickening.

Funding The authors received no financial support for the research, authorship, and/or publication of this article.

Conflict of interest The authors declared no potential conflicts of interest with respect to the research, authorship, and/or publication of this article.

References

- 1 Craig K, Keeler T and Buckley P. **Broncholithiasis: a case report.** *J Emerg Med* 2002; 23: 359–363.
- 2 Talavera J, del Palacio MJF, Bayon A, et al. **Broncholithiasis in a cat: clinical findings, long-term evolution and histopathological features.** *J Feline Med Surg* 2008; 10: 95–101.
- 3 Olson E J, Utz JP and Prakash UB. **Therapeutic bronchoscopy in broncholithiasis.** *Am J Respir Crit Care Med* 1999; 160: 766–770.
- 4 Allan GS and Howlett CR. **Miliary broncholithiasis in a cat.** *J Am Vet Med Assoc* 1973; 162: 214–216.
- 5 Menivale F, Deslee G, Vallerand H, et al. **Therapeutic management of broncholithiasis.** *Ann Thorac Surg* 2005; 79: 1774–1776.
- 6 Seo JB, Song KS, Lee JS, et al. **Broncholithiasis: review of the causes with radiologic-pathologic correlation.** *Radiographics* 2002; 22: 199–213.
- 7 Yeo CD, Baeg MK and Kim JW. **A case of endobronchial aspergilloma presenting as a broncholith.** *Am J Med Sci* 2012; 20: 1–3.
- 8 Barrs VR, Allan GS, Beatty JA, et al. **Feline pyothorax: a retrospective study of 27 cases in Australia.** *J Feline Med Surg* 2005; 7: 211–212.
- 9 Lamb CR and Jones ID. **Associations between respiratory signs and abnormalities reported in thoracic CT scans of cats.** *J Small Anim Pract* 2016; 57: 561–567.
- 10 Moise NS, Wiedenkeller D, Yeager AE, et al. **Clinical, radiographic, and bronchial cytologic features of cats with bronchial disease: 65 cases (1980–1986).** *J Am Vet Med Assoc* 1989; 194: 1467–1473.
- 11 Reinero C. **Advances in the understanding of pathogenesis, and diagnostics and therapeutics for feline allergic asthma.** *Vet J* 2011; 190: 28–33.