

Necrotizing canaliculitis: A case report and review of the literature

Osama Al Sheikh¹, Rawan Al Thaqib¹, Naif Al Sulaiman¹, Eman M. Al-Sharif²

Access this article online

Quick Response Code:



Website:

www.saudijophthalmol.org

DOI:

10.4103/SJOPT.
SJOPT_110_21

Abstract:

Canaliculitis is defined as infection of the canalicular part of the lacrimal system. Despite usual presenting clinical characteristics such as pouting of the lacrimal punctum, discharge, and redness at the medial canthus area, it is usually misdiagnosed and overlooked. The presence of punctal ulceration and tissue necrosis is an uncommon presentation in these patients. We report a case of a 35-year-old female with a 3-day history of left lower eyelid medial swelling, tenderness, and discharge. She was found to have left lower eyelid diffuse conjunctival injection and swelling involving the lower lacrimal punctum with whitish necrotic tissue. The patient was taken to the minor treatment room and debridement of the necrotic tissue was done and swabs were taken for culture and sensitivity. The punctum was found to be open with deroofting of the proximal canalicular system due to the severe nature of the infection; this was followed by irrigation using moxifloxacin and povidone-iodine. The patient was started on systemic antibiotics, topical antibiotic eye drops, and povidone-iodine sticks to clean the affected area. Few days later, the microbiology results revealed infection by *Pseudomonas aeruginosa*, and the patient was improving gradually until she had complete resolution of the infection.

Keywords:

Canaliculitis, infection, lacrimal system, necrotizing, *Pseudomonas*

INTRODUCTION

Canaliculitis is defined as infection of the proximal part of the lacrimal drainage system. This condition can be caused by primary infectious organisms or secondary to punctal plugs and lacrimal stents.^[1] Despite the well-documented presenting characteristics of this infection such as ocular discharge, pouting of the lacrimal punctum, tearing, and swelling of the adjacent eyelid, it can be misdiagnosed and confused with similar conditions such as conjunctivitis, dacryocystitis, and inflamed chalazion. This misdiagnosis can lead to delay in reaching the accurate diagnosis to a period that can reach up to 10 years as documented in some cases.^[2-4]

Classically, *Actinomyces* species are well known to be the most common organisms causing primary canaliculitis.^[4] However,

recent studies have shown different results with *Streptococcus* and *Staphylococcus* species becoming more prevalent. *Pseudomonas aeruginosa*, a Gram-negative bacillus, can be the causative organism in cases of canaliculitis, but it is not as common as other species, especially in cases of primary canaliculitis.^[2,3]

Diagnosing canaliculitis cases requires a high index of clinical suspicion. Hence, taking careful history and performing accurate examination are vital in such situations. The management plan usually starts with conservative measures, such as topical and systemic antibiotics, warm compressors, local massage, syringing, and irrigation. Nevertheless, some cases are refractory to medical treatment due to the presence of concretions which shield the offending organism from antibiotics. Surgical intervention, such as canaliculotomy or snip punctoplasty with removal of concretions and irrigation of the lacrimal system with antibiotics, is commonly essential to eradicate the infection in patients not responding to medical management.^[5]

This is an open access journal, and articles are distributed under the terms of the Creative Commons Attribution-NonCommercial-ShareAlike 4.0 License, which allows others to remix, tweak, and build upon the work non-commercially, as long as appropriate credit is given and the new creations are licensed under the identical terms.

For reprints contact: WKHLRPMedknow_reprints@wolterskluwer.com

How to cite this article: Al Sheikh O, Al Thaqib R, Al Sulaiman N, Al-Sharif EM. Necrotizing canaliculitis: A case report and review of the literature. Saudi J Ophthalmol 2021;35:263-5.

¹Oculoplastic and Orbit Division, King Khaled Eye Specialist Hospital, ²Department of Ophthalmology, College of Medicine, Princess Nourah bint Abdulrahman University, Riyadh, Saudi Arabia

Address for correspondence: Dr. Osama Al Sheikh, Oculoplastic and Orbit Division, King Khaled Eye Specialist Hospital, PO Box 7191, Riyadh 11462, Saudi Arabia. E-mail: oshaikh@kkesh.med.sa

Submitted: 19-May-2021

Revised: 21-May-2021

Accepted: 23-May-2021

Published: 17-Nov-2021

CASE REPORT

This is a 35-year-old medically-free female who presented to King Khalid Eye Specialist Hospital (KKESH) emergency room complaining of left lower eyelid medial swelling, tenderness, tearing, and discharge for 3 days duration. On further questioning, the patient denied history of trauma, punctal plugs application, lacrimal system infections, or previous lacrimal surgeries. Examination showed left lower eyelid diffuse conjunctival injection and swelling involving the lower lacrimal punctum that looked like adherent pus with an adjacent area suspicious for necrotic tissue, as evident in [Figure 1a]. She was started on topical erythromycin ointment and moxifloxacin eye drops as the provisional diagnosis was canaliculitis. On follow-up 2 days later, the patient reported no symptomatic improvement, and examination demonstrated signs of infection progression with enlargement of the necrotic area to cover the entire punctum and new onset of diffuse bulbar conjunctival injection [Figure 1b]. At this point, the clinical diagnosis of ulcerative canaliculitis was ascertained, and the patient was taken to the minor treatment room for further intervention.

Under local anaesthesia, debridement of the necrotic tissue was done, and this was followed by irrigation using moxifloxacin and povidone-iodine. The punctum was found to be open with deroofting of the proximal canalicular system secondary to the aggressive nature of the infection. Moreover, a surgical biopsy was taken from the margin of the necrotic area and sent for histopathology and microbiology for culture and sensitivity. The patient was started on oral amoxicillin-clavulanate potassium (Augmentin) oral tablets 1 g twice daily, topical erythromycin ointment, moxifloxacin eye drops, and povidone sticks to clean the medial part of the left lower eyelid.

On follow-up the next day, the patient reported significant improvement in her symptoms and examination showed less

conjunctival injection with shrinkage of the infected area and absence of further necrosis as demonstrated in [Figure 1c]. The initial microbiology results showed Gram-negative bacilli organism. The histopathology report showed tissue infiltrated predominantly with acute inflammatory cells, and the Gram stain showed infiltration with Gram-negative bacilli. As the patient was demonstrating significant clinical improvement with the above mentioned treatment, the same antibiotics were continued along with the sterilizing povidone-iodine sticks.

Five days later, the patient was much better subjectively and reported major improvement. Her examination showed a quiet left eye, no more conjunctival injection, and no more discharge or necrotic tissue in the left lower lacrimal punctum area. The microbiology culture results confirmed infection by *P. aeruginosa* which is sensitive to fluoroquinolone, gentamicin, and ceftazidime. The patient completed a full-course of topical and systemic antibiotics and she had complete resolution of canaliculitis both subjectively and objectively as shown in [Figure 1d]. Fortunately, 1 year after her initial presentation, she was found to have no recurrence of her condition with no tearing.

DISCUSSION

Canaliculitis is a disorder that is usually overlooked and misdiagnosed due to the similarity of presenting clinical features to other conditions such as conjunctivitis, marginal chalazion, and dacryocystitis.^[2] In such situations, delay in reaching the diagnosis and initiation of the appropriate management may lead to undesirable complications. Canaliculitis cases caused by *P. aeruginosa* can be rarely associated with concomitant microbial keratitis, which may end up with devastating outcomes.^[6] Therefore, early diagnosis and management is of utmost importance to prevent such complications. Fortunately, our patient presented early within 3 days, which led to immediate initiation of treatment, resulting in favorable outcome. Otherwise, negligence with delay in management in such cases might result in rapid progression of the infection due to the virulent behavior of this organism. In fact, this hypothetically will result in worse outcome as it might endanger the integrity of the canalicular system and even the cornea.

In Saudi Arabia, Gogandy *et al.* studied the clinical features and bacteriology of 131 canaliculitis cases presenting to KKESH, Riyadh, Saudi Arabia, which is one of the major tertiary eye centers in the Middle East.^[2] In their study, *Streptococcus* species were found to be the most common causative organisms (48.2%), while *P. aeruginosa* accounted for only 4.6% of primary canaliculitis cases. These results are consistent with most published studies.^[2,4,5]

P. aeruginosa is considered a rare causative organism of primary canaliculitis. However, it has been found in the literature to have common association with the using punctal plugs or lacrimal stents, with some studies showing 45% of secondary canaliculitis cases caused by this organism.^[1] In

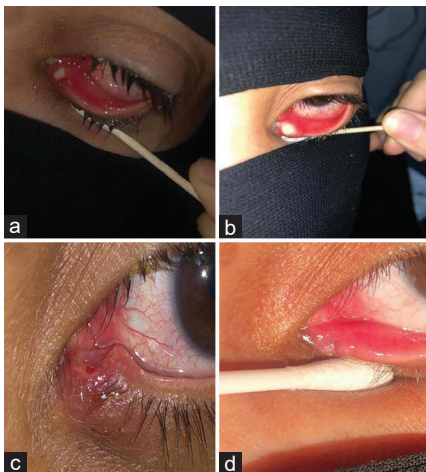


Figure 1: A case of necrotizing canaliculitis – (a) initial presentation; (b) 2 days later with worse presentation; (c) after debridement with clear deroofting of the proximal canaliculus with clinical improvement; (d) last presentation with resolution of symptoms

our case, the patient denied use of punctal plugs or lacrimal stents. Nevertheless, *P. aeruginosa* was found to be the cause of her condition with atypical presentation of ulceration of the proximal part of the lacrimal drainage system with the presence of necrotic tissue.

Surgical canaliculotomy with the removal of concretions is still considered the gold standard therapy in cases of canaliculitis.^[7] However, surgical intervention is not always needed in the management of these cases. In the previously cited study, out of 131 patients with canaliculitis, only 25.2% needed surgical intervention with canaliculotomy, while the other patients improved with other modalities, such as topical/systemic antibiotics, or irrigation of the lacrimal system with antibiotics.^[2] In our case, debridement of the necrotic tissue revealed that the inferior punctum was found to be open with deroofting of the proximal canalicular system, due to the aggressive nature of the infection. Therefore, canaliculotomy was not needed as antibiotics (local/topical and systemic) along with local povidone-iodine were solely enough to resolve the infection.

In conclusion, the rarity of canaliculitis, coupled with its various presenting symptoms and signs, can make the diagnosis challenging and require a high index of suspicion. *P. aeruginosa* has a recognizable association with punctal plugs and lacrimal stents, but it is a rare cause of primary canaliculitis. The presence of canalicular ulceration and tissue necrosis is an atypical presentation of primary canaliculitis. Therefore, more studies describing these unusual findings would open the door for more comparative studies in future.

Declaration of patient consent

The authors certify that they have obtained all appropriate patient consent forms. In the form the patient(s) has/have given his/her/their consent for his/her/their images and other clinical information to be reported in the journal. The patients understand that their names and initials will not be published and due efforts will be made to conceal their identity, but anonymity cannot be guaranteed.

Financial support and sponsorship

Nil.

Conflicts of interest

There are no conflicts of interest.

REFERENCES

1. Huang YY, Yu WK, Tsai CC, Kao SC, Kau HC, Liu CJ. Clinical features, microbiological profiles and treatment outcome of lacrimal plug-related canaliculitis compared with those of primary canaliculitis. *Br J Ophthalmol* 2016;100:1285-9.
2. Gogandy M, Al-Sheikh O, Chaudhry I. Clinical features and bacteriology of lacrimal canaliculitis in patients presenting to a tertiary eye care center in the Middle East. *Saudi J Ophthalmol* 2014;28:31-5.
3. Anand S, Hollingworth K, Kumar V, Sandramouli S. Canaliculitis: The incidence of long-term epiphora following canaliculotomy. *Orbit* 2004;23:19-26.
4. Baldursdóttir E, Sigurdsson H, Jónasson L, Gottfredsson M. Actinomycotic canaliculitis: Resolution following surgery and short topical antibiotic treatment. *Acta Ophthalmol* 2010;88:367-70.
5. Freedman JR, Markert MS, Cohen AJ. Primary and secondary lacrimal canaliculitis: A review of literature. *Surv Ophthalmol* 2011;56:336-47.
6. Chou YP, Yeh PH, Tsai YJ, Yen CH, Hsiao CH. Infectious keratitis secondary to canaliculitis with concretions: A case report. *Medicine (Baltimore)* 2019;98:e17444.
7. Pavilack MA, Frueh BR. Through curettage in the treatment of chronic canaliculitis. *Arch Ophthalmol* 1992;110:200-2.