



Radiological differential diagnosis and management of retroperitoneal hematomas posterior to radical inguinal orchiectomies. A case report

Santiago Escobar-Urrejola^a, Gastón Astroza^b, Felipe Del Valle^b, Alberto Fuentes^b,
Álvaro Zúñiga^{c,1,*}

^a Emergency Department, Hospital Sótero del Río, Avenida Concha y Toro 3459, Puente Alto, Región Metropolitana, 81500000, Chile

^b Urology Department, Pontificia Universidad Católica de Chile, Diagonal Paraguay 362, Santiago, Región Metropolitana, 8320000, Chile

^c Urology Department, Clínica Santa María, Avenida Sana María 500, Providencia, Región Metropolitana, 7500000, Chile

ARTICLE INFO

Keywords:

Orchiectomy
Postoperative complications
Hematoma
Therapy
Differential diagnosis

ABSTRACT

Introduction: Retroperitoneal hematomas are rare complications of radical inguinal orchiectomy. This case report discusses their radiological differential diagnosis and management.

Case presentation: A radical inguinal orchiectomy was performed on a 27-year-old patient. After discharge, he referred back pain. Computed tomography showed a retroperitoneal hematoma. A conservative approach was decided.

Discussion: Traditionally, retroperitoneal hematomas have been considered possible radiologic pitfalls, which has therapeutic implications. This pitfall seems less likely in contemporary clinical practice.

A conservative approach is preferred in stable patients, whereas active management should be offered to unstable patients.

Conclusion: Future studies are necessary to offer evidence-based therapeutical options.

Introduction

Radical inguinal orchiectomy has been the standard of treatment for testicular masses with clinical suspicion of malignancy since the 1940's. It is considered a safe procedure, with low perioperative complication rates. Among these, retroperitoneal hematoma secondary to testicular artery hemorrhage has been classically described. This is a rare complication, but with potential life-threatening outcomes due to persistent bleeding resulting in hemodynamic compromise or in the development of a compartmental syndrome.

The objective of this case report is to discuss the radiological differential diagnosis and the management of this lesion.

Case Presentation

A healthy 27 year old attended an outpatient clinic referring 2 months of intermittent orchialgia. At physical examination he presented a painless indurated mass in the right testes. Multiple vascularized

nodular lesions were demonstrated in testicular ultrasound. Abdomen and pelvis computer tomography (CT) showed no signs of metastatic disease. Bloodwork revealed alpha fetoprotein of 1,1 ng/mL; human chorionic gonadotropin <2 mUI/mL and lactate dehydrogenase 173 U/L.

Given the suspicion of a testicular tumor of malignant origin, a radical inguinal orchiectomy with double ligation of the spermatic cord was performed. There were no intraoperative incidents or abnormal bleeding. 7 days after his discharge, he attended the emergency room (ER) referring back pain, with no other symptoms.

On admission to ER, he had a mild tachycardia and moderate abdominal and lumbar pain. His hematocrit was 28.8%. A CT scan was performed, showing a retroperitoneal hematoma of 14,6 cms. In its major diameter, anterior to the right psoas. Its distal end was in direct relation to the deep inguinal ring, with no evidence of active bleeding (Fig. 1). He was admitted to an intermediate care unit and, considering the patient's hemodynamic stability, a conservative approach was decided. He was discharged after 3 days of continuous monitoring and

Abbreviations: CT, Computed tomography; MRI, Magnetic resonance imaging; ER, Emergency room.

* Corresponding author. Avenida Sana María 500, Providencia, Región Metropolitana, 7500000, Chile.

E-mail addresses: sescobar3@uc.cl (S. Escobar-Urrejola), gastroza@med.puc.cl (G. Astroza), fdelvallelorca@gmail.com (F. Del Valle), albfuentes.e@gmail.com (A. Fuentes), alzuniga@med.puc.cl (Á. Zúñiga).

¹ Part of the contributions of Dr Zúñiga to this article were done while he was affiliated to the Urology Department of the Pontificia Universidad Católica de Chile.

<https://doi.org/10.1016/j.eucr.2022.102020>

Received 30 December 2021; Received in revised form 29 January 2022; Accepted 29 January 2022

Available online 2 February 2022

2214-4420/© 2022 The Authors.

Published by Elsevier Inc.

This is an open access article under the CC BY-NC-ND license

(<http://creativecommons.org/licenses/by-nc-nd/4.0/>).

serial hematocrit testing, with no clinical nor laboratory evidence of persisting bleeding.

Since his discharge and to this date the patient has been asymptomatic, with no evidence of new episodes of bleeding or tumoral relapse. Notably, there has been a slow size decrease of the retroperitoneal hematoma upon radiologic follow-up. 10 months after the surgery a 26 mm lesion persists in the retroperitoneal compartment.

Discussion

During the dissection of the spermatic cord in radical inguinal orchidectomies, the testicular artery may retract towards its anatomical origin in the abdominal aorta. Hence, the artery may not be included in the spermatic cord ligature, leading to persistent bleeding through the inguinal canal into the retroperitoneum.

Retroperitoneal hematomas usually present with non-specific symptoms, such as abdominal pain or distention, back pain, dizziness, fever, sweating and cutaneous hematomas. Mild hypotension and tachycardia that improves with fluid administration should also alert physicians.¹ Clinicians should have a high index of suspicion regarding retroperitoneal hematomas as they can rapidly develop hemodynamic compromise or a compartmental syndrome.

Traditionally, retroperitoneal hematomas have been considered possible radiologic pitfalls in post-surgical patients without prior radiological studies. Hematomas density decrease with time, resulting in a radiological pattern that may be interpreted as tumoral masses in CT images.² This has led to unnecessary chemotherapy in reported cases,³ which is especially relevant considering that hematomas can disappear slowly, as in the case described above, and can thus be interpreted as relapses in surveillance images.²

Fortunately, there are clinical and radiological findings that can help to differentiate hematomas and metastases. Patients with hematomas typically develop hypotension, tachycardia, and drops in hemoglobin count, which are not common with non-complicated metastases. In the unusual case of subclinical hematomas discovered in surveillance imaging, some radiological features can help to differentiate both entities. Hematomas produce inflammatory changes in surrounding tissues that are not typically seen in metastases,⁴ and while hematomas size tends to decrease with time, metastases size tends to grow.

It should also be noted that this misdiagnose was mainly reported in studies done in the 1980's and 1990's, with older CT scan models and with less access to magnetic resonance (MRI) for further clinical evaluation. Considering the improvements on scanner technology in the last decades and the wider use of MRI, it seems less likely in contemporary clinical practice. The extended use of pre-operative imaging also

diminishes the probability of this misdiagnose. Ordering CT Scans in patients with high clinical suspicion of malignancy could avoid this confusion altogether. In the last 20 years there has been no cases of this misdiagnose in our urology department and, to our knowledge, there has been just one case report describing it during this period.²

Even though retroperitoneal hematomas are well-known complications of pelvic surgeries and several femoral-access vascular procedures, there is a lack of evidence-based guidelines regarding their management, due to a paucity of well-designed studies.

In the reviewed literature and in our center, a conservative approach is preferred when patients remain hemodynamically stable and with no significant nor persistent hemoglobin drop. Conservative management entails clinical observation and monitoring, intravenous fluid, blood transfusion if necessary and laboratory follow-up. Nonetheless, a subgroup of patients are admitted or evolve with hemodynamic or laboratory instability. An active approach is preferred in this group, with interventional radiology or open surgery. This stability-based treatment is similar to some proposals regarding retroperitoneal hematoma management in blunt trauma, where surgery should be considered in cases expanding hematomas, pulsatile masses or uncontained abdominal masses.⁵

Interventional radiology has had an important growth during the past years and is gaining acceptance as the first step in active management of retroperitoneal hemorrhage, showing promising efficiency in bleeding control with a low rate of complications. Surgical management should be preferred in unstable patients without a clear bleeding site, in patients with compartmental syndrome or in case of failure or unavailability of interventional radiology¹ (Fig. 2).

Conclusion

Retroperitoneal hematoma is a rare and potentially life threatening complication of radical orchidectomy. There is a lack of studies to sustain evidence-based clinical guidelines. We described a stepwise management approach, based on the current knowledge of its clinical characteristics. Future studies are necessary to offer patients and clinicians evidence-based therapeutical options.

Funding sources

This research did not receive any specific grant from funding agencies in the public, commercial, or not-for-profit sectors.

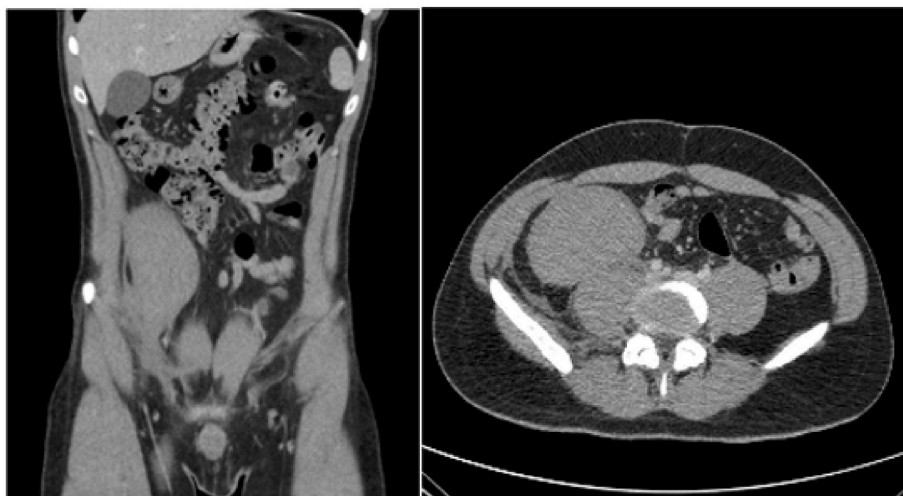

Fig. 1. Admission CT scan.

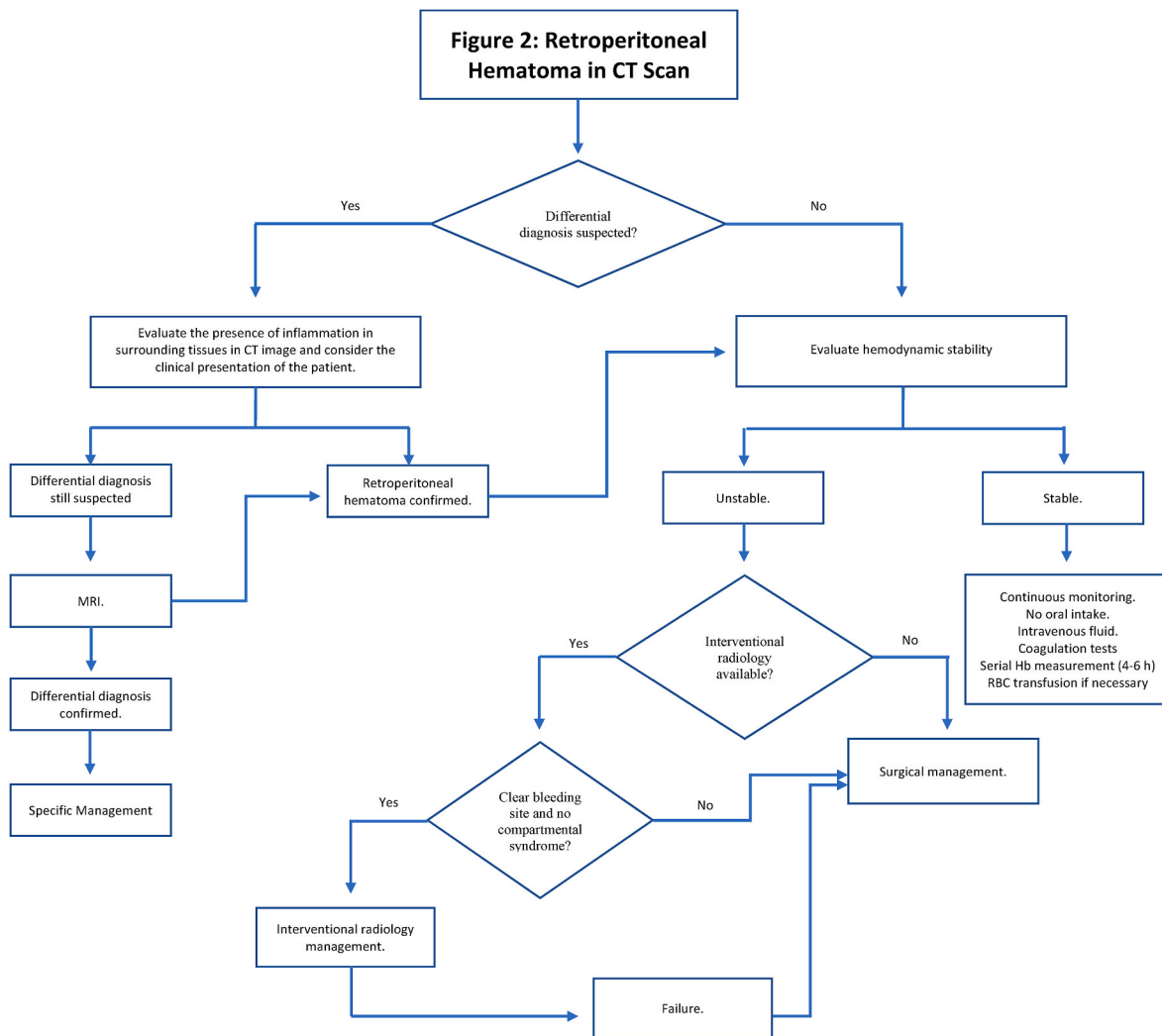


Fig. 2. Post-Surgical retroperitoneal hematoma management algorithm proposal.

Declaration of competing interest

None.

References

1. Chan YC, Morales JP, Reidy JF, Taylor PR. Management of spontaneous and iatrogenic retroperitoneal haemorrhage: conservative management, endovascular intervention or open surgery?. *Oct Int J Clin Pract.* 2008;62(10):1604–1613. PubMed PMID: 17949429. Epub 2007/10/19. eng.
2. Glicksman R, Hamilton RJ, Chung P. Retroperitoneal hematoma following radical orchiectomy: two cases, 2017 Jan-Feb *Can Urol Assoc J.* 2017;11(1-2). E35-E7. PubMed PMID: 28163811. PMCID: PMC5262509. Epub 2017/01/12. eng.
3. Bochner BH, Lerner SP, Kawachi M, Williams RD, Scardino PT, Skinner DG. Postradical orchiectomy hemorrhage: should an alteration in staging strategy for testicular cancer be considered?. *Sep Urology.* 1995;46(3):408–411. PubMed PMID: 7660521. eng.
4. Kennedy C, Harland C, Watson G, Parker C. Retroperitoneal haematoma and pelvic haematoma following orchidectomy. *Jan Br J Radiol.* 1991;64(757):72–73. PubMed PMID: 1998845. eng.
5. Wang F. The diagnosis and treatment of traumatic retroperitoneal hematoma. *Apr Pak J Med Sci.* 2013;29(2):573–576. PubMed PMID: 24353579. PMCID: PMC3809226. eng.