

Ultrasound-guided Intraarticular Hip Injection for Osteoarthritis Pain in the Emergency Department

Erik S. Anderson, MD
Andrew A. Herring, MD
Caitlin Bailey, MD
Daniel Mantuani, MD
Arun D. Nagdev, MD

Alameda County Medical Center, Highland Hospital, Department of Emergency Medicine, Oakland, California

Supervising Section Editor: Rick McPheeters, DO

Submission history: Submitted October 8, 2012; Revisions received December 18, 2012; Accepted February 15, 2013

Full text available through open access at http://escholarship.org/uc/uciem_westjem

DOI: 10.5811/westjem.2013.2.13966

Ultrasound-guided intraarticular hip corticosteroid injections may be useful for emergency care providers treating patients with painful exacerbations of osteoarthritis of the hip. Corticosteroid injection is widely recommended as a first-line treatment for painful osteoarthritis of the hip. Bedside ultrasound is readily available in most emergency departments; however, using ultrasound to guide therapeutic hip injections has not yet been described in emergency practice. Herein, we present the first description of a successful emergency physician-performed ultrasound-guided hip injection of local anesthetic and corticosteroid for pain control in a patient with an acute exacerbation of osteoarthritis. [West J Emerg Med. 2013;14(5):505–508.]

INTRODUCTION

Hip osteoarthritis (OA) is a common painful condition in the emergency department (ED). It is estimated that one in four people will develop painful hip OA in their lifetime.¹ Acute exacerbations of painful hip OA can be severe and disabling, often presenting a clinical challenge for emergency physicians (EP). Intraarticular corticosteroid hip injection is a well-established and effective treatment used extensively by rheumatologists, orthopedists, and pain physicians.² Landmark-based techniques of intraarticular injections are technically difficult with a relatively high failure rate and are associated with inadvertent neurovascular injury.³ Over the past decade, ultrasound-guided intraarticular hip injection has emerged as a safe and efficacious alternative to landmark techniques.^{4-6,8} Despite the evidence for the efficacy and excellent safety profile of ultrasound-guided hip corticosteroid injections as a first-line treatment for acute OA pain, this technique has never been described in emergency medicine practice.

Entering the hip joint space can be technically challenging due to its depth and proximity to the femoral neurovascular bundle. Fluoroscopy, which has been shown to be relatively safe and accurate, requires significant resource allocation and introduces the risk associated with exposure to ionizing radiation. Also, fluoroscopy does not visualize soft tissue or neurovascular structures.^{2,3} As a result, the ultrasound-guided technique for hip joint injections has been widely accepted as

a safe and effective alternative by interventional radiologists, pain physicians, and orthopedists.⁴⁻¹²

Within emergency medicine, diagnostic ultrasound-guided hip arthrocentesis for cases of suspected septic joint has been recently described.¹³⁻¹⁵ Herein we present the first description of EP-performed ultrasound-guided native hip injections for pain control.

METHODS

Ultrasound-guided technique

Preparation

An ultrasound system (Sonosite M-Turbo Bothell, Washington) is positioned contralateral to the affected hip with the screen in the line of sight of the operator. The skin overlying the hip should be cleaned in a sterile manner.

Survey Scan

A low-frequency curvilinear probe (5-2 MHz), covered with an adhesive sterile dressing, is placed in a transverse plane parallel to the inguinal ligament and used to identify the femoral artery and vein above the hyperechoic femoral head. The probe is then moved laterally to just above the hyperechoic femoral head and rotated to an oblique sagittal position so that the probe marker is aimed towards the umbilicus. The femoral head, femoral neck, anterior capsular recess, and ileofemoral ligament should be visualized.

Table 1. Ultrasound-guided intraarticular hip injection in the emergency department.

Emergency care indications	Pain from osteoarthritis and other degenerative disease of the hip.
Ultrasound-guided technique	Low frequency curvilinear transducer is used to visualize hip joint and target the anterior synovial recess for injection.
Positioning	Supine with hip slightly abducted and internally rotated.
Needle approach	In-plane approach with a 20-22 gauge 3.5 inch standard cutting spinal needle.
Important anatomy	Inguinal crease, femoral neurovascular bundle, and the anterior synovial recess.
Potential complications	Significant complications are rare. Flare of chronic pain and an increased risk of post-operative infection is possible if total hip arthroplasty is done within 3-4 months of injection. ¹² Local irritation, and puncture of the femoral artery or vein are possible but have not been reported with ultrasound guidance.

Needle insertion and injection. A superficial wheal of local anesthetic is placed at the point of planned needle entry. A 6ml mixture of 5ml of bupivacaine 0.5% and 1ml of 40mg/ml of triamcinolone is placed in a 10cc syringe. A 20-gauge 3.5 inch standard cutting spinal needle is guided in-plane under real-time ultrasound guidance to the anterior capsular recess (Figure). When the needle tip is clearly visualized in the joint space, 1-2 mL aliquots of the solution is slowly injected under low pressure. Successful targeting of the joint space is confirmed by spread of anechoic fluid under the ileofemoral ligament within the anterior capsular recess.

Disposition

Only a short period of observation is necessary as the volume of local anesthetic is quite small. It is, however, possible that inadvertent partial femoral nerve blockade could result and all patients should demonstrate full muscle strength before discharge.

CASE PRESENTATION

A 47-year-old male presented to the ED with an acute flare of his chronic severe left hip due to osteoarthritis. He was being followed as an outpatient by the orthopedic service and was scheduled for an upcoming fluoroscopy-guided therapeutic hip injection. He complained of 8/10 pain in the left hip that was significantly limiting his daily functioning. In conjunction with orthopedics consultation and after informed consent, the left hip was injected according to the previously stated technique. At follow up 1 week later, the patient reported significant improvement in his pain and increased daily activity without evidence of infection.

DISCUSSION

We present the first description of an ultrasound-guided injection for pain relief from osteoarthritis of the hip by an EP. In the ED there are few options for treating patient's pain from osteoarthritis and other forms of degenerative hip disease. The American College of Rheumatologists has no recommendations for control of pain in the acute

care setting. They do, however, recommend oral pain medications and intraarticular cortisone injections as initial treatment in outpatient practice.¹⁶ Not only is osteoarthritis of the hip common, patients with pain from osteoarthritis are more likely to visit EDs than patients without pain from hip osteoarthritis.^{1,17} The economic costs of disability from osteoarthritis are staggering – patients with pain have higher healthcare costs and higher economic costs from missed work and disability compared to patients without pain from osteoarthritis.¹⁷ With such a common, painful and costly problem presenting frequently to EDs, an approach to pain control with only oral pain medications may be limited. Oral medications such as NSAIDs and opiates are often inadequate and not without complications.^{18,19}

Hip injections with corticosteroids are not without potential complications. In a review of the literature by Kruse in *Current Reviews in Musculoskeletal Medicine* in 2008, there were 3 main clinically significant complications of intraarticular corticosteroid injection of the hip: septic arthritis, osteonecrosis, and infection of total hip replacement following pre-operative joint injection.¹² Of the 4 randomized controlled trials of imaging guided hip injections with corticosteroids involving 265 patients, no clinically significant adverse events were reported.¹² There were some minor side effects noted, such as flushing, flare of pain in the days following injection, and hyperglycemia.

The incidence of septic arthritis after hip injection has not been well studied, and only 2 case reports were found in the literature. One case details septic arthritis after a single injection, while in the second case it occurred after repeated injections of sodium hyaluronate and a single injection of triamcinolone.^{20,21} There is 1 case report of osteonecrosis after 1 injection of methylprednisolone, although it is unclear if this was due to disease progression or the steroid injection.²²

The injection of corticosteroids for pain control of hip osteoarthritis in the ED has not been studied or commented on in emergency medicine literature to our knowledge. The idea is not without potential concerns. Patients may present to EDs on a regular basis requesting injections for pain control,

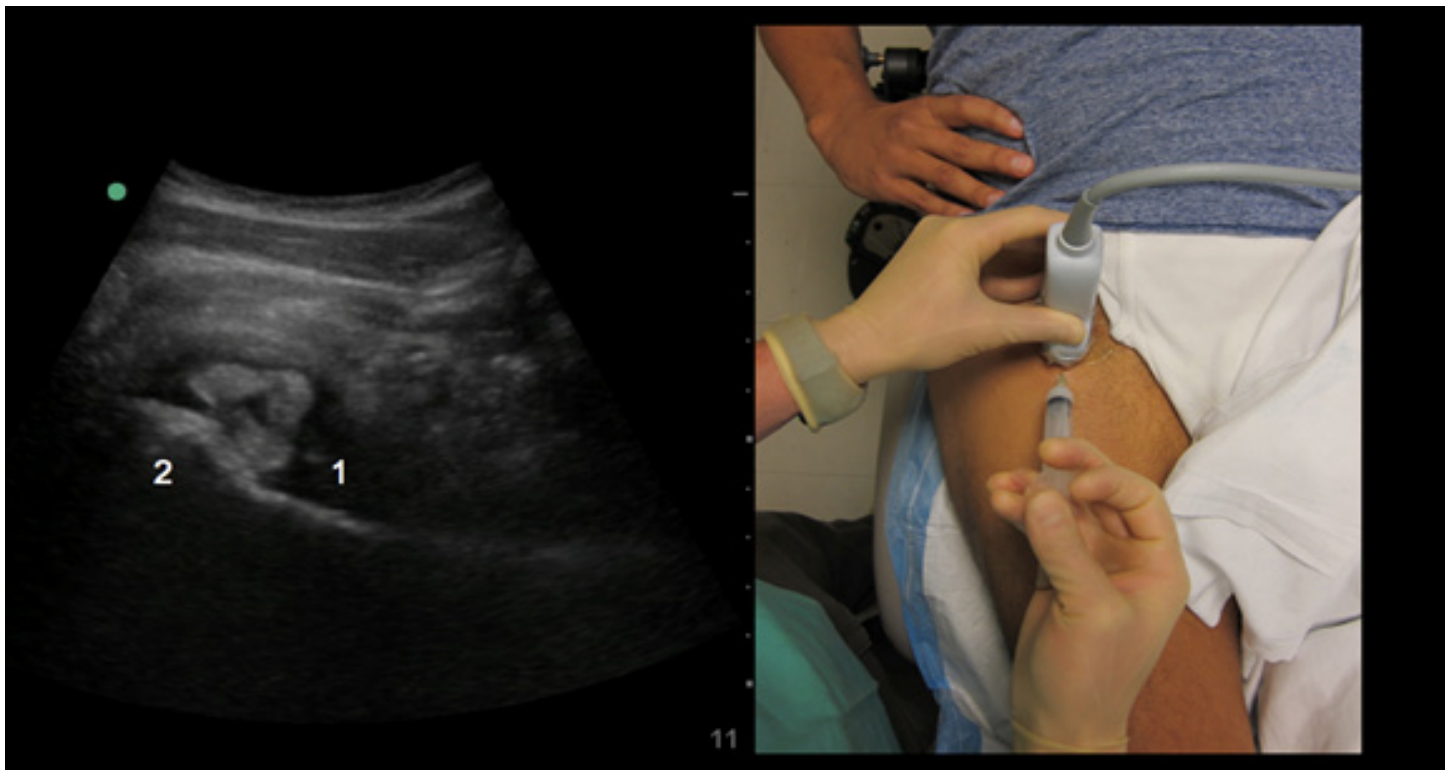


Figure. The needle tip (1) is noted under the iliofemoral ligament in the anterior synovial recess, with the femoral neck (2) in view. Injectate is deposited with a resultant spread of anechoic fluid.

and without the follow up and consultation of an orthopedist, this would be outside the standard of care for managing hip osteoarthritis. A patient presenting to the ED with hip pain has many more diagnostic and therapeutic considerations than a patient presenting with chronic hip pain to a subspecialty outpatient clinic.

Ultrasound-guided hip injections are commonly performed in the outpatient clinic and could easily be transferred to the ED for pain control in the properly selected patient.⁵⁻⁸ Emergency providers familiar with point-of-care ultrasound can become proficient in this procedure, which has proven to be safe in office-based settings.⁷⁻⁸ We present a case of an alternative technique for pain reduction in patients with clinical signs and symptoms of chronic OA of the hip. In conjunction with consultative services, this novel technique may be a potentially useful method to reduce pain from OA in the ED setting.

Address for Correspondence: Erik S. Anderson, MD, Alameda County Medical Center, Department of Emergency Medicine, 1411 E 31st St, Oakland, CA 94602. Email: esoremanderson@gmail.com.

Conflicts of Interest: By the WestJEM article submission agreement, all authors are required to disclose all affiliations, funding sources and financial or management relationships that could be perceived as potential sources of bias. The authors disclosed none.

REFERENCES

1. Murphy LB, Helmick CG, Schwartz TA, et al. "One in four people may develop symptomatic hip osteoarthritis in his or her lifetime" *Osteoarthritis Cartilage*. 2010;18(11):1372-1379.
2. Margules KR. "Fluoroscopically directed steroid instillation in the treatment of hip osteoarthritis: safety and efficacy in 510 cases." *Arthritis Rheum*. 2001;44(10):2449-2450.
3. Leopold SS, Battista V, Oliverio JA. "Safety and Efficacy of Intraarticular Hip Injection Using Anatomic Landmarks" *Clin Orthop Relat Res*. 2001;391:192-197.
4. Lambert RG, Hutchings EJ, Grace MG, et al. "Steroid Injection for Osteoarthritis of the Hip: A Randomized, Double-Blind, Placebo Controlled Trial." *Arthritis Rheum*. 2007;56(7):2278-2287.
5. Smith J, Murdle MF. "Office Based Ultrasound-Guided Intra-Articular Hip Injection: Technique for Physiatric Practice" *Arch Phys Med Rehabil*. 2006;87(2):296-298.
6. Sofka Saboeiro G, Adler RS. "Ultrasound-guided Adult Hip Injections" *J Vasc Interv Radiol*. 2005;16(8):1121-1123.
7. Caglar-Yagci H, Unsal S, Yagci I, et al. "Safety and efficacy of ultrasound-guided intra-articular hyaluron G-F 20 injection in osteoarthritis of the hip: a pilot study" *Rheumatol Int*. 2005;25(5):341-344.
8. Migliore A, Tormenta S, Martin Marin LS, et al. "Safety profile of 185 ultrasound-guided intra-articular injections for treatment of rheumatic diseases of the hip" *Reumatismo*. 2004;56(2):104-109.
9. Cavalier R, Herman MJ, Pizzutillo PD, et al. "Ultrasound-guided aspiration of the hip in children: a new technique." *Clin Orthop Relat Res*. 2003;(415):244-247.

10. Smith J, Hurdle MF, Weingarten TN. "Accuracy of Sonographically Guided Intra-articular Injections in the Native Adult Hip" *J Ultrasound Med*. 2009;28(3):329-335.
11. Micu MC, Bogdan GD, Fodor D. Steroid injection for hip osteoarthritis: efficacy under ultrasound guidance. *Rheumatology (Oxford)*. 2010;49(8):1490-1494.
12. Kruse DW. Intraarticular cortisone injection for osteoarthritis of the hip. Is it effective? Is it safe? *Curr Rev Musculoskelet Med*. 2008;1(3-4):227-233.
13. Freeman K, Dewitz A, Baker WE. "Ultrasound-guided hip arthrocentesis in the ED" *Am J Emerg Med*. 2007;25(1):80-86.
14. Smith SW. "Emergency Physician-performed Ultrasonography-guided Hip Arthrocentesis" *Acad Emerg Med*. 1999;6(1):84-86.
15. Tsung JW, Blaivas M. "Emergency Department Diagnosis of Pediatric Hip Effusion and Guided Arthrocentesis Using Point-of-Care Ultrasound" *J Emerg Med*. 2008;35(4):393-399.
16. Hochberg M, Altman RD, April KT, et al. "American College of Rheumatology 2012 Recommendations for the use of Nonpharmacologic and Pharmacologic Therapies in Osteoarthritis of the Hand, Hip, and Knee" *Arthritis Care Res (Hoboken)*. 2012;64(4):465-474.
17. DiBonaventura MC, Gupta S, McDonald M, et al. "Evaluating the health and economic impact of osteoarthritis pain in the workforce: results from the National Health and Wellness Survey" *BMC Musculoskelet Disord*. 2011;12:83.
18. Tenenbaum J. "The epidemiology of non-steroidal anti-inflammatory drugs" *Can J Gastroenterol*. 1999;13(2):119-122.
19. Henry D, McGettigan P. "Epidemiology overview of gastrointestinal and renal toxicity of NSAIDs" *Int J Clin Pract Suppl*. 2003;(135):43-49.
20. Nallamshetty L, Buchowski JM, Nazarian LA, et al. Septic arthritis of the hip following cortisone injection: case report and review of the literature. *Clin Imaging*. 2003;27(4):225-228.
21. Chazerain P, Rolland D, Cordonnier C, et al. Septic hip arthritis after multiple injections into the joint of hyaluronate and glucocorticoid. *Rev Rhum Eng Ed*. 1999;66(7-9):436-437.
22. Yamamoto T, Schneider R, Iwamoto Y, et al. Rapid destruction of the femoral head after a single intraarticular injection of corticosteroid into the hip joint. *J Rheumatol*. 2006;33(8):1701-1704.