

Received: 2017.10.11  
Accepted: 2018.01.02  
Published: 2018.03.17

e-ISSN 1941-5923  
© Am J Case Rep, 2018; 19: 304-308  
DOI: 10.12659/AJCR.907494

## Living Donor Liver Transplantation for Wilson's Disease Associated with Fulminant Hepatic Failure: A Case Report

Authors' Contribution:  
Study Design A  
Data Collection B  
Statistical Analysis C  
Data Interpretation D  
Manuscript Preparation E  
Literature Search F  
Funds Collection G

ABCDEF 1,2 **Yu Huang**  
ABCDEF 1 **Mitsuhisa Takatsuki**  
ABCDEF 1 **Akihiko Soyama**  
ABCDEF 1 **Masaaki Hidaka**  
BDE 1 **Shinichiro Ono**  
BDE 1 **Tomohiko Adachi**  
BDE 1 **Takanobu Hara**  
BDE 1 **Satomi Okada**  
BDE 1 **Takashi Hamada**  
ADEFG 1 **Susumu Eguchi**

1 Department of Surgery, Nagasaki University Graduate School of Biomedical Sciences, Nagasaki City, Nagasaki, Japan  
2 Department of Hepatobiliary Surgery, Guangzhou First People's Hospital, Guangzhou Medical University, Guangzhou, Guangdong, P.R. China

**Corresponding Author:** Susumu Eguchi, e-mail: [sueguchi@nagasaki-u.ac.jp](mailto:sueguchi@nagasaki-u.ac.jp)  
**Conflict of interest:** None declared

**Patient:** Female, 17  
**Final Diagnosis:** Fulminant Wilson's disease  
**Symptoms:** General jaundice • malaise • abdominal pain  
**Medication:** —  
**Clinical Procedure:** ICU  
**Specialty:** Transplantology

**Objective:** Rare disease

**Background:** Liver transplantation is indicated for patients with Wilson's disease (WD) who present either with acute liver failure or with end-stage liver disease and severe hepatic insufficiency as the first sign of disease. However, almost all reported cases have been treated with death donor liver transplantation. Here we report the case of a patient with WD associated with fulminant hepatic failure (WD-FHF) who underwent living donor liver transplantation (LDLT).

**Case Report:** A 17-year-old female was diagnosed with WD-FHF based on high uric copper (10 603 µg/day, normal <100 µg/day), low serum ceruloplasmin (15 mg/dL, normal >20 mg/dL) and Kayser-Fleischer (K-F) corneal ring, and acute liver failure (ALF), acute renal failure (ARF) and grade 2 hepatic encephalopathy (HE). The model for end-stage liver disease (MELD) score was 35. Due to her critical condition, the patient underwent LDLT utilizing a right liver graft from her 44-year-old mother. The right hepatic vein (RHV) and inferior right hepatic vein (iRHV) were reconstructed. She developed severe liver dysfunction due to a crooked hepatic vein caused by compression from the large graft. To straighten the bend, a reoperation was performed. During the operation, we tried to relieve the compressed hepatic vein by adjusting the graft location, but the benefits were limited. We therefore performed stenting in both the RHV and iRHV on postoperative day 9. The patient gradually improved, exhibiting good liver and renal functions, and was finally discharged on postoperative day 114.

**Conclusions:** When WD-FHF deteriorates too rapidly for conservative management, LDLT is an effective therapeutic strategy.

**MeSH Keywords:** Hepatolenticular Degeneration • Liver Failure, Acute • Liver Transplantation

**Full-text PDF:** <https://www.amjcaserep.com/abstract/index/idArt/907494>



1569



—



2



3



22



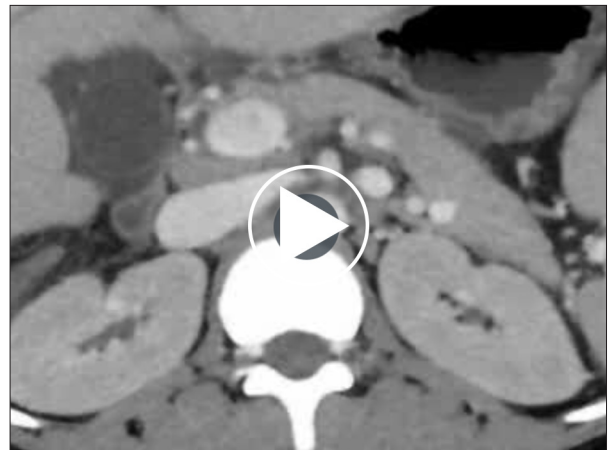## Background

Wilson's disease (WD) is an autosomal recessive inherited disorder of copper metabolism. It affects between one in 30 000 and one in 100 000 individuals, and the carrier frequency is approximately one in 90 [1]. This rare disease is caused by mutations in a gene encoding a copper-transporting P-type ATPase. Clinical manifestations of WD can present acutely with hepatic, neurologic, ophthalmic and/or psychiatric signs [2]. Although many drugs are available for WD [3], liver transplantation remains the only effective option [4]. Liver transplantation may correct the underlying hepatic metabolic defect [4], and has shown good long-term results even in cases with fulminant hepatic failure [5].

Knowledge of the efficacy of liver donor liver transplantation (LDLT) experience on WD associated with fulminant hepatic failure (WD-FHF) is insufficient because only rare cases have been treated with LDLT. In the United States, approximately 6% of patients undergo transplantation for WD-FHF [6,7], and almost all of these cases are treated with deceased donor liver transplants (DDLT) [8–11]. In Japan, about 129 patients (1.5%) have undergone LT for WD, and only two cases, both children, were reported with LDLT due to WD-FHF in 2002 [12]. Even though some cases have been analyzed retrospectively by many authors, our case may offer some valuable experience for the treatment of WD-FHF by LDLT, which could become a first-line option in Japan due to the high rate of LDLT cases in this country. In addition, our experience could also be important in countries with few LDLT cases that plan to increasingly utilize LDLT rather than DDLT in future treatment of WD.

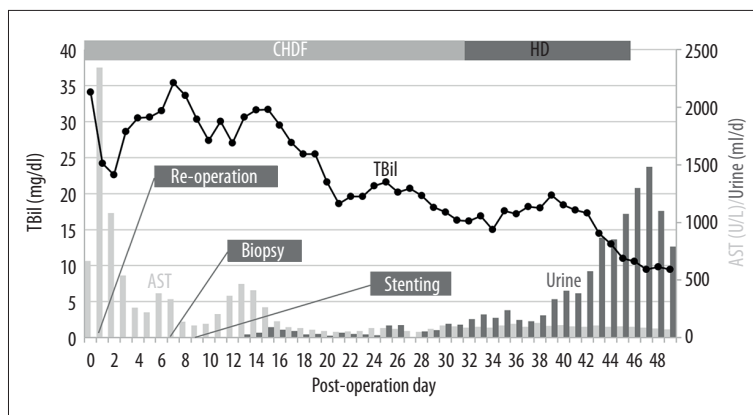
## Case Report

A 17-year-old female was admitted to a primary hospital presenting with acute abdominal pain, diarrhea, and malaise. After being diagnosed with acute liver failure, she was transferred to our hospital. She had no previous history of any liver disease

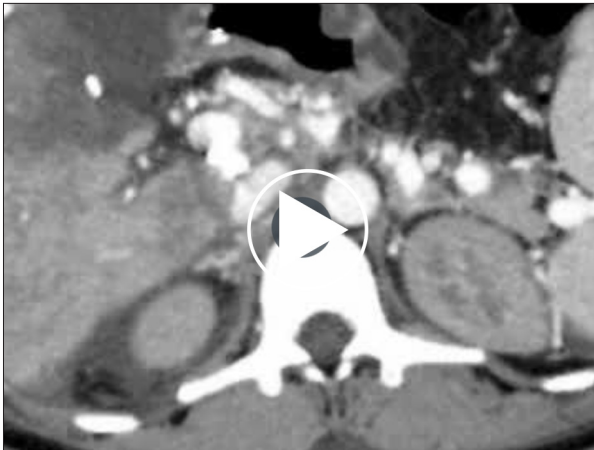


**Video 1.** Computed tomographic video before liver transplantation. Preoperative CT scanning showed splenomegaly and ascites, but without cirrhosis of this case.

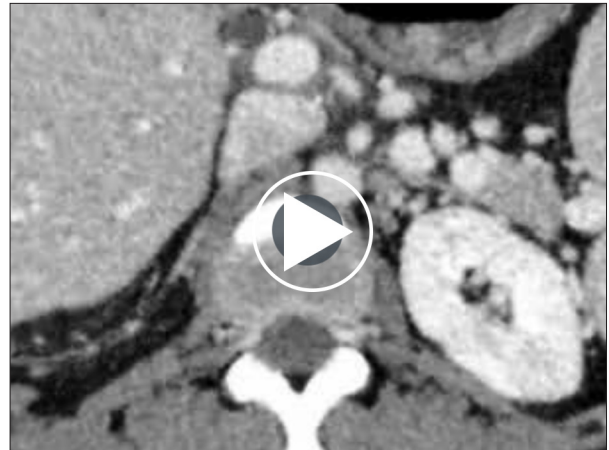or abdominal surgery. Her older brother, however, had previously been suspected of having WD. On examination, she appeared acutely ill, with progressive general jaundice and high fever, as well as a distended abdomen with massive ascites. The results of ophthalmic examination with K-F rings were typical, and there were no significant findings on neurological or neuropsychiatric examination. Laboratory examination showed leukocytosis ( $22\,800/\mu\text{L}$ ), low platelet count ( $2.3 \times 10^4/\mu\text{L}$ ), prolonged prothrombin time (23%), high total bilirubin (TBil) level (59.1 mg/dL), high uric copper level (10 603  $\mu\text{g}/\text{day}$ ), and low ceruloplasmin level (15 mg/dL). Preoperative CT scanning demonstrated splenomegaly and ascites, but no cirrhosis was identified (Video 1). Her Child-Pugh status was class C with 11 points, her MELD score was 35 points, and she developed grade 2 encephalopathy and anuria. Continuous hemodiafiltration and plasma exchange were started upon her transfer to the intensive care unit on day 3 of admission.



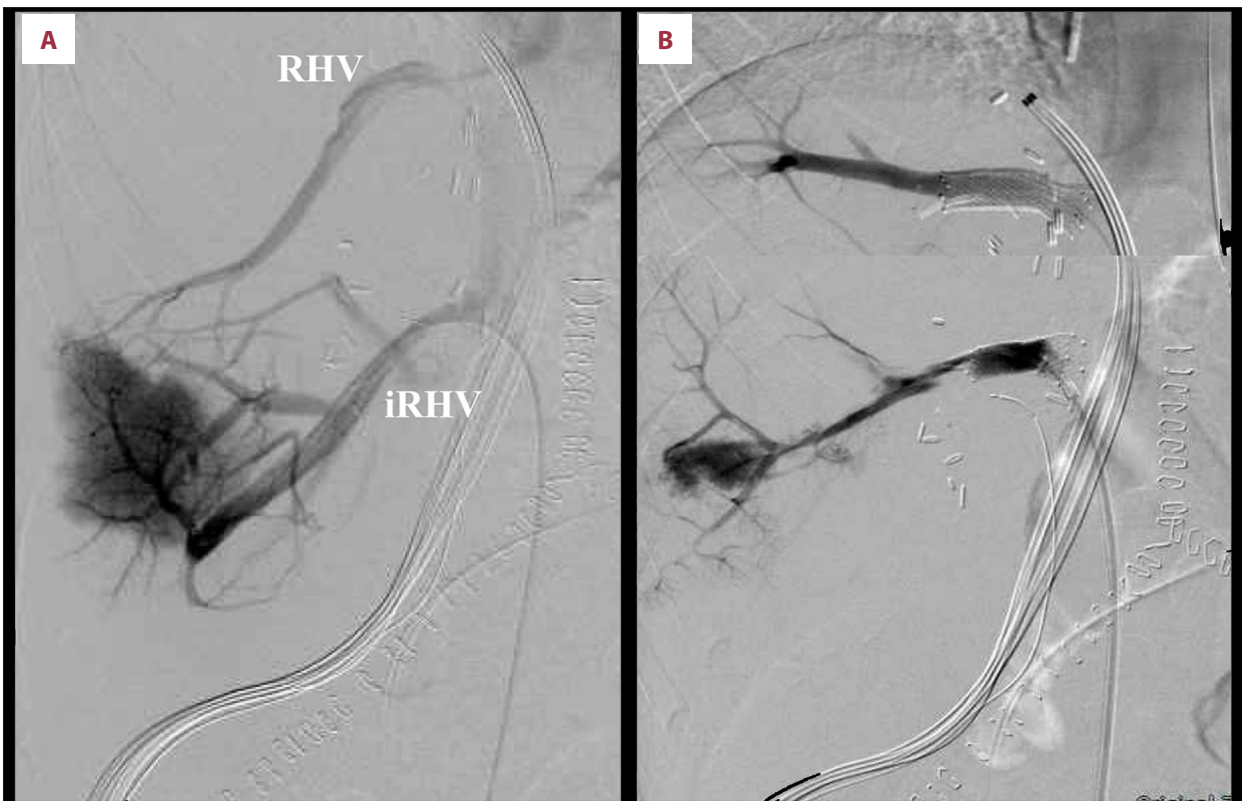
**Figure 1.** Post-transplant course in a WD patient associated with FHF in the first 50 days. She underwent reoperation on POD1, biopsy on POD7, and stenting on POD9. She was switched to HD on POD32, and HD was stopped after POD46. CHDF – continuous hemodiafiltration; HD – hemodiafiltration; TBil – total bilirubin; AST – aspartate aminotransferase; IVR – interventional radiology.



**Video 2.** Postoperative day 1 (POD1) computed tomographic video. POD1 CT scan showed compression of the iRHV due to the twisted venous anastomosis between the liver graft and inferior vena cava.



**Video 3.** Postoperative day 206 (POD206) computed tomographic video. POD206 CT scan showed no perfusion injury and the liver continued to grow satisfactorily.



**Figure 2.** Interventional radiology and stenting results on postoperative day 9. Interventional radiology showed compression of the RHV and iRHV before stenting (A) and good improvement after stenting (B).

### Perioperative management

Diagnosis of WD was easily established based on the presentation of typical K-F rings, lower ceruloplasmin level, and comparatively high uric copper concentration. LDLT was performed with an ABO blood type-identical right liver lobe offered by

her 44-year-old mother. The donor graft weighed 740 grams, equivalent to 63.4% of the recipient standard liver volume. The operation time was 831 minutes, and both the right hepatic vein (RHV) and inferior right hepatic vein (iRHV) were reconstructed and anastomosed to the recipient inferior vena cava, with 7169 milliliters of blood loss. However, the first day after

transplantation, the patient's serum AST/ALT levels increased dramatically (Figure 1), and lower hepatic venous perfusion was confirmed by ultrasonic examination. Postoperative CT scanning showed compression of the iRHV due to the twisted venous anastomosis between the liver graft and inferior vena cava (Video 2). To relieve this problem, she underwent an emergency reoperation. The twisted iRHV was confirmed during reoperation. We adjusted the position of the liver graft by lifting the caudal side of the liver toward the ventral side, and pulling down the graft head side to maintain the space from the right diaphragm. A rolled coil-like surgical packing material was inserted between the graft and the inferior vena cava. We also layered the omentum to lift the liver caudal side and maintain this position. Following the reoperation, however, the patient's liver function was not fully recovered. We excluded accelerated rejection by liver biopsy on postoperative day 7 (POD7). Interventional radiology with stenting was performed in both RHV and iRHV on POD9 (Figure 2). After stenting, her hepatic and renal function gradually improved, and hemodialysis was withdrawn on POD46. She was discharged on POD114. Reexamination by CT scan on POD206 showed no perfusion injury and the liver continued to grow satisfactorily thereafter (Video 3). The patient is currently doing well with good liver and renal functions, with urinary excretion of copper of 76 µg/day.

## Discussion

The great danger of WD is that it is progressive, and it is thought to be fatal if left untreated. The most difficult challenge is how to manage patients who deteriorate. Liver transplantation is the only effective option for those with WD who present with acute liver failure or FHF [13,14], and this approach may correct the underlying hepatic metabolic defect and generally shows good long-term results. Undoubtedly, prompt initiation of appropriate treatment – such as LDLT in our case – is paramount after the diagnosis of WD. After that, multidisciplinary cooperation and management are also of vital importance, and were particularly important in our patient, whose case deteriorated into multi-organ dysfunction.

In our case, we considered that LT was the best therapeutic solution based on the following points. 1) Disease severity assessment; the patient had acute onset and rapid progression. Her MELD score was 35, and her Child-Pugh score was 11. She suffered from ALF, AFR, and grade 2 hepatic encephalopathy. This situation, termed WD-FHF or fulminant Wilson's disease (FWD), would certainly have been life-threatening without proper intervention. ARF develops frequently in patients with FWD and typically resolves postoperatively [15]. Without urgent and expeditious LT, FWD is progressive and is uniformly fatal [15]. 2) Consideration of the medical therapeutic time window; the patient deteriorated so rapidly that we

did not have enough time to treat her with chelate. In view of the delay between the initiation of treatment and a measurable objective laboratory response, which is often a gap of 6–8 weeks or more, the previously recommended interval for a medical trial was 3 months [2]. Moreover, this 3-month recommendation may represent an underestimation, since some patients will deteriorate before several months have elapsed. Therefore, we believed that transplantation was more urgently needed. 3) The efficiency of LT; LT can reverse the basic metabolic abnormality in WD and improve both hepatic and neurologic symptoms [15–18], and LT is indicated in advanced cases with hepatic decompensation or in patients with FWD [19]. 4) Consideration of the damaging liver results; massive hepatocellular necrosis or apoptosis may result in FHF if long-accumulated copper is suddenly released [20]. Remarkably, she showed poor liver function as well as marked inflammatory changes as demonstrated by histopathology. Thus, chelators may hardly have been effective. 5) Availability of a liver donor resource; because of the shortage of deceased donors, living donors have been used as a major organ resource for LT in many countries. In LDLT, the donor is almost always a blood relative of the patient. More importantly, grafts chosen from heterozygote carriers do not appear to confer any risk of recurrence in recipients, at least in the short term [21]. In this case, the patient's mother was strongly motivated to offer part of her liver to save her daughter's life, which solved the problem of donor resources. 6) Consideration of neurologic impairment; LT can protect against neurologic deterioration irreversibly. Patients with neurologic abnormalities show significant improvement after LT [21]. In this case, the underlying neurologic impairment presented as a tremor. From this point of view, LDLT was imperative to protect from permanent irreversible neurologic impairments. 7) Consideration of the King's score and prognostic scoring system; according to the revised King's score, LT should be the first-line treatment for cases with a score of more than 11 points. Patients with FWD whose score was more than 7 will not survive without LT [22]. The presence of jaundice and ascites were the only clinical signs of prognostic value, since they are associated with a significantly higher mortality [22]. Her revised King's score was 14 points, and she presented with both jaundice and ascites. Considering all these considerations, we decided to perform an emergency LDLT.

Based on the present case, we recommend any case with unexplained liver disease with or without neurological or psychiatric symptoms should be evaluated for WD. WD should be suspected in any patient presenting with FHF with modest elevations in serum aminotransferases, low serum alkaline phosphatase, and a ratio of alkaline phosphatase to bilirubin of less than 2 [13,14]. Early LT should be considered for WD-FHF patients. In the technical point of view in this case, the stenting of venous anastomosis was effective, so that we propose this technique for the stricture of hepatic venous anastomosis.

## Conclusions

In conclusion, it is of paramount importance that a diagnosis of WD-FHF be considered as early as possible. LDLT is a curative procedure for WD-FHF. Multidisciplinary cooperation and management are also of vital importance for every patient, and especially those who rapidly deteriorate into multi-organ

dysfunction. Our valuable experience on FWD treatment with LDLT might be beneficial to groups having little or no experience with LDLT who plan to increase their use of LDLT in the future.

## Conflicts of interest

None.

## References:

1. Cheng F, Li G-Q, Zhang F et al: Outcomes of living-related liver transplantation for Wilson's disease: A single-center experience in China. *Transplantation*, 2009; 87: 751–57
2. Ala A, Walker AP, Ashkan K et al: Wilson's disease. *Lancet*, 2007; 369: 397–408
3. Ferenci P, Czlonkowska A, Stremmel W et al: EASL Clinical Practice Guidelines: Wilson's disease. *J Hepatol*, 2012; 56: 671–85
4. Catana AM, Medici V: Liver transplantation for Wilson disease. *World J Hepatol*, 2012; 4: 5–10
5. Lankarani KB, Malek-Hosseini SA, Nikeghbalian S et al: Fourteen years of experience of liver transplantation for Wilson's disease; A report on 107 cases from Shiraz, Iran. *PLoS One*, 2016; 11: 1–11
6. Schiodt F V, Atillasoy E, Shakil AO et al: Etiology and outcome for 295 patients with acute liver failure in the United States. *Liver Transpl Surg*, 1999; 5: 29–34
7. Eisenbach C, Sieg O, Stremmel W et al: Diagnostic criteria for acute liver failure due to Wilson disease. *World J Gastroenterol*, 2007; 13: 1711–14
8. Jhang JS, Schilsky ML, Lefkowitz JH, Schwartz J: Therapeutic plasmapheresis as a bridge to liver transplantation in fulminant Wilson disease. *J Clin Apher*, 2007; 22: 10–14
9. Markiewicz-Kijewska M, Szymczak M, Ismail H et al: Liver transplantation for fulminant Wilson's disease in children. *Ann Transplant*, 2008; 13: 28–31
10. Morgan SM, Zantek ND: Therapeutic plasma exchange for fulminant hepatic failure secondary to Wilson's disease. *J Clin Apher*, 2012; 27: 282–86
11. Hilal T, Morehead RS: Fulminant Wilson's disease managed with plasmapheresis as a bridge to liver transplant. *Case Rep Med*, 2014; 2014: 672985
12. Komatsu H, Fujisawa T, Inui A, Sogo T et al: Hepatic copper concentration in children undergoing living related liver transplantation due to Wilsonian fulminant hepatic failure. *Clin Transplant*, 2002; 16: 227–32
13. Roberts EA, Schilsky ML: Diagnosis and treatment of Wilson disease: An update. *Hepatology*, 2008; 47: 2089–111
14. Roberts EA, Schilsky ML: A practice guideline on Wilson disease. *Hepatology*, 2003; 37: 1475–92
15. Emre S, Atillasoy EO, Ozdemir S, Schilsky M: Orthotopic liver transplantation for Wilson's disease: A single-center experience. *Transplantation*, 2001; 72: 1232–36
16. Medici V, Mirante VG, Fassati LR et al: Liver transplantation for Wilson's disease: The burden of neurological and psychiatric disorders. *Liver Transplant*, 2005; 11: 1056–63
17. Sutcliffe RP, Maguire DD, Muiesan P et al: Liver transplantation for Wilson's disease: Long-term results and quality-of-life assessment. *Transplantation*, 2003; 75: 1003–6
18. Eghtesad B, Nezakatgoo N, Geraci LC et al: Liver transplantation for Wilson's disease: A single-center experience. *Liver Transplant Surg*, 1999; 5: 467–74
19. Ferenci P, Sternlieb I: Wilson's Disease. *Clin Liver Dis*, 1998; 2: 31–49
20. Strand S, Hofmann WJ, Grambihler A et al: Hepatic failure and liver cell damage in acute Wilson's disease involve CD95 (APO-1/Fas) mediated apoptosis. *Nat Med*, 1998; 4: 588–93
21. Wang XH, Cheng F, Zhang F et al: Living-related liver transplantation for Wilson's disease. *Transpl Int*, 2005; 18: 651–56
22. Nazer H, Ede RJ, Mowat AP, Williams R: Wilson's disease: Clinical presentation and use of prognostic index. *Gut*, 1986; 27: 1377–81