

Successful retrieval of a broken circular mapping catheter after entrapment in the tricuspid valve apparatus



Qun-Shan Wang,^{*} Peng-Pai Zhang,^{*} Da-Xin Zhou,[†] Jian-Hua Yan,^{*} Jian Sun,^{*} Yi-Gang Li^{*}

From the ^{*}Department of Cardiology, Xinhua Hospital, Shanghai Jiaotong University School of Medicine, Shanghai, China, and [†]Department of Cardiology, Zhongshan Hospital, Fudan University, Shanghai, China.

Introduction

Invasive electrophysiology study and catheter ablation are relatively safe procedures with only rare complications. A circular mapping catheter is commonly used to localize abnormal foci within the atria and thoracic vein¹. Entrapment of the circular mapping catheter in the mitral valve (MV) apparatus has been reported previously by Wu et al,² who noted serious complications following the catheter retrieval procedure. In the present case, the circular catheter was inadvertently mispositioned into the right ventricle, entrapped, and broken in the tricuspid valve (TV) apparatus during the mapping of premature atrial complexes (PACs) from the right atrium (RA) in a patient with frequent episodes of palpitation who underwent a cardiac electrophysiology study (EPS) and eventually catheter ablation. In the present case report, we describe the successful retrieval of the fragment by a percutaneous transfemoral venous approach.

Case report

A 36-year-old female with a 10-year history of recurrent symptomatic palpitations was admitted to our hospital in December 2014. Examinations reviewed no signs of structural heart disease. Holter monitoring documented narrow complex tachycardia [197 beats per minute (bpm)] without visible P waves with coincident symptoms. Treatments with propafenone (450 mg/d, taken orally) and metoprolol (12.5 mg, every 12 hours, taken orally) were unsuccessful in preventing the recurrent tachycardia. The patient underwent an EPS in sinus rhythm. Short atrial runs and a number of intermittent PACs in forms of bigeminy were observed during the EPS. The CARTO 3 MEM (Biosense Webster, Diamond Bar, CA) was used for catheter navigation during the entire procedure. In all, 3 catheters (Biosense Webster) were used: quadripolar catheters were placed at the His-

bundle position and the right ventricular apex, and an octapolar catheter was placed at the coronary sinus. A 3.5-mm-tip cool saline-irrigated catheter (NaviStar ThermoCool, Biosense Webster) and a 7F 20-mm deflectable circular catheter equipped with ten 1-mm electrodes (Lasso, Biosense Webster) were introduced for activation mapping, geometry reconstruction, and ablation. Bipolar intracardiac electrograms were filtered (30–500 Hz) and obtained via an electrophysiology system (Labsystem Pro, Bard Electrophysiology, Lowell, MA).

Atrioventricular reentrant tachycardia (AVRT) was induced by catheter manipulation. Intracardiac recordings confirmed a concealed left-sided free-wall accessory pathway. The accessory pathway was successfully interrupted with radiofrequency catheter ablation by transseptal methods using a CARTO 3 electrophysiology navigation system. Biatrial activation mapping of the atrial tachycardia was performed using a circular multielectrode catheter. Three-dimensional endocardial activation mapping of both atria was performed during induced nonsustained atrial tachycardia (AT). Left atrial mapping was carried out via atrial septal puncture, and no abnormality was found. However, the RA activation map revealed early activation at the lateral part of the RA. After RA mapping, the circular mapping catheter was inadvertently advanced into the right ventricle, and it became immobile when we attempted to withdraw it back into the RA. Fluoroscopy revealed that the circular catheter tip was entrapped in the TV apparatus. Gentle traction of the catheter as well as clockwise and counterclockwise catheter rotation failed to free the catheter tip. During this maneuver, the circular part of the catheter broke from the shaft.

The patient was hemodynamically stable. We decided to retrieve the remnants of the catheter percutaneously. A single-snare technique was used initially. However, the remnants of the circular catheter were difficult to snare by way of femoral access, so the saline-irrigated catheter was then placed to anchor the broken catheter via internal jugular access. Although the proximal portion of circular catheter was snared, we could not retrieve the broken catheter, because the snare slipped up as soon as we tried to pull the assembly. (Figure 1A).

KEYWORDS Complication; Catheter ablation; Atrial tachyarrhythmia; Tricuspid valve apparatus; Broken catheter retrieval (Heart Rhythm Case Reports 2016;2:187–189)

Address reprint requests and correspondence: Dr Yi-Gang Li, Department of Cardiology, Xinhua Hospital, Shanghai Jiaotong University School of Medicine, Kongjiang Road 1665, 200092 Shanghai, China. E-mail address: drliyigang@outlook.com.

KEY TEACHING POINTS

- Complications associated with circular mapping catheter entrapment in the tricuspid valve (TV) apparatus include damage to the TV, which can be severe and may result in severe TV dysfunction or critical mitral or tricuspid regurgitation secondary to ruptured chordae tendineae.
- Surgical tricuspid valve repair or replacement or catheter removal should be considered; moreover, in a case of catheter entrapment, excessive traction should be avoided because it may result in damage to the TV apparatus.
- Using a double-snare technique in this patient, the broken lasso catheter entrapment in the TV apparatus was retrieved successfully and safely by way of a percutaneous transfemoral venous approach.

We then attempted to use a double-snare technique to solve this problem. A loop snare was introduced through the right femoral sheath and forwardly tightened by pushing the angiographic catheter (JR6.0-6F), thereby holding the proximal fragment. The distal portion was held by another loop snare (Figure 1B). Fortunately, our attempt was successful this time (Figure 1C). The catheter fragment was withdrawn through the inferior vena cava down into the pelvis. Thus, the whole assembly—the sheath, the snare loop, and the fractured fragment—was completely removed as a single unit from the femoral vein, and hemostasis was achieved. Subsequent echocardiographic examination revealed normal TV function without tricuspid regurgitation. No further attempt was made to manage the atrial arrhythmia(s). The patient was placed on beta blocker therapy and discharged, and her palpitation symptom was attenuated despite recurrent episodes of premature atrial contractions. During a

12-month follow-up after the procedure, no recurrence of supraventricular tachycardia was observed via 24-hour Holter monitoring.

Discussion

Catheter entrapment in the MV during atrial fibrillation ablation has been reported.² The catheter has a circular spine on which 10 or 20 electrodes are located. Entrapment of a circular mapping catheter at the mitral annulus is one of the most common etiologies of MV injury during catheter ablation.³ The resultant damage to the MV can be severe and may result in severe MV dysfunction.

Our case showed that a broken circular mapping catheter after entrapment in the TV apparatus could be removed without complication, but it should be recognized that the retrieval procedure is associated with a risk of thrombosis formation in the right ventricle and a resultant risk of pulmonary embolism; moreover, if the retrieval procedure accidentally damages the TV with resultant TV dysfunction or critical tricuspid regurgitation secondary to ruptured chordae tendineae, surgical TV repair or replacement should be considered.

After the circular mapping catheter was inadvertently advanced into the right ventricle and then entrapped and broken in the TV apparatus, we tried multiple techniques to retrieve the broken catheter.^{4,5} A single loop snare was used to pull the fractured catheter but failed. Finally, 2 loop snares were used to hold the catheter from proximal and distal portions. This technique is used more commonly in peripheral interventions such as carotid and peripheral vascular interventions. To the best of our knowledge, this is the first report of successful and safe retrieval of a broken circular mapping catheter after entrapment in the TV apparatus, via a percutaneous transfemoral venous approach.

Acknowledgments

This work was supported in part by the National Science Foundation of China (81270259).

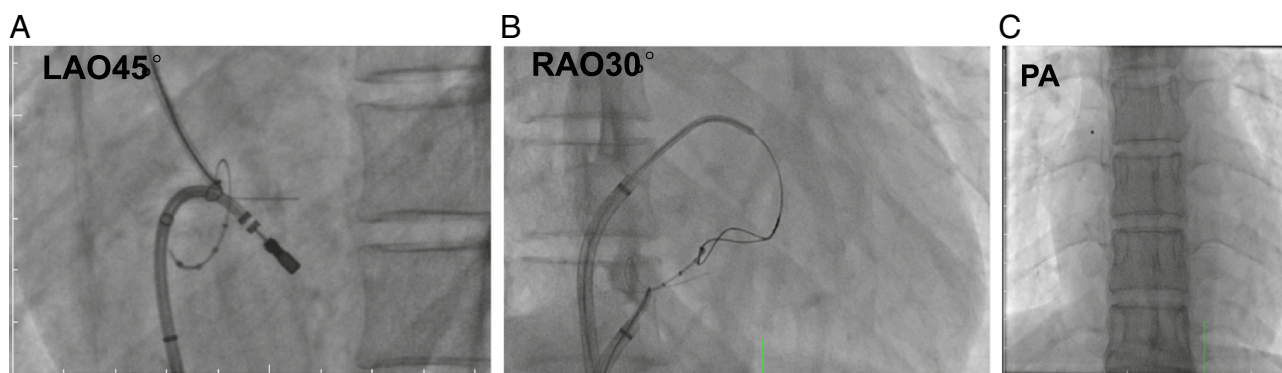


Figure 1 **A:** Left anterior view of the right atrium showing the circular remnants of the mapping catheter trapped in the tricuspid valve apparatus. **B:** The broken circular mapping catheter being snared by 2 snares. **C:** The whole assembly of sheath, snare loop, and the fractured fragment were removed.

References

1. Haïssaguerre M, Jais P, Shah DC, Garrigue S, Takahashi A, Lavergne T, Hocini M, Peng JT, Roudaut R, Clémenty J. Electrophysiological end point for catheter ablation of atrial fibrillation initiated from multiple pulmonary venous foci. *Circulation* 2000;101(12):1409–1417.
2. Wu R, Brinker J, Yuh D, et al. Circular mapping catheter entrapment in the mitral valve apparatus: a previously unrecognized complication of focal atrial fibrillation ablation. *J Cardiovasc Electrophysiol* 2002;13(8):819–821.
3. Desimone CV, Hu T, Ebrille E, Syed FF, Vaidya VR, Cha YM, Valverde AM, Friedman PA, Suri RM, Asirvatham SJ. Catheter ablation related mitral valve injury: the importance of early recognition and rescue mitral valve repair. *J Cardiovasc Electrophysiol* 2014;25(9):971–975.
4. Mansour M, Mela T, Ruskin J, Keane D. Successful release of entrapped circumferential mapping catheters in patients undergoing pulmonary vein isolation for atrial fibrillation. *Heart Rhythm*. 2004;1(5): 558–561.
5. Tavernier R, Duytschaever M, Taeymans Y. Fracture of a circular mapping catheter after entrapment in the mitral valve apparatus during segmental pulmonary vein isolation. *Pacing Clin Electrophysiol* 2003;26(8): 1774–1775.