

The benefits of navigated neuroendoscopy in children with multiloculated hydrocephalus

Sergei Afanasievich Kim, German Vladimirovich Letyagin, Vasiliy Evgenievich Danilin, Anna Alekseevna Sysoeva, Jamil Afetovich Rzaev, Galina Ivanovna Moisak

Department of Pediatric Neurosurgery, Federal State Budget Institution, Federal Center of Neurosurgery, Novosibirsk, Russia

ABSTRACT

Context: Multiloculated hydrocephalus remains one of the most challenging neurosurgical problems. In this study, we use frameless navigation during endoscopic interventions to improve the efficiency of operations.

Subjects and Methods: Nine navigated endoscopic procedures were performed in 8 children with various forms of multiloculated hydrocephalus from March 2013 to June 2014. Preoperatively, the optimal entry point for fenestration of several cysts was determined on the basis of magnetic resonance data. During surgery, rigid endoscope was registered in neuronavigation system for making the connection between separated ventricles and cysts. The final stage of the operation was to conduct a stent through the working channel of the endoscope for implantation of a shunt.

Results: Number of compartments interconnected by an operation ranged from 3 to 5. Seven interventions were performed simultaneously with the shunt implantation. The follow-up period ranged from 9 to 15 months. The clinical improvement as a result of the operation was achieved in all children. The follow-up included clinical examination and evaluation of magnetic resonance imaging. Additional surgery was necessary in two patients: The first 5 months later, the second 1-year after endoscopic intervention.

Conclusion: Application of frameless navigated neuroendoscopy makes this kind of operations the most efficient and safe for the patient.

Key words: Frameless navigation, multiloculated hydrocephalus, neuroendoscopy in children

Introduction

Multiloculated or multicompartamental hydrocephalus which represents a separation of ventricular system into isolated compartments remains one of the most challenging problems of neurosurgery. Information about its frequency is variable. Cipri and Gambardella reported 11 children with multilevel occlusion in a group of 57 patients with hydrocephalus, thereby multiloculated hydrocephalus was amounted 19%.^[1] In another study, authors reported 62 children with obstructive hydrocephalus, in 23 (37%) of whom multiloculated hydrocephalus was identified.^[2] This

separation may be either congenital or acquired (a consequence of hemorrhage or inflammation).^[3-5] Also, complications such as overdrainage or shunt infection occurring after implantation of the shunt system or the shunt revisions can also lead to the formation of compartmentalized hydrocephalus. Formed membranes and trabeculae impede the normal liquor circulation leading to the formation of isolated cavities such as isolated brain ventricle, intraventricular or intraparenchymal cysts. In turn, the growth of isolated cavity leads to brain compression and deformation of the ventricular system, thereby exacerbate the cerebrospinal fluid (CSF) circulation disorders. The aim of this study was to improve the results of surgical treatment of multiloculated hydrocephalus due to the combined use of endoscopic techniques and neuronavigation.

Subjects and Methods

Eight patients with various forms of multiloculated hydrocephalus were treated in our hospital from March 2013 to June 2014. Age of patients ranged from 1-month to 5 years.

Preoperative evaluation included an assessment of the neurological status, neurosonography, computed tomography-ventriculography, magnetic resonance imaging (MRI)

Access this article online	
Quick Response Code:	Website: www.asianjns.org
	DOI: 10.4103/1793-5482.165799

Address for correspondence:

Dr. Sergei Afanasievich Kim, 132/1, Nemirovicha-Danchenko Street, Novosibirsk 630087, Russia.
E-mail: neuroserjeon@mail.ru

of the brain. Localization of isolated cavities was as follows: The lateral ventricles (5 children), third ventricle (1), fourth ventricle (3), interhemispheric fissure (1), and cisterna ambient (3). In 4 children, endoscopic surgery was as a primary intervention, in 4 remaining cases-after ventriculoperitoneal (VP)-shunt performed previously. At the time of admission, 1 child had VP-shunt, in another 3 children previously implanted shunts were removed in connection with shunt infection. The formation of a multilevel occlusion in 7 children was due to ventriculitis, the separation of ventricular system in 1 child was diagnosed by means of a prenatal ultrasound examination.

In our clinic the equipment of company «KARL STORZ» was used for endoscopic procedures: Direct-viewing rigid ventriculoscope had an outer diameter of 6.1 mm, instrumental canal (diameter 2.9 mm), and two irrigation canals (diameter 1.6 mm). Rod-lens optics had viewing angles of 0°, 30°, and 45°. The pediatric neuroendoscope with an external diameter of 4.5 mm also was used and had working channel (diameter 1.3 mm) and two channels for irrigation and aspiration (diameter 1.0 mm). Prerequisite for endoscopy under neuronavigation control is reliable fixing the patient's head, excluding its accidental movement during manipulation. In our clinic, the head fixation in children over 5-year-old was performed using Mayfield clamp with special children's pins. In children under 5-year-old, a head was fixed by a clamp with pediatric horseshoe-shaped gel holders to prevent excessive pressure on the soft-tissue.

Before surgery thin slice MRI of the brain with preplaced markers on the head were performed. The obtained data were transferred to neuronavigation station which created a three-dimensional model of the patient's head. Preoperatively the optimal entry point for fenestration of several cysts was determined on the basis of magnetic resonance data. We also calculated the required length and the position of the catheter. After induction of anesthesia and fixation in the Mayfield clamp, the patient's head was registered in the navigation station. After covering the surgical field with sterile linen, we performed registration of rigid endoscope in the neuronavigation system. To this end, reflective spheres were strongly fixed to the endoscope. Thereby, the navigation station could track the three-dimensional position of the working part of the tool relative to the constructed images in real time. Most often, surgical approach was made through an enlarged lateral ventricle (6 patients). On the previously planned trajectory, we found cyst and perforated its wall. Through the resulting hole endoscope was brought into the cavity of the cyst and the rear wall was fenestrated under the navigation control. Thus, depending on the location of the cyst there was created fistula with isolated posterior horn of the ipsilateral lateral ventricle (two interventions), with the cavity of the contralateral lateral ventricle (3), or with isolated IV ventricle (3). If there were additional isolated cavities, the endoscope was put back into the lateral ventricle from the perforated cyst. After that, the trajectory was changed and under visual and navigation

control an interhemispheric cyst was identified. Then it was fenestrated through, thereby connection with the contralateral ventricle was created (one intervention). In two patients, the approach was performed directly across the cyst cavity. In one case inside the cavity of interhemispheric cysts, the areas close to both lateral ventricles were sought and at these points the fenestration was performed. In the second case, the cyst was perforated in places where it abutted to the opposite hemisphere or the isolated IV ventricle. In two cases, the additional intraoperative monitoring was carried out using an ultrasound scan through the anterior fontanelle. The final stage of the operation was to conduct a silicone stent with additional side holes through the working channel of the endoscope for the prevention of reocclusion. The distal end of the catheter was placed in the cavity of the IV ventricle (three cases), the opposite lateral ventricle (3) or in the dorsal horn of the ipsilateral ventricle (1). Further, the catheter passed through the cyst cavity into the lateral ventricle toward the burr hole. In one case, the stent was fixed with a ligature to the dura mater. In six patients, the stent was used as a ventricular catheter of the shunt system, which was installed after the endoscopic phase of the operation. In 1 child, the cyst recurrence of the opposite lateral ventricle caused a significant strain of the ventricular system and consequently the stent migration with a dysfunction of VP-shunt 1-year after the intervention. In this case, another endoscopic intervention with the formation of the connection between the cyst and lateral ventricles and with the replacement of the shunt system was performed.

Results

All the children achieved clinical improvement as a result of the intervention. Characteristics of performed operations are presented in Table 1.

Complications were observed in two cases (22.2%). In one child, the small subdural hematoma on the side of intervention was diagnosed after surgery without significant mass effect and did not require surgical intervention. In another child the displacement of the stent distal end from the cyst cavity into the lateral ventricle was seen, which did not disturb the drain through the shunt system and also did not require repeated surgery. There was not mortality in this group of patients. The regress of clinical manifestations was registered after operations [Table 2].

All children were discharged with the improvement. The average length of hospital stay after surgery was 9 days. In 1 child, VP-shunt was removed because of advanced shunt infection 5 months later after the operation. After the sterilization of CSF, shunt system was reinstalled.

Clinical case 1

The 7-month-old male child presented with an increased size of the head, vomiting, refusal to eat, fontanelle tension, respiratory failure.

Table 1: Characteristics of performed operations

Patient	Age	Sex	Number of connected compartments	Stent implantation	VP-shunt implantation	Complications
Sh.	1-year	Female	3	+	+	Subdural hematoma
O.	5 months	Male	5	+	+	-
V.	5 years	Male	3	+	+	-
Z.	3 years	Female	3	+	-	-
K.	11 months	Male	3	+	+	Stent migration
B.	7 months	Male	4	+	+	-
P.	7 months	Male	3	+	+	-
P.	1-year 7 months	Male	3	+	+	-
S.	1-months	Female	3	-	-	-

VP – Ventriculoperitoneal

Table 2: Dynamics of clinical manifestations in the postoperative period

Signs	Occurrence in the group before surgery (%)	Dynamics after surgery		
		No changes	Partial improvement (%)	Complete regression of symptoms (%)
Pathological increase in head circumference	7 (77.8)	-	-	7 (100)
Oculomotor disorders	8 (88.9)	-	5 (62.5)	3 (37.5)
Vomiting	4 (44.4)	-	-	4 (100)
Bulbar syndrome	3 (33.3)	-	1 (33.3)	2 (66.7)
Respiratory disorders	1 (11.1)	-	-	1 (100)
Seizures	7 (77.8)	-	4 (57)	3 (43)
Developmental delay	9 (100)	-	9 (100)	-

The child was born at 33–34 weeks in critical clinical condition. His Apgar score was 7/7. The artificial lung ventilation was started from the 2nd day of life, the convulsions were observed. At the 15th day after delivery, the child was transferred from the hospital to the newborn pathology department with purulent meningoencephalitis, ventriculitis, intraventricular hemorrhage, stage II, complicated with obstructive hydrocephalus. During stay in the ward, he received prolonged antibiotic therapy, valproic acid, acetazolamide. The child was discharged at the age of 4 months. At the age of 5 months, the child was hospitalized to the local neurosurgery department where the VP-shunt was installed. One month after that the revision and removal of VP-shunt and installation of external drainage were made because of the shunt dysfunction. After removal of the drainage, the patient was discharged and referred to our clinic. The last 3 days before admission: the child demonstrated severe deterioration: Reduction of motor activity, complete rejection of food and drink, vomiting, reducing the breath frequency. The child immediately was hospitalized in the children's department of our clinic with a serious condition. The child was asleep and adynamic. The neurological examination revealed bradypnea 12/min with periods of apnea lasting 10–15 s, exotropia, Graefe's sign, sluggish motor response on inspection and painful stimuli, pseudobulbar syndrome, central moderate tetraparesis. His head had hydrocephalic shape and circumference 53 cm. The anterior fontanelle had size 6 cm × 6 cm and was tense.

Magnetic resonance imaging showed multiloculated occlusive hydrocephalus with isolated cysts of III and IV ventricles [Figure 1].

An urgent endoscopic intervention was performed using the neuronavigation, which resulted in the interconnected lateral ventricles and cysts of III and IV ventricles. Through the formed holes the silicone stent was placed into the III and IV ventricles and used as a ventricular catheter of VP-shunt [Figure 2].

The clinical improvement including the regression of intracranial hypertension, improving of general condition, normalization of respiratory function, shifting from tube feeding to oral feeding, reduction of oculomotor disturbances, appearance of emotional reactions were seen postoperatively. The patient was discharged in good condition.

Clinical case 2

The 1-year-old child presented with an increase of head circumference, anxiety, prolonged monotonous cry, seizures, refusal to eat, gagging when swallowing.

At 1.5 months of life, the child was operated concerning posthemorrhagic hydrocephalus and VP-shunt was implanted. Two months later the shunt was removed and external ventricular drainage was installed because of shunt infection. VP-shunt was reinstalled after the sterilization of CSF. The patient was discharged with improvement and had been regularly accompanied. Two months after that the shunt infection re-emerged and the repeated shunt removal with the installation of external drainage was performed. The child had taken prolonged antibiotic therapy and after the sterilization of CSF the drainage was removed and the child was discharged.

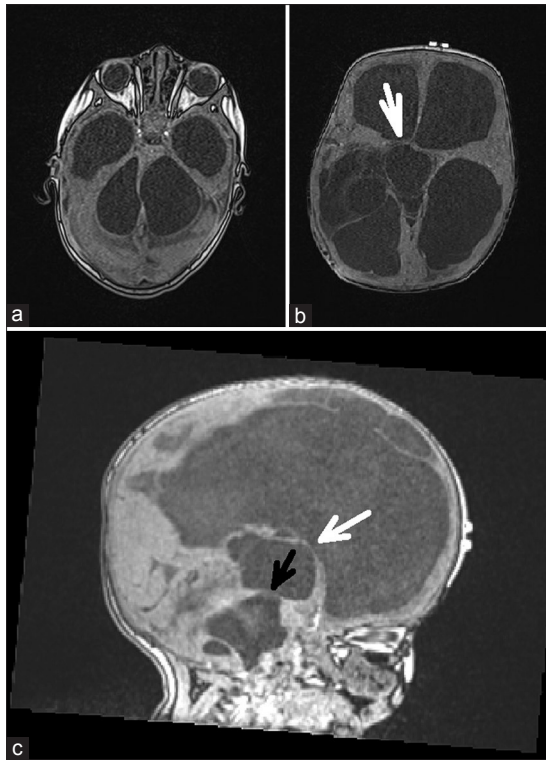


Figure 1: Case 1. Magnetic resonance imaging of the brain before surgery showed cysts of III and IV ventricles, several widening of the lateral ventricles. (a) The picture shows the septum divided the IV ventricle into two separate chambers. (b) The white arrow indicates the direction of the endoscope at perforating the anterior wall of the cyst of the III ventricle. (c) The black arrow points to the application site of connection with isolated IV ventricle

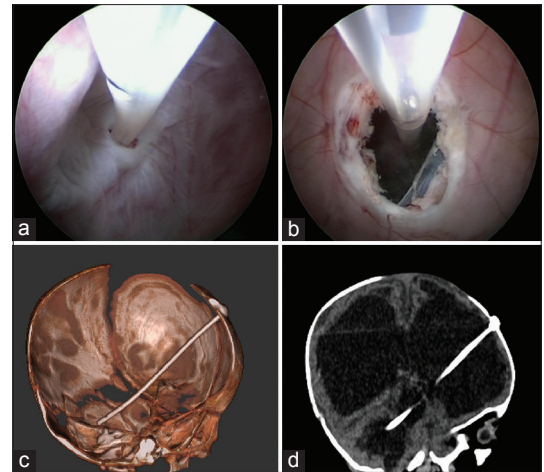


Figure 2: Case 1. Intraoperative photographs. (a) The endoscope is inside of cavity of III ventricle cyst. The rear wall of the cyst separated this chamber from the IV ventricle was perforated and the wall inside the IV ventricle was fenestrated. Into the cavity of the IV ventricle installed silicone catheter. (b) The endoscope was removed from the III ventricle cyst into the right lateral ventricle. A hole in the front wall of the cyst is seen. The catheter follows from the IV ventricle through the III ventricle into the right lateral ventricle. (c and d) The postoperative computed tomography of the brain shows the stent for connecting IV, III, and lateral ventricles

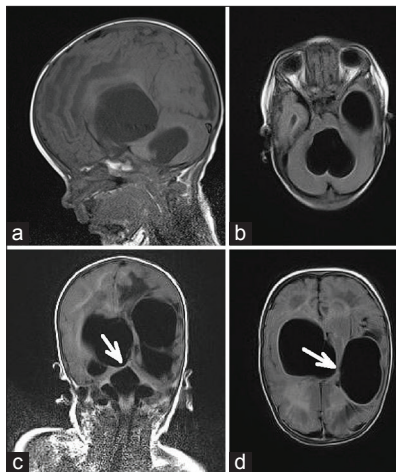


Figure 3: Case 2. (a and b) Magnetic resonance imaging of the brain before surgery showed the isolated cysts of the right and left hemispheres and IV ventricle. (c) The direction of the endoscope for perforation the rear cyst wall, which separated it from the IV ventricle. (d) After creation a fistula to the IV ventricle, the endoscope was returned into the cyst of the right hemisphere and the trajectory was changed in the direction to the cyst of the left hemisphere (the arrow)

At the time of admission, the child's condition was of moderate severity. The child was alert, he was crying and had restlessness during the examination. His head circumference

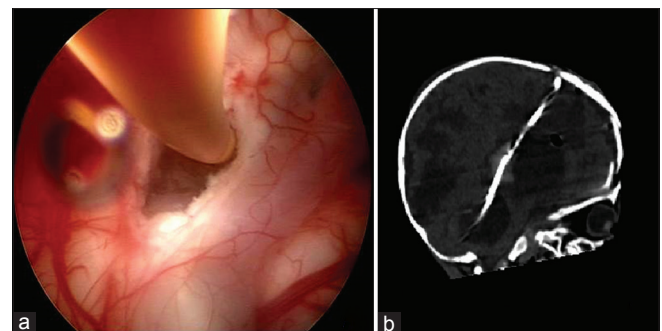


Figure 4: (a) Intraoperative photograph: the endoscope is inside a cyst of the right hemisphere. The perforated rear wall of the cyst through which the silicone catheter goes into IV ventricle is seen. (b) The postoperative computed tomography of the brain shows the stent which drains IV ventricle and cyst

was 46.5 cm, a large fontanelle had size 2 cm × 2 cm and was tense. On neurological examination exotropia, reduced of active movements in the left limbs, left mild hemiparesis were revealed. The tracking eyes response was not clearly identified. The patient had nasogastric tube feeding because of gagging when swallowing.

The MRI revealed polycystic brain with isolated cysts of the right and left hemispheres and IV ventricle [Figure 3].

The patient underwent endoscopic intervention using the intraoperative frameless navigation, in which the connection between the cysts of the left and right hemispheres and the IV ventricle cyst was created. The installation of shunt system and the drainage of the IV ventricle cysts and cerebral hemispheres were performed simultaneously [Figure 4].

The regression of intracranial hypertension and bulbar disorders, improving of general condition, the relief of seizures was noted after surgery and the tube feeding was changed to oral feeding with gradual volume food expansion. The patient was discharged in good condition.

Discussion

Hydrocephalus today remains one of the most common diseases faced by neurosurgeons worldwide. The patients with different variants of multiloculated hydrocephalus when the sequestration of the ventricular system into multiple isolated chambers occurs definitely are the most difficult group. Standard implantation of a shunt system in these cases does not bring positive results. There is still no consensus which method of surgery should be preferred as the most effective and safe.^[2,6-14] The most common method of the VP-shunting can require implantation of several shunts and multiple revisions.^[14-17] Another option is to perform stereotactic aspiration of cysts and make interconnections between them.^[17,18] It is also possible to perform microsurgical dissection of cysts using transcallosal or transcortical approach.^[19,20] In our opinion, neuroendoscopic intervention in these patients is the most promising method of surgery.^[2,21-23] In some cases, endoscopy allows to remove a previously implanted shunt system or save from shunt implantation.^[2,11,21] However, when conducting such operations neurosurgeons often have difficulty in planning and intraoperative orientation in conditions of impaired anatomy and lack of landmarks. Using the navigation at such interventions can significantly ease the task of the surgeon and improve the efficiency of the operation.^[24-26] The combined use of endoscopic techniques and frameless navigation saved us from the need for multiple approaches and allowed to establish communication between several cavities and stop the progression of hydrocephalus in a single step. Through the implementation of the intervention all patients in our group achieved an improvement that confirms a rather high efficiency of this type of interventions. Furthermore, the presence of intraoperative navigational control allowed us to minimize the risk of damage to critical structures such as large vessels, functionally important areas, and the brain stem. Complications noted in 2 patients (22%) were not significant and did not affect the overall favorable outcomes.

Conclusion

The endoscopic surgery is the current treatment of choice for multiloculated hydrocephalus. The application of navigation during endoscopic interventions makes this kind of surgery the most effective and safe for the patients. The combination of minimally invasive endoscopic approach and neuronavigation facilitates the preoperative planning and intraoperative orientation in distorted cerebral anatomy and lack of normal brain landmarks. The endoscopic stenting of formed connections

ensures adequate catheter position and prevents the recurrence of occlusion. The aim of operation is the drainage of the maximum possible numbers of cavities using minimal amounts of the proximal catheter and shunts systems. In some cases, this type of surgery allows the patients to avoid the shunting.

References

1. Cipri S, Gambardella G. Neuroendoscopic approach to complex hydrocephalus. Personal experience and preliminary report. *J Neurosurg Sci* 2001;45:92-6.
2. Simernitsky BP, Petraki VL, Prityko AG. To the discussion of surgical tactics in children with multilevel occlusive hydrocephalus. *J Quest Neurosurg* 2006;1:22-6.
3. Albanese V, Tomasello F, Sampaolo S. Multiloculated hydrocephalus in infants. *Neurosurgery* 1981;8:641-6.
4. Kalsbeck JE, DeSousa AL, Kleiman MB, Goodman JM, Franken EA. Compartmentalization of the cerebral ventricles as a sequela of neonatal meningitis. *J Neurosurg* 1980;52:547-52.
5. Reinprecht A, Dietrich W, Berger A, Bavinzski G, Weninger M, Czech T. Posthemorrhagic hydrocephalus in preterm infants: Long-term follow-up and shunt-related complications. *Childs Nerv Syst* 2001;17:663-9.
6. Kuschel YV, Korshunov AE. Ventriculo-subarachnoid shunting of isolated IV ventricle: Surgical technique and long-term outcomes. *J Pediatr Neurosurg Neurol* 2005;3:58-64.
7. Petraki VL, Simernitsky BP, Prityko AG, Asadov RN, Kulikovskij PV, Klimchuk OV, Rjabkova MG, et al. Experience in the use of endoscopic techniques in surgical interventions on the isolated IV ventricle in children. *J Pediatr Neurosurg Neurol* 2011;2:30-52.
8. Petraki VL, Simernitsky BP, Asadov RN. Isolated IV ventricle: The use of endoscopic techniques to create an alternative way of communication between the III and IV ventricles due to occlusion of cerebral aqueduct. Description of the case. *J Pediatr Neurosurg Neurol* 2009;3:4:49-53.
9. Rabandiyarov MR, Akshulakov SK, Hachtryan VA. Experience in the use of atypical CSF shunt surgery in patients with hydrocephalus with multilevel block of cerebrospinal fluid pathways. *Russ Polenovs Neurosurg J* 2013;5:272.
10. Hachtrjan VA, Bersnev VP, Safin ShM, Orlov JuA, Trofimova TN. Hydrocephalus: Pathogenesis, diagnosis, surgical treatment. SPb.: Izd. RINH 1998. p. 230.
11. El-Ghandour NM. Multiloculated hydrocephalus: A study of 24 patients operated by endoscopic cyst fenestration. *J Neurosurg* 2006;59:477.
12. El-Ghandour NM. Complex hydrocephalus. In: Pant S, editor. *Hydrocephalus*. Croatia: In Tech; 2012. p. 167-88.
13. Rhoton AL Jr, Gomez MR. Conversion of multilocular hydrocephalus to unilocular. Case report. *J Neurosurg* 1972;36:348-50.
14. Schultz P, Leeds NE. Intraventricular septations complicating neonatal meningitis. *J Neurosurg* 1973;38:620-6.
15. Gaeviy OV, Artaryan AA, Vorobiev IA, Shablya VV. Hydrocephalus complicated by cystic formations in children. *J Russ Neurosurg* 2000;1-2:71-2.
16. Rabandiyarov MR. Modified CSF shunt operations: Early and late postoperative outcomes. *Russ Polenovs Neurosurg J* 2013;5:20.
17. Ross DA, Muraszko K, Dauser R. A special cyst puncture catheter for use in thick-walled or mobile intracranial cysts. *Neurosurgery* 1994;34:191-2.
18. Mathiesen T, Grane P, Lindquist C, von Holst H. High recurrence rate following aspiration of colloid cysts in the third ventricle. *J Neurosurg* 1993;78:748-52.
19. Nida TY, Haines SJ. Multiloculated hydrocephalus: Craniotomy and fenestration of intraventricular septations. *J Neurosurg* 1993;78:70-6.
20. Sandberg DI, McComb JG, Krieger MD. Craniotomy for fenestration of multiloculated hydrocephalus in pediatric patients. *Neurosurgery* 2005;57:100-6.
21. El-Ghandour NM. Endoscopic cyst fenestration in the treatment of multiloculated hydrocephalus in children. *J Neurosurg Pediatr* 2008;1:217-22.
22. Spennato P, Cinalli G, Ruggiero C, Aliberti F, Trischitta V, Cianciulli E,

- et al.* Neuroendoscopic treatment of multiloculated hydrocephalus in children. *J Neurosurg* 2007;106:29-35.
23. Lewis AI, Keiper GL Jr, Crone KR. Endoscopic treatment of loculated hydrocephalus. *J Neurosurg* 1995;82:780-5.
24. Konovalov AN, Potapov AA, Gavrilov AG, Shurkhai VA, Goryainov SA, Gol'bin DA, *et al.* Neuronavigational systems and Intraoperative neuro visualisation. In: Konovalov AN, editor. *Modern Technologies and Clinical Researches in Neurosurgery*. Vol. 1. Moscow: Izd. IP T. A. Alekseeva 2012. p. 66-75.
25. Paraskevopoulos D, Biyani N, Constantini S, Beni-Adani L. Combined intraoperative magnetic resonance imaging and navigated neuroendoscopy in children with multicompartmental hydrocephalus and complex cysts: A feasibility study. *J Neurosurg Pediatr* 2011;8:279-88.
26. Schulz M, Bohner G, Knaus H, Haberl H, Thomale UW. Navigated endoscopic surgery for multiloculated hydrocephalus in children. *J Neurosurg Pediatr* 2010;5:434-42.

How to cite this article: Kim SA, Letyagin GV, Danilin VE, Sysoeva AA, Rzaev JA, Moisak GI. The benefits of navigated neuroendoscopy in children with multiloculated hydrocephalus. *Asian J Neurosurg* 2017;12:483-8.

Source of Support: Nil, **Conflict of Interest:** None declared.