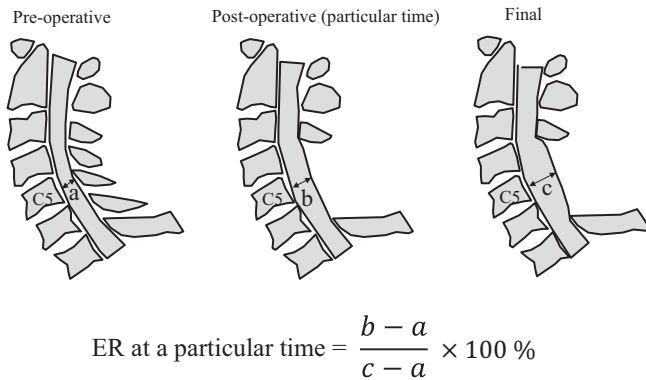




### Expansion ratio (ER)



**Figure 1.** Anteroposterior (AP) diameter and expansion ratio (ER) of the dural tube. AP diameter of the dural tube was measured at mid-level of the C5 vertebral body on T2 sagittal image.

### Materials and Methods

We retrospectively examined 83 patients who underwent muscle-preserving selective laminectomy of three consecutive laminae between C4 and C6 for cervical myelopathy, with a minimum of 2-year follow-up between 2012 and 2014. Sagittal alignment of the cervical spine was measured in a neutral position at C2-7 using the Cobb method on lateral radiographs. Neck range of motion (ROM) was assessed on the basis of differences in the C2-7 angles from flexion to extension. We measured C2-7 sagittal vertical axis (SVA), which was defined as the deviation of the C2 plumb line (extending from the centroid of the C2 vertebra) from the posterior-superior corner of the vertebral body of C7, with positive sagittal alignment defined as an anterior deviation. C2-7 angles, ROM, and C2-7 SVA were measured pre-operatively and at final follow-up. All measurements were conducted by three spine surgeons.

Cervical alignment was determined on the basis of pre-operative neutral radiographs using a classification system proposed by Kamata et al<sup>8)</sup>. Anteroposterior (AP) diameter of the dural tube was measured at the mid-level of C5 vertebral body on T2 sagittal image pre- and post-operatively. This measurement was conducted in the plane vertical to the axis of the dural tube (Fig. 1). Expansion ratio (ER) was defined as the extent of expansion at a particular time divided by the final extent of expansion of the dural tube diameter (Fig. 1). The time-dependent transition of ER was analyzed among five periods: pre-operative, within 6 months after the surgery, between 6 months and 1 year after the surgery, between 1 and 1.5 years after the surgery, and at final follow-up. Operative outcomes were examined using the Japanese Orthopaedic Association (JOA) scores.

#### Statistical analysis

Data are expressed as mean  $\pm$  standard deviation. We used one-way analysis of variance (ANOVA) for analyzing statistical differences in data obtained from radiographs. Re-

peated measures ANOVA was used to compare AP diameter of the dural tube, the extent of expansion of the AP diameter, and ER at different periods. After assessing the significance of ANOVA, pairwise comparisons with a Tukey-Kramer test were conducted. Correlations between AP diameter of the dural tube and radiological factors were analyzed using Pearson's correlation coefficient. The outcome of JOA scores was analyzed using Wilcoxon signed-rank test. All statistical analyses were conducted with a commercially available software program (SPSS 24.0; SPSS, Chicago, IL, USA). A  $p$ -value of  $<0.05$  was considered significant.

### Results

The mean age of patients was 62.3 years, and the average follow-up period was 2 years and 9 months. There were 57 male and 26 female patients. Pathogenesis of myelopathy was cervical spondylotic myelopathy in 62 patients, cervical ossification of the posterior longitudinal ligament in 16, cervical spondylotic amyotrophy in 4, and cervical disk herniation in 1. Numbers of cases classified by the cervical curvature were 28 for lordosis, 21 for straight, 11 for sigmoid, and 23 for kyphosis.

#### C2-7 angle, ROM, and C2-7 SVA

Averaged C2-7 angles were  $9.4^\circ \pm 12.4^\circ$  pre-operatively and  $8.4^\circ \pm 13.0^\circ$  ( $p = 0.2$ ) at the final follow-up. Averaged ROM were  $33.7^\circ \pm 11.9^\circ$  pre-operatively and  $30.4^\circ \pm 10.7^\circ$  ( $p < 0.05$ ) at the final follow-up. ROM significantly decreased after the surgery. Averaged SVA were  $18.6 \pm 11.0$  mm pre-operatively and  $20.8 \pm 12.2$  mm ( $p < 0.05$ ) at the final follow-up. SVA significantly increased after the surgery.

#### AP diameter of the dural tube

Transition of parameters such as AP diameter of the dural tube, the amount of expansion of the dural tube, and ER are shown in Table 1. AP diameter of the dural tube and ER significantly increased until 1 year after surgery. ER classified according to the cervical curvature at 6 months after surgery is shown in Table 2. ER in cases with kyphosis at 6 months was significantly lower than that in cases without kyphosis. An illustrative case is represented in Fig. 2.

#### Correlations between AP diameter of the dural tube and radiological factors

Correlations between AP diameter of the dural tube and C2-7 angles, ROM, or C2-7 SVA are shown in Table 3. Final extent of the expansion of AP diameter and the final AP diameter of the dural tube were mildly correlated with pre- and post-operative C2-7 angles. ROM and C2-7 SVA were not correlated with the final extent of expansion of AP diameter. Final C2-7 SVA was mildly correlated with pre-operative AP diameter.

**Table 1.** Anteroposterior Diameter of the Dural Tube and Expansion Ratio.

	Pre-OP	6 months	1 year	1.5 years	Final	Repeated measures ANOVA
AP diameter of dural tube (mm)	8.5±1.1*	12.4±1.8*	13.3±1.9*	13.6±2.3	13.7±2.2	<i>p</i> <0.001
Extent of expansion of AP diameter (mm)		2.8±1.8**	4.7±2.0	5.2±2.2	5.1±2.0	<i>p</i> <0.001
Expansion ratio (%)		74.8±20.5**	91.2±15.8	94.9±13.5	100	<i>p</i> <0.001

\*Statistically significant difference among three durations (Tukey-Kramer test, *p*<0.05)

\*\*Statistically significant difference to the other durations (Tukey-Kramer test, *p*<0.05)

ANOVA, analysis of variance; AP, anteroposterior; pre-OP, pre-operative

**Table 2.** Expansion Ratio at 6 Months after the Surgery Classified with Cervical Curvature.

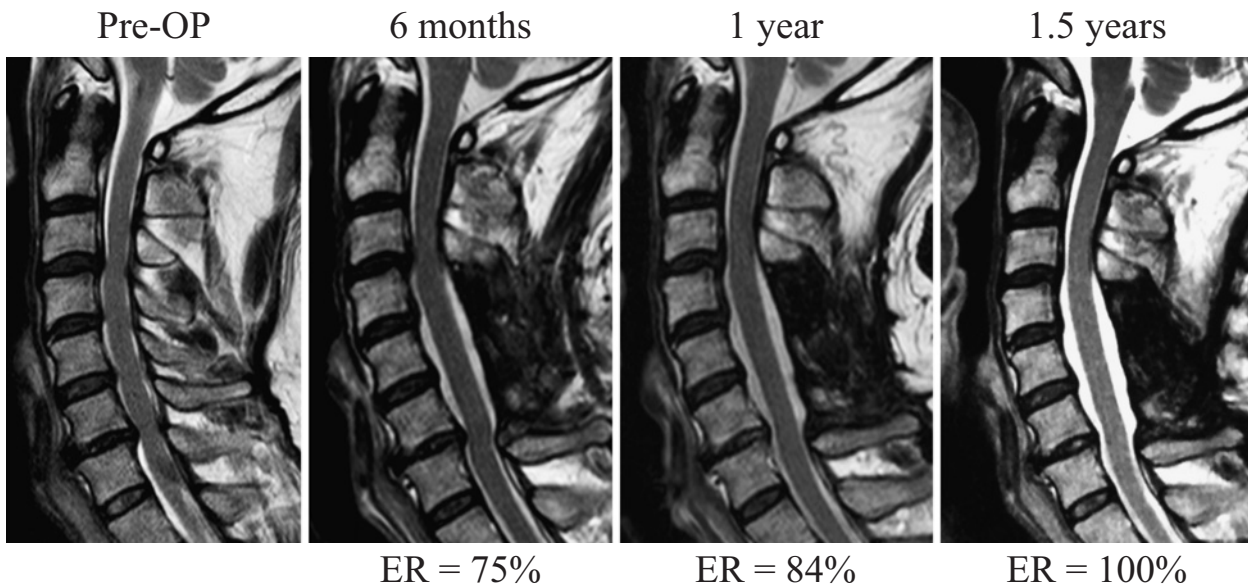
	Lordosis (N: 28)	Straight (N: 21)	Sigmoid (N: 11)	Kyphosis (N: 23)	ANOVA
ER (%) at 6 months	76.0±16.9	80.0±19.4	85.7±13.6	65.1±24.3*	<i>p</i> <0.001

\*Statistically significant lower values than in straight and sigmoid (Tukey-Kramer test, *p*<0.05)

No significant difference in values between kyphosis and lordosis (Tukey-Kramer test, *p*=0.06)

ANOVA, analysis of variance; ER, expansion ratio

Illustrative case: a 63-year-old man



**Figure 2.** Illustrative case of dural expansion. The dural tube continued to expand over time. ER, expansion ratio; Pre-OP, pre-operative

**Surgical outcomes**

Surgical outcomes classified according to the amount of the final expansion of AP diameter of the dural tube are shown in Table 4. There was no significant difference in the value of the recovery rate of JOA scores between the groups. Small dural expansion did not indicate bad surgical outcomes.

**Discussion**

To our knowledge, this is the first report showing that the cervical dural tube continues to expand until 1 year after decompression surgeries. ER within 6 months after the surgery

was approximately 75% and that within 1 year was approximately 90%. These findings suggest that the dural tube could expand until at least 1 year after muscle-preserving selective laminectomy. Decrease of scar tissue might lead to the expansion of the dural tube 6 months after surgery because one report on lumbar decompression surgery described that the scar size around the dura mater decreased between 6 and 24 months after surgery<sup>9)</sup>. Muscle-preserving selective laminectomy with an anatomical approach might facilitate the late expansion of the dural tube. Laminectomy with an anatomical approach decreased the dead space formation because preserved musculature could easily get back to its original position. A small amount of blood loss during the muscle-preserving selective laminectomy also contrib-

**Table 3.** Correlations between AP Diameter of the Dural Tube and Radiological Factors.

Pearson's correlation coefficient <i>r</i> ( <i>p</i> value)	Pre-OP AP diameter	Final AP diameter	Final extent of expansion of AP diameter
Pre-OP C2-7 angle	-0.08 ( <i>p</i> =0.470)	0.234 ( <i>p</i> =0.034)	0.276 ( <i>p</i> =0.012)
Pre-OP ROM	-0.065 ( <i>p</i> =0.561)	-0.054 ( <i>p</i> =0.627)	-0.017 ( <i>p</i> =0.876)
Pre-OP C2-7 SVA	0.173 ( <i>p</i> =0.117)	0.083 ( <i>p</i> =0.453)	-0.014 ( <i>p</i> =0.899)
Final C2-7 angle	-0.037 ( <i>p</i> =0.739)	0.361 ( <i>p</i> =0.001)	0.378 ( <i>p</i> <0.001)
Final ROM	-0.108 ( <i>p</i> =0.339)	-0.101 ( <i>p</i> =0.372)	-0.041 ( <i>p</i> =0.719)
Final C2-7 SVA	0.244 ( <i>p</i> =0.026)	0.142 ( <i>p</i> =0.202)	0.004 ( <i>p</i> =0.972)

AP, anteroposterior; pre-OP, pre-operative

**Table 4.** Clinical Outcomes Classified with the Final Extent of Expansion of the AP Diameter.

Final extent of expansion of AP diameter	0-3.9 mm (N: 24)	4.0-5.9 mm (N: 30)	6.0-mm (N: 29)	
Pre JOA score (full: 17)	12.0±2.6	11.4±2.2	12.6±2.4	NS
Post JOA score	14.3±2.2	13.8±2.0	14.0±2.3	NS
Recovery rate (%) of JOA scores	50.7±26.8	44.3±23.5	34.7±30.7	NS

AP, anteroposterior; JOA, Japanese Orthopaedic Association; NS, not significant

uted to the small dead space formation<sup>6,7</sup>. Post-laminectomy membrane can negatively affect the recovery of neurological damage due to the disease. Considering the late expansion of the dural tube after the muscle-preserving selective laminectomy, the risk of harmful scar tissue formation is minimal after surgery.

ERs at 6 months after surgery were approximately 65% in patients with kyphosis and 80% in the other patients, indicating that the speed of dural expansion was slower in cases with kyphosis. Breig reported that the dural tube and spinal cord were stretched because of neck flexion<sup>10</sup>. The dural tube with kyphosis seemed to be difficult to expand because it was stretched according to neck curvature. The manner of dural expansion in patients with kyphosis possibly suggested that cerebrospinal pressure gradually expanded the dural tube in the same manner that the dural pulsation expanded the dural tube during the surgery because hard dural tube seemed to take time to expand. However, further study is necessary to confirm this idea.

Neck alignment affected the dural expansion because C2-7 angles had mild correlation with the final AP diameter of the dural tube and the final extent of the expansion of AP diameter. These results described that the more the neck curvature was lordotic, the more the dural tube expanded. These results are consistent with previous reports and supported that a greater decompression achieved by lordotic alignment correlated with a better clinical outcome<sup>11,12</sup>. However, the amount of expansion of the dural tube did not have a great influence on neurological recovery. There was no difference in the recovery rate based on JOA scores among the three groups classified by the extent of expansion of the dural tube. Even when the final expansion of AP diameter was <4 mm, the neurological recovery was good, with an average recovery rate of approximately 50%. These results support the findings in a previous report, which described

that extensive decompression was not always necessary for multisegmental cervical spondylotic myelopathy<sup>13,14</sup>. Wide decompression sometimes causes C5 palsy because of excessive spinal cord shift<sup>6,15,16</sup>. In contrast, insufficient decompression will certainly lead to poor neurological recovery. Further studies are necessary to understand the proper extent of decompression required for cervical myelopathy.

### Limitations

As with any study, this investigation had several limitations. First, it was a retrospective study with a small number of patients. To determine the complete time-dependent change of dural expansion, a prospective study that utilizes a large number of subjects is warranted. Second, we did not follow-up patients for a long time. A follow-up of >5 years could possibly reveal an increased expansion of the dural tube. To clarify the limitation of expansion, further studies with longer follow-up periods and more patients are necessary. Third, we only considered AP diameter of the dural tube as a measurement of the dural tube expansion. Measurement of the cross-sectional area of or calculation of the exact volume might be more accurate because it provides three-dimensional information of the dural tube.

### Conclusion

The dural tube continues to expand for approximately 1 year after muscle-preserving selective laminectomy. The dural tube of patients with kyphosis slowly expanded, probably indicating that the hardness of the dura matter affected the dural tube expansion. Small dural expansion does not necessarily indicate bad surgical outcomes.

**Conflicts of Interest:** The authors declare that there are

no relevant conflicts of interest.

**Author Contributions:** Ryoma Aoyama wrote and prepared the manuscript, and all of the authors participated in the study design. All authors have read, reviewed, and approved the article.

## References

1. Hirabayashi K, Watanabe K, Wakano K, et al. Expansive open-door laminoplasty for cervical spinal stenotic myelopathy. *Spine (Phila Pa 1976)*. 1983;8(7):693-9.
2. Wang XY, Dai LY, Xu HZ, et al. Prediction of spinal canal expansion following cervical laminoplasty: a computer-simulated comparison between single and double-door techniques. *Spine (Phila Pa 1976)*. 2006;31(24):2863-70.
3. Hirabayashi S, Yamada H, Motosuneya T, et al. Comparison of enlargement of the spinal canal after cervical laminoplasty: open-door type and double-door type. *Eur Spine J*. 2010;19(10):1690-4.
4. Gu ZF, Zhang AL, Shen Y, et al. The relationship between laminoplasty opening angle and increased sagittal canal diameter and the prediction of spinal canal expansion following double-door cervical laminoplasty. *Eur Spine J*. 2015;24(8):1597-604.
5. LaRocca H, Macnab I. The laminectomy membrane. Studies in its evolution, characteristics, effects and prophylaxis in dogs. *J Bone Joint Surg Br*. 1974;56b(3):545-50. eng.
6. Shiraishi T, Fukuda K, Yato Y, et al. Results of skip laminectomy-minimum 2-year follow-up study compared with open-door laminoplasty. *Spine (Phila Pa 1976)*. 2003;28(24):2667-72. eng.
7. Shiraishi T, Kato M, Yato Y, et al. New techniques for exposure of posterior cervical spine through intermuscular planes and their surgical application. *Spine (Phila Pa 1976)*. 2012;37(5):E286-96. eng.
8. Chiba K, Toyama Y, Watanabe M, et al. Impact of longitudinal distance of the cervical spine on the results of expansive open-door laminoplasty. *Spine (Phila Pa 1976)*. 2000;25(22):2893-8.
9. Ronnberg K, Lind B, Zoega B, et al. Peridural scar and its relation to clinical outcome: a randomised study on surgically treated lumbar disc herniation patients. *Eur Spine J*. 2008;17(12):1714-20.
10. Breig A, el-Nadi AF. Biomechanics of the cervical spinal cord. Relief of contact pressure on and overstretching of the spinal cord. *Acta Radiol Diagn (Stockh)*. 1966;4(6):602-24.
11. Baba H, Uchida K, Maezawa Y, et al. Lordotic alignment and posterior migration of the spinal cord following en bloc open-door laminoplasty for cervical myelopathy: a magnetic resonance imaging study. *J Neurol*. 1996;243(9):626-32.
12. Sodeyama T, Goto S, Mochizuki M, et al. Effect of decompression enlargement laminoplasty for posterior shifting of the spinal cord. *Spine (Phila Pa 1976)*. 1999;24(15):1527-31; discussion 31-2.
13. Hatta Y, Shiraishi T, Hase H, et al. Is posterior spinal cord shifting by extensive posterior decompression clinically significant for multisegmental cervical spondylotic myelopathy? *Spine (Phila Pa 1976)*. 2005;30(21):2414-9.
14. Nori S, Shiraishi T, Aoyama R, et al. Posterior spinal cord shift does not affect surgical outcomes after muscle-preserving selective laminectomy. *J Clin Neurosci*. 2018;50:226-31.
15. Bydon M, Macki M, Aygun N, et al. Development of postoperative C5 palsy is associated with wider posterior decompressions: an analysis of 41 patients. *Spine J*. 2014;14(12):2861-7.
16. Nori S, Aoyama R, Ninomiya K, et al. Cervical laminectomy of limited width prevents postoperative C5 palsy: a multivariate analysis of 263 muscle-preserving posterior decompression cases. *Eur Spine J*. 2017;26(9):2393-403.

Spine Surgery and Related Research is an Open Access journal distributed under the Creative Commons Attribution-NonCommercial-NoDerivatives 4.0 International License. To view the details of this license, please visit (<https://creativecommons.org/licenses/by-nc-nd/4.0/>).