

Single Case

Pan-Esophageal Submucosal Dissection following Transesophageal Echocardiography

Abdulrahman Qatomah^a Jonathan Cools-Lartigue^b Emmanuel Moss^c
Jonathan Wyse^d Corey S. Miller^d

^aDivision of Gastroenterology and Hepatology, McGill University Health Centre, Montreal, QC, Canada; ^bDivision of Thoracic and Upper Gastrointestinal Surgery, Department of Surgery, McGill University Health Center, McGill University, Montreal, QC, Canada; ^cDivision of Cardiac Surgery, Department of Surgery, Jewish General Hospital, McGill University, Montreal, QC, Canada; ^dDivision of Gastroenterology, Department of Medicine, Jewish General Hospital, McGill University, Montreal, QC, Canada

Keywords

Esophagus · Dissection · Upper endoscopy · Gastrointestinal bleeding · Transesophageal echocardiography

Abstract

A 73-year-old female underwent open mitral valve replacement with transesophageal echocardiography (TEE) guidance. She developed upper gastrointestinal bleeding postoperatively and was found on upper endoscopy to have a bleeding site at the gastric cardia with the appearance of focal trauma and a possible puncture site. A submucosal bluish protrusion was seen throughout the esophagus with a mucosal flap at the proximal esophagus. As a unifying diagnosis, it was suspected that the intraoperative TEE probe caused a submucosal dissection with point of entry at the proximal esophagus, running the entire length of the esophagus and exiting at the gastric cardia, giving rise to a clinical upper gastrointestinal bleed. Closure of the esophageal defect was achieved using an endoclip. A CT scan showed focal pneumomediastinum along the proximal esophagus, confirming the hypothesis. We report the first case to our knowledge of iatrogenic pan-esophageal submucosal dissection, which, in this case, presented as a clinical bleed from the exit point trauma to the gastric cardia mucosa caused by a TEE probe. Endoscopic management of the gastric injury as well as the esophageal defect led to resolution of the bleeding and avoidance of mediastinitis, respectively, allowing for an excellent recovery.

© 2022 The Author(s).

Published by S. Karger AG, Basel

Correspondence to:
Corey S. Miller, corey.miller@mcgill.ca

Introduction

Transesophageal echocardiography (TEE) is a common noninvasive procedure used for diagnosis and guidance for a variety of cardiovascular procedures. Esophageal injury following TEE is uncommon. It ranges between minor trauma of the esophageal mucosa to full esophageal perforation reported at 0.03% in a large series [1].

Description of submucosal dissection following TEE is limited to case reports. The management of such complication varies, the main determining factors being the extent of esophageal defect and the patient's clinical stability. Both conservative management and endoscopic intervention with stent placement have been reported [2, 3]. Herein, we report a case of pan-esophageal submucosal dissection from TEE that presented in an unusual way (online suppl. Resource 1; for all online suppl. material, see www.karger.com/doi/10.1159/000525278).

Case Report

A 73-year-old female underwent open mitral valve repair and left atrial appendage closure for severe mitral regurgitation with atrial fibrillation. Intraoperative TEE was performed. Postprocedure, the patient developed moderate amount of blood noted via the nasogastric tube. She was admitted to the intensive care unit and a diagnostic upper endoscopy was performed on day 1 of admission, showing a large blood clot with fresh blood at the fundus. After extensive irrigation and removal of the clot, the bleeding source was identified at the gastric cardia with the appearance of focal trauma and a possible puncture site without evidence of an ulcer or visible vessel (shown in Fig. 1). Hemostasis was successfully achieved using epinephrine injection and clip placement. On withdrawal, a tubular protrusion with bluish discoloration was seen running the length of the esophagus, most pronounced in the mid esophagus (shown in Fig. 2). With normal overlying mucosa, the abnormality was presumed to be arising from the submucosal space. Indeed, at the proximal esophagus, there was a 5-mm mucosal disruption suggestive of trauma with extension into a false tract (shown in Fig. 3). As a unifying diagnosis, it was suspected that the intraoperative TEE probe caused a submucosal dissection with point of entry at the proximal esophagus, running the entire length of the esophagus and exiting at the gastric cardia, giving rise to a clinical upper gastrointestinal bleed. A single clip was placed at the defect, and the patient was started on prophylactic antibiotics (online suppl. Video 1). A CT scan of the thorax showed focal pneumomediastinum along the right proximal esophagus without evidence of mediastinal collection or hematoma, confirming the hypothesis (shown in Fig. 4). Decision was made, in conjunction with thoracic and cardiac surgery, to manage expectantly at this point.

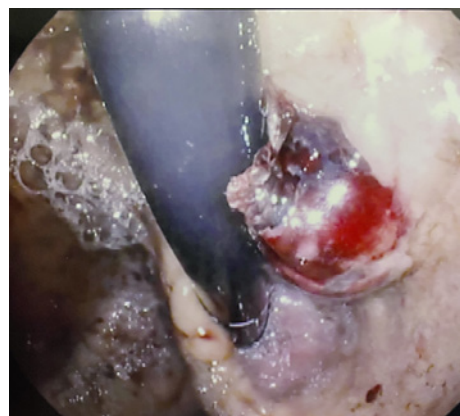

Fig. 1. Gastric cardia defect with appearance of possible puncture site.

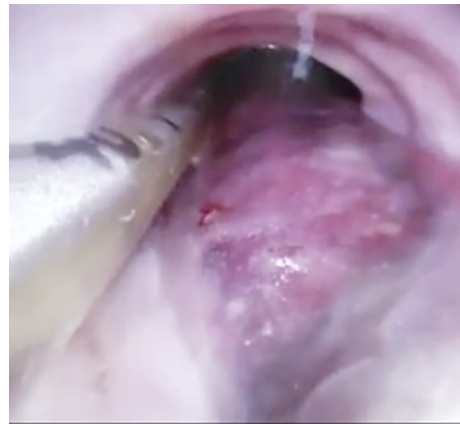

Fig. 2. Suspected submucosal abnormality with bulging and bluish discoloration in the mid esophagus.

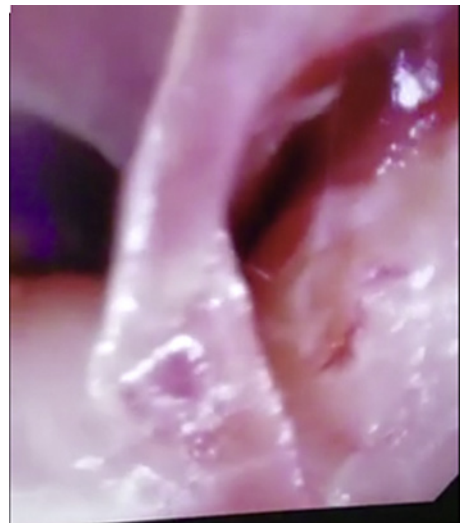

Fig. 3. Mucosal flap at the proximal esophagus with a false tract into the submucosal space (Right) and normal esophageal lumen (Left).

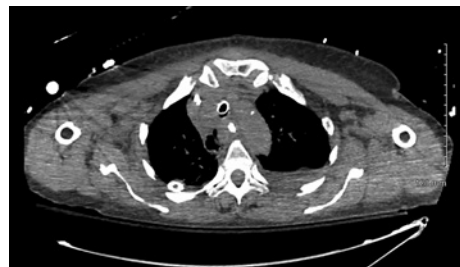


Fig. 4. CT scan of thorax (axial) with pneumomediastinum.

No further overt gastrointestinal bleeding was observed during the intensive care unit course. The patient's hemodynamics was stable throughout. Repeat upper endoscopy on post-operative day 2 confirmed complete closure of the proximal esophageal defect as well as no evidence of bleeding in the stomach. The patient was transferred to the surgery ward where she recovered uneventfully. Prophylactic antibiotics were stopped after 4 days with negative daily blood cultures. Repeat CT with oral contrast demonstrated no contrast extravasation. The patient was assessed by speech pathology and nutrition during her hospital stay, and her diet advanced without issues. She was subsequently discharged home.

Discussion/Conclusion

Esophageal submucosal dissection is an uncommon complication of TEE. There are minimal reported data to guide management of this complication. Our decision to manage the esophageal defect with endoscopic clip closure was based on the corollary of the per-oral endoscopic myotomy procedure, in which the entry site to the submucosal tunnel is closed with clips to approximate the mucosa. Using this technique, only very rare (<0.1%) postprocedure leak and mediastinitis is reported [4]. We believe that early recognition of this complication as well as a multidisciplinary approach involving gastroenterology and thoracic surgery is vital for successful management.

We report the first case to our knowledge of iatrogenic pan-esophageal submucosal dissection, which, in this case, presented as a clinical bleed from the exit point trauma to the gastric cardia mucosa caused by a TEE probe. Endoscopic management of the gastric injury as well as the proximal esophageal defect led to resolution of the bleeding and avoidance of mediastinitis, respectively, allowing for an excellent recovery.

Statement of Ethics

Ethical approval is not required for this study in accordance with local or national guidelines. All procedures followed were in accordance with the ethical standards laid down in the 1964 Declaration of Helsinki and its later amendments. Written informed consent was obtained from the patient for publication of this case report and any accompanying images.

Conflict of Interest Statement

The authors declare that they have no conflict of interest.

Funding Sources

Authors received no funding for this case report.

Author Contributions

Abdulrahman Qatomah conducted material preparation, data collection, and analysis; drafted the first manuscript; and participated in writing the final version. Corey Miller conducted material preparation, data collection, and analysis and participated in writing the final version of the manuscript. Jonathan Cools-Lartigue, Emmanuel Moss, and Jonathan Wyse participated in manuscript writing and reviewing the final version.

Data Availability Statement

All data generated or analyzed during this study are included in this article and its online supplementary supporting files. Further inquiries can be directed to the corresponding author.

References

- 1 Min JK, Spencer KT, Furlong KT, DeCara JM, Sugeng L, Ward RP, et al. Clinical features of complications from transesophageal echocardiography: a single-center case series of 10,000 consecutive examinations. *J Am Soc Echocardiogr*. 2005;18(9):925–9.
- 2 Jovic M, Baulig W, Schneider P, Schmid ER. Esophageal dissection after transesophageal echocardiography in a patient with Barrett's esophagus and long-term systemic steroid therapy. *J Cardiothorac Vasc Anesth*. 2011; 25(1):150–2.
- 3 El-Chami MF, Martin RP, Lerakis S. Esophageal dissection complicating transesophageal echocardiogram – the lesson to be learned: do not force the issue. *J Am Soc Echocardiogr*. 2006;19(5):579e5–7.
- 4 Stavropoulos SN, Desilets DJ, Fuchs KH, Gostout CJ, Haber G, Inoue H, et al. Per-oral endoscopic myotomy white paper summary. *Gastrointest Endosc*. 2014;80(1):1–15.