

Endoscopic Third Ventriculostomy in the Fourth Ventricle Outlet Obstruction Associated with Chiari Malformation Type I and Syringomyelia: Case Report

Abstract

Hydrocephalus by the fourth ventricle outlet obstruction (FVOO) associated with a Chiari malformation type I and syringomyelia is a well-known entity but a rare situation in clinical practice. Although suboccipital craniectomy with the opening of the obstruction membrane appears to be the most physiological approach, by restoring the original pathway of cerebrospinal fluid flow, the endoscopic third ventriculostomy (ETV) represents an important minimally invasive alternative. We report the case of an adult patient with tetra ventricular hydrocephalus by FVOO associated with Chiari malformation and syringomyelia. The ETV alone completely resolved all symptoms, as well as neuroimaging abnormalities on the control magnetic resonance imaging. The ETV is a minimally invasive option for the treatment of hydrocephalus in patients with obstruction at the exit of the fourth ventricle, even in cases associated with Chiari malformation and syringomyelia.

Keywords: Chiari malformation type I, endoscopic third ventriculostomy, foramen of Magendie, fourth ventricle outlet obstruction, hydrocephalus

Introduction

Hydrocephalus by the fourth ventricle outlet obstruction (FVOO) associated with a Chiari malformation type I (CM-I) and syringomyelia is a well-known entity, but a rare situation in clinical practice.^[1] FVOO can be congenital or acquired. In adults, the occlusion is acquired rather than congenital, related to infection, head injury, intraventricular hemorrhage, tumors, or Chiari malformation.^[2] Conventionally, this association is treated by suboccipital craniectomy with the opening of the obstruction membrane.^[3] However, since the advent of neuroendoscopic techniques, endoscopic third ventriculostomy (ETV) has been successfully used to treat hydrocephalus as well as CM-I and syringomyelia.^[1,3,4] We report a case that illustrates the success of neuroendoscopic treatment in this combination.

Case Report

A 23-year-old male student in the English department at the university presented with intense headaches, nausea, dizziness, and visual blur that had been gradually

developing over the past 11 months. No specific pathological history was found during the interview. The patient reported worsening of these symptoms during the past 3 months, with a significant decrease in visual acuity, forcing him to drop out of school. On admission to the neurosurgery department, the neurological examination found a conscious cephalalgic patient, without a neurological sensory-motor deficit. A slight exaggeration of the osteotendinous reflexes in all four limbs was noted. The fundus objectified a bilateral papillary edema stage 2.

Cerebral computed tomography scan revealed hydrocephalus with significant dilatation of all ventricles, including the fourth ventricle, and obliteration of the retrocerebellar space of the cerebrospinal fluid (CSF) [Figure 1a]. Complementary craniocervical magnetic resonance imaging (MRI) confirmed tetraventricular hydrocephalus and showed CM-I and cervical syringomyelia extending to C3 [Figure 1b and c]. The interpeduncular and prepontine cisterns were significantly compressed and

**Sidi Salem-Memou,
Tolba Amal,
Sidi-Mohamed
Salihi,
Outouma Soumare,
Boukhrissi Najat**

*Department of Neurosurgery,
National Hospital Center,
Nouakchott, Mauritania*

Address for correspondence:
Dr. Sidi Salem-Memou,
Department of Neurosurgery,
National Hospital Center,
BP 612, Nouakchott,
Mauritania.
E-mail: fkct@hotmail.com

Access this article online

Website: www.asianjns.org

DOI: 10.4103/ajns.AJNS_67_20

Quick Response Code:



How to cite this article: Salem-Memou S, Amal T, Salihi SM, Soumare O, Najat B. Endoscopic third ventriculostomy in the fourth ventricle outlet obstruction associated with chiari malformation Type I and syringomyelia: Case report. *Asian J Neurosurg* 2021;16:170-3.

Submitted: 26-Feb-2020

Revised: 05-May-2020

Accepted: 04-Aug-2020

Published: 23-Feb-2021

This is an open access journal, and articles are distributed under the terms of the Creative Commons Attribution-NonCommercial-ShareAlike 4.0 License, which allows others to remix, tweak, and build upon the work non-commercially, as long as appropriate credit is given and the new creations are licensed under the identical terms.

For reprints contact: WKHLRPMedknow_reprints@wolterskluwer.com

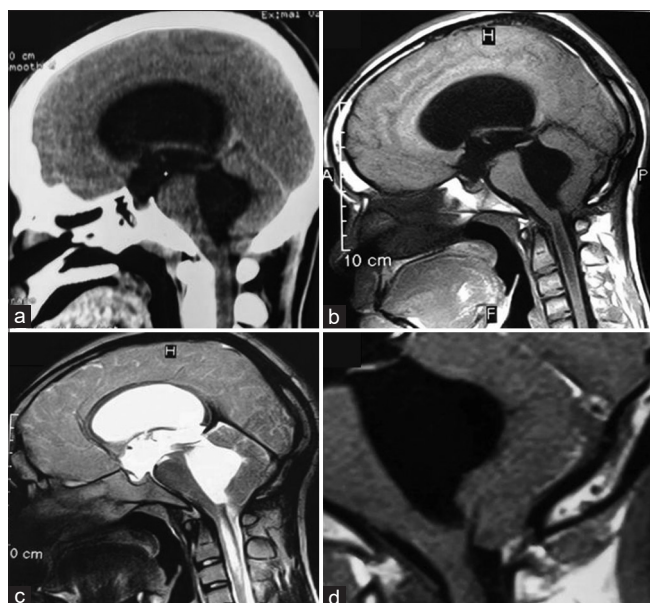

Figure 1: Sagittal (a) Computed tomography scan demonstrating dilation of all ventricles. Sagittal (b and d) T1-weighted, sagittal (c) T2-weighted magnetic resonance imaging showing dilation of all ventricles, Chiari malformation type I, obliteration of the retrocerebellar cerebrospinal fluid space, and syringomyelia

reduced in volume by the very large dilatation of the fourth ventricle [Figure 1].

Faced with this radio-clinical symptomatology, an emergent endoscopic operation was planned. A right transventricular approach was used with an entry point located 1 cm anterior to the coronal suture and 3 cm off the midline. Using a 30° rigid endoscope, a ventriculocisternostomy of the floor of the third ventricle (ETV) was performed. Perforation was performed in the region of the tuber cinereum with a blunt perforator and then dilated with the Fogarty balloon. The endoscope was introduced into the prepontine cistern to check that the procedure was complete. Endoscopic observations of the lateral ventricle, the third ventricle, and the prepontine cistern did not reveal any abnormalities suggestive of previous infection or hemorrhage.

The postoperative course was favorable, with a spectacular improvement in clinical symptomatology and resumption of schooling from the 1st month. The control MRI at 8 months postoperatively showed a virtual disappearance of syringomyelia, the ascension of the cerebellar tonsils, and the resolution of hydrocephalus [Figure 2]. Seen as an outpatient at 11 months postoperatively, the patient was well and had no neurological disturbance.

Discussion

FVOO is a rare but well-established cause of obstructive tetraventricular hydrocephalus.^[5] Although numerous studies on FVOO have been published, the pathogenic mechanism of this condition remains unclear. Tetraventricular hydrocephalus by FVOO is usually

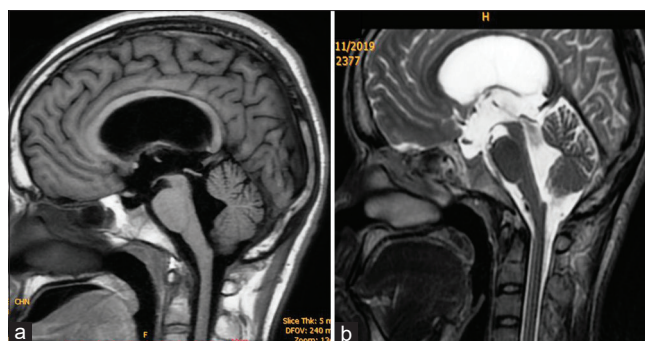


Figure 2: Sagittal (a) T1-weighted and Sagittal (b) T2-weighted postoperative magnetic resonance images showing complete disappearance of Chiari malformation type I and Syringomyelia with a resolution of hydrocephalus

either acquired, caused by an inflammatory process, or congenital, caused by abnormalities of the posterior fossa, such as Dandy–Walker Syndrome, Chiari malformation, and tuberous sclerosis.^[2,6,7] In adults, the occlusion is acquired rather than congenital, often related to infection, head trauma, intraventricular hemorrhage, tumors, or Chiari malformation.^[2]

FVOO is a rare syndrome that is associated with hydrocephalus and syringomyelia, which are frequently found in patients with CM-I; such an obstruction is caused by the chronic tonsillar herniation.^[8] The mechanisms precipitating the onset of hydrocephalus associated with CM-I in adults are unknown. Some authors have proposed that meningoencephalitis, infraclinical inflammation, or even connective tissue proliferation without inflammatory changes may cause obstruction of the exit of the fourth ventricle.^[1]

In a combination of CM-I and hydrocephalus by FVOO, the most difficult question is whether CM-I is the cause or consequence of obstructive hydrocephalus. We know that hydrocephalus can cause pressure on the cerebellar tonsils causing them to descend into the foramen magnum. However, overt hydrocephalus is reported in only 7%–10% of patients with symptomatic CM-I.^[4] It has been argued that CM-I is primarily a developmental abnormality of the posterior fossa with subsequent arachnoid adhesions. Therefore, any associated hydrocephalus may be due to an obstructive phenomenon at the exit of the fourth ventricle CSF pathway.^[9] Some authors believe that in cases of pronounced dilatation of the fourth ventricle with an increase in the size of the lateral cavities and no history of inflammation or hemorrhage, the diagnosis of Luschka's and Magendie's foramina atresia is most likely.^[2,6,10,11]

Our case had no known medical history and the endoscopic appearance of the lateral ventricles and the third ventricle showed no evidence of previous meningitis or hemorrhage. In addition, the lack of intraoperative endoscopic or macroscopic exploration of the fourth ventricle exits in our case does not permit to confirm that the hydrocephalus was primary to the FVOO.

The onset of clinical symptoms in adulthood, as in our case, would be explained by a late noncompensation of a constitutional “partial” imperforation of the Magendie foramen which was semi-permeable, obstructing the exit pathways of the CSF. However, the reason for this evolution remains uncertain.^[7] Longatti *et al.* reported ten cases of primary obstruction of the fourth ventricle outflow. These authors endoscopically revealed a type of primitive stenosis such as restriction of the Magendie’s contour with a thick and opaque membrane, transparent spiderweb-like membrane, and dense membrane with fissure acting as a valve.^[7]

Orakdogan *et al.* reported a series of four patients who all had CM-I, tetraventricular dilatation, and syringomyelia. All four patients had a membrane obstructing the Magendie foramen visible intraoperatively after posterior fossa cerebral decompression and exploration.^[12]

The treatment of these malformations is still controversial. Different approaches have been described for the treatment of hydrocephalus due to FVOO, such as ventriculoperitoneal shunt, ETV, fourth endoscopic ventriculostomy, suboccipital craniectomy with a simple opening of the obstructing membrane or placement of a catheter to maintain its permeability to the cisterna magna or the subarachnoid space of the anterolateral superior cervical spinal cord.^[5,6]

It is now well established that ETV is the standard treatment for obstructive hydrocephalus. Although recent studies have suggested that ETV is a less invasive treatment and an effective strategy for treating hydrocephalus with FVOO.^[7,13-16] However, in cases associated with CM-I and syringomyelia, some prefer other options that focus on decompression of the foramen magnum. Indeed, posterior fossa craniotomy and membrane excision are still advocated by some.^[12,17]

Orakdogan *et al.* suggest that suboccipital craniectomy with the opening of the obstructing membrane and placement of a catheter is the most physiological approach, restoring the original pathway of CSF circulation.^[5,12] However, this technique is far from being minimally invasive. In addition, the ventriculo-subarachnoid shunt is a foreign material that can be responsible for complications such as infection and catheter migration.^[10]

The principle of ETV is essentially to allow the passage of CSF from the ventricular system to the basal cisterns without the need for the CSF to pass through the fourth ventricle. Therefore, ETV should be beneficial in the case of hydrocephalus due to obstruction at the CSF outlet and the foramen magnum region.^[3] The good issue of our case following ETV suggested that primary hydrocephalus was the etiology of the CMI. It has been successfully used by several authors and has, as in our case, solved all pathologies such as CM-I, hydrocephalus, and

syringomyelia.^[1,3,4,7,13,14] In fact, ETV has many advantages. It is a safe physiological procedure and a minimally invasive technique with a low risk of infection and a low recurrence rate.^[13] However, some distortions can make it difficult and risky to perform. Among these distortions is an anteriorly dislodged brain stem making the suprasellar and prepontine cisterns very narrow and a basilar trunk very close to the floor of the third ventricle. However in our opinion, inexperienced hands, even under these conditions, ETV is most often achievable.

Endoscopic foraminoplasty by direct fenestration of the membranous obstruction at the exit of the fourth ventricle is another reported treatment option.^[5,7,18]

Although there have been reports of good results with this more demanding technique, it should be considered only when ETV is difficult or ineffective and should be performed by experienced neuro-endoscopists.^[16]

Conclusion

In this case, a pathological association of hydrocephalus by FVOO, CM-I, and syringomyelia is described in an adult without a pathological history. The effectiveness obtained in our case suggests that ETV may be sufficient to treat hydrocephalus as well as CM-I and syringomyelia and could be considered as a first-line treatment in the management of this entity, pending completion of further randomized control trials.

Declaration of patient consent

The authors certify that they have obtained all appropriate patient consent forms. In the form, the legal guardian has given his consent for images and other clinical information to be reported in the journal. The guardian understands that names and initials will not be published and due efforts will be made to conceal identity, but anonymity cannot be guaranteed.

Financial support and sponsorship

Nil.

Conflicts of interest

There are no conflicts of interest.

References

1. Suehiro T, Inamura T, Natori Y, Sasaki M, Fukui M. Successful neuroendoscopic third ventriculostomy for hydrocephalus and syringomyelia associated with fourth ventricle outlet obstruction. Case report. *J Neurosurg* 2000;93:326-9.
2. Rougier A, Ménégon P. MRI evidence of membranous occlusion of the foramen of Magendie. *Acta Neurochir (Wien)* 2009;151:693-4.
3. Mohanty A, Suman R, Shankar SR, Satish S, Praharaj SS. Endoscopic third ventriculostomy in the management of chiari I malformation and syringomyelia associated with hydrocephalus. *Clin Neurol Neurosurg* 2005;108:87-92.
4. Hayhurst C, Osman-Farah J, Das K, Mallucci C. Initial

- management of hydrocephalus associated with chiari malformation type I-syringomyelia complex via endoscopic third ventriculostomy: An outcome analysis. *J Neurosurg* 2008;108:1211-4.
5. Longatti P, Fiorindi A, Feletti A, Baratto V. Endoscopic opening of the foramen of magendie using transaqueductal navigation for membrane obstruction of the fourth ventricle outlets. Technical note. *J Neurosurg* 2006;105:924-7.
 6. Giannetti AV, Malheiros JA, da Silva MC. Fourth ventriculostomy: An alternative treatment for hydrocephalus due to atresia of the Magendie and Luschka foramina. *J Neurosurg Pediatr* 2011;7:152-6.
 7. Longatti P, Fiorindi A, Martinuzzi A, Feletti A. Primary obstruction of the fourth ventricle outlets: Neuroendoscopic approach and anatomic description. *Neurosurgery* 2009;65:1078-85.
 8. Milhorat TH, Chou MW, Trinidad EM, Kula RW, Mandell M, Wolpert C, *et al.* Chiari I malformation redefined: Clinical and radiographic findings for 364 symptomatic patients. *Neurosurgery* 1999;44:1005-17.
 9. Banerji NK, Millar JH. Chiari malformation presenting in adult life. Its relationship to syringomyelia. *Brain* 1974;97:157-68.
 10. Karachi C, Le Guérinel C, Brugières P, Melon E, Decq P. Hydrocephalus due to idiopathic stenosis of the foramina of Magendie and Luschka. Report of three cases. *J Neurosurg* 2003;98:897-902.
 11. Carpentier A, Brunelle F, Philippon J, Clemenceau S. Obstruction of Magendie's and Luschka's foramina. Cine-MRI, aetiology and pathogenesis. *Acta Neurochir (Wien)* 2001;143:517-21.
 12. Orakdogan M, Emon ST, Erdogan B, Somay H. Fourth ventriculostomy in occlusion of the foramen of magendie associated with chiari malformation and syringomyelia. *NMC Case Rep J* 2015;2:72-5.
 13. Mohanty A, Anandh B, Kolluri VR, Praharaj SS. Neuroendoscopic third ventriculostomy in the management of fourth ventricular outlet obstruction. *Minim Invasive Neurosurg* 1999;42:18-21.
 14. Oertel JM, Mondorf Y, Schroeder HW, Gaab MR. Endoscopic diagnosis and treatment of far distal obstructive hydrocephalus. *Acta Neurochir (Wien)* 2010;152:229-40.
 15. Ferrer E, de Notaris M. Third ventriculostomy and fourth ventricle outlets obstruction. *World Neurosurg* 2013;79:S20.e9-13.
 16. Ishi Y, Asaoka K, Kobayashi H, Motegi H, Sugiyama T, Yokoyama Y, *et al.* Idiopathic fourth ventricle outlet obstruction successfully treated by endoscopic third ventriculostomy: A case report. *Springerplus* 2015;4:565.
 17. Huang YC, Chang CN, Chuang HL, Scott RM. Membranous obstruction of the fourth ventricle outlet. A case report. *Pediatr Neurosurg* 2001;35:43-7.
 18. Torres-Corzo J, Sánchez-Rodríguez J, Cervantes D, Rodríguez-Della Vecchia R, Muruato-Araiza F, Hwang SW, *et al.* Endoscopic transventricular transaqueductal Magendie and Luschka foraminoplasty for hydrocephalus. *Neurosurgery* 2014;74:426-35.