

# Multimodality treatment of head-and-neck soft-tissue sarcomas and short-term outcomes: Analysis from sarcoma medical oncology clinic

Ilavarasi Vanidassane, Aparna Sharma, Aditi Aggarwal<sup>1</sup>, Sudhakar Gunasekar<sup>2</sup>, Adarsh Barwad<sup>3</sup>, Ekta Dhamija<sup>4</sup>, Rambha Pandey<sup>5</sup>, Suryanarayana Deo<sup>2</sup>, Rakesh Garg<sup>6</sup>, Sameer Rastogi

## Abstract

**Background:** Head-and-neck soft-tissue sarcomas (HNSTS) are extremely rare and lack definite guidelines. **Methods:** We retrospectively analyzed consecutive adult patients with HNSTS who presented to our sarcoma medical oncology clinic from January 2016 to October 2017. **Results:** There were a total of 30 patients. Unresectable localized disease was seen in 13 (43%) patients, metastatic disease 10 (34%) patients, while resectable disease in 7 (23%) patients only. Among unresectable localized disease, 3 (25%) patients could be converted to resectable disease after neoadjuvant therapy. Median follow period was 11 months. Progression-free survival was 19 months in patients with resectable disease and 6 months in patients with the unresectable/metastatic disease. Median OS was not reached. **Conclusion:** Unresectable HNSTS has a poor outcome. Neoadjuvant therapy can be tried in selected cases for achieving respectability or for vital organ preservation until robust data are available. A multidisciplinary approach for local control is crucial in managing unresectable HNSTS.

**Key words:** Head-and-neck sarcoma, multimodality treatment, neoadjuvant therapy, soft-tissue sarcoma, unresectable

## Introduction

Soft-tissue sarcomas (STSs) constitute <1% of all malignancies.<sup>[1]</sup> The most common site of STS is extremity (45%), visceral (21%), retroperitoneum (17%), trunk (10%), head and neck (5%), and others (2%).<sup>[2]</sup> Head-and-neck STSs (HNSTSs) constitute 1% of all head-and-neck malignancies.<sup>[3]</sup> Surgery is the primary modality in the management of HNSTS. The data for adjuvant radiation therapy (RT) are extrapolated from extremity sarcomas which favor RT in high-grade STS or in tumor with close or positive margins.<sup>[4]</sup> Difficulty in attaining negative margins owing to complex functional anatomy in head-and-neck region attributes to increased local recurrence and poor survival. There are very few reports regarding the management of HNSTS with surgery and adjuvant therapy (predominantly radiotherapy).<sup>[5-9]</sup> Mendenhall *et al.* conducted a review of literature and reported 5-year OS of 60%–70% in HNSTS and concluded that adjuvant radiotherapy improved local control in high-grade tumors and/or positive margins.<sup>[6]</sup> Liuzzi *et al.* in their study of 62 patients showed T2 lesions, presence of lymph node metastasis, advanced stage and invasion to adjacent bone, nerves were associated with decreased survival.<sup>[9]</sup> These series predominantly had patients with resectable disease.

The role of chemotherapy in HNSTS is not well established. In this paper, we highlight the role of medical oncology in the management of this rare tumor.

## Methods

This is a retrospective study of prospectively maintained data base of all patients with above 14 years who presented to sarcoma medical oncology clinic from January 2016 to October 2017. All cases were reviewed in multidisciplinary sarcoma clinic comprising surgical oncologist, radiation oncologist, medical oncologist, and palliative medicine team.

STSs above clavicle were categorized as HNSTS. Data including clinical characteristics, histopathology, treatment

modality, and outcomes were documented through hospital records.

Patients with a resectable tumor underwent surgical excision in an attempt to attain R0 resection. Adjuvant therapy was provided for lesions with any high-risk factors of disease relapse which includes tumor size >5 cm, high histological grade, and deep location. Unresectable locally advanced disease was planned for neoadjuvant therapy, in an attempt to make it surgically resectable.

## Statistical methods

Categorical variables and ordinal variables were displayed in tabular form. All numerical variables were tabulated as whole number. Data were tabulated in Microsoft Excel. Median and range were used to describe quantitative variables.  $P < 0.05$  was considered statistically significant. Kaplan–Meier curve was used for estimating survival. SPSS (IBM Corp. Released 2015. IBM SPSS Statistics for Windows, Version 23.0. Armonk, NY) was used for statistical calculation.

## Results

### Patient and tumor characteristics

A total of 30 patients with HNSTS were registered in our clinic during the study period. The median age of patients was 37 (14–73) years. The patient characteristics are tabulated in Table 1. The majority of the patients were men ( $n = 21$ , 70%). The most common sites of HNSTS were neck, face, and scalp. The most common histology in our series were synovial sarcoma, and pleomorphic undifferentiated sarcoma (PUS) followed by malignant peripheral nerve sheath tumor (MPNST), rhabdomyosarcoma (RMS), and angiosarcoma. At the time of presentation, only 7 (24%) patients had resectable localized disease, 13 (43%) patients had locally unresectable disease, and 10 (33%) had metastatic disease. In patients with metastatic disease, the most common site of metastasis was the lung

This is an open access journal, and articles are distributed under the terms of the Creative Commons Attribution-NonCommercial-ShareAlike 4.0 License, which allows others to remix, tweak, and build upon the work non-commercially, as long as appropriate credit is given and the new creations are licensed under the identical terms.

**For reprints contact:** reprints@medknow.com

**How to cite this article:** Vanidassane I, Sharma A, Aggarwal A, Gunasekar S, Barwad A, Dhamija E, *et al.* Multimodality treatment of head-and-neck soft-tissue sarcomas and short-term outcomes: Analysis from sarcoma medical oncology clinic. *South Asian J Cancer* 2019;8:69-71.

### Access this article online

#### Quick Response Code:



Website: www.sajc.org

DOI: 10.4103/sajc.sajc\_229\_18

Departments of Medical Oncology, <sup>2</sup>Surgical Oncology, <sup>4</sup>Radiodiagnosis, <sup>5</sup>Radiation Oncology and <sup>6</sup>Oncoanaesthesia, IRCH, AIIMS, <sup>3</sup>Department of Pathology, AIIMS, <sup>1</sup>Department of Radiation Oncology, Lok Nayak Hospital, New Delhi, India  
**Correspondence to:** Dr. Sameer Rastogi,  
 E-mail: samdoc\_mamc@yahoo.com

followed by bones. Lymph node involvement was seen in three cases each from angiosarcoma, epithelioid sarcoma, and synovial sarcoma.

### Treatment modalities

All seven patients with resectable disease underwent wide surgical excision. The postoperative histopathological examination in all patients revealed close margin. Five received postoperative adjuvant radiotherapy (intensity-modulated radiotherapy) and two patients received adjuvant sequential chemotherapy (single-agent doxorubicin 5 or 6 cycles) and intensity-modulated radiotherapy. Total radiation dose was approximately 6000 cGy in 30 fractions.

Metastatic patients were started on palliative chemotherapy. Totally 6 patients received anthracycline-based chemotherapy (VCD, ifosfamide epirubicin, and single-agent doxorubicin), 2 patients with angiosarcoma received pazopanib, 2 patients with dermatofibrosarcoma protuberans (DFSP) received imatinib. Those patients who progressed were given second line or advised best supportive care if performance status was poor.

Of 13 patients with unresectable localized disease, neoadjuvant therapy was offered in 12 patients, as one patient with MPNST refused further treatment and shifted to alternative medicine. Among patients who received neoadjuvant treatment, 2 patients received chemoradiation, 8 patients received chemotherapy

only, and 2 patients received imatinib. Best response was partial response in 5 (41.6%) patients (2 patients of RMS, one each of synovial sarcoma, PUS, and DFSP), stable disease in 5 (41.6%) patients, and progressive disease in 2 (16.6%) patients. Out of the 5 patients who achieved partial response, 3 patients underwent surgical resection and received adjuvant radiotherapy; Figure 1 explains the overview of treatment of cohort.

### Treatment outcomes

Median follow-up period was 11 months. In the resectable group, 2 of 7 (28%) patients had local recurrence. In unresectable locally advanced group and metastatic group, 6 of 13 (46%) patients and 7 of 10 (70%) patients had disease progression. Of all 8 patients with recurrences, local recurrence alone was seen in 5 (63%) patients and distant metastasis along with local recurrence was seen in 3 (38%) patients. Progression-free survival (PFS) of patients with resectable and unresectable/metastatic disease was 19 months and 6 months, respectively, [Figure 2]. Median OS was not reached at the time of publication.

### Discussion

Out of total 400 sarcoma patients registered during the study period, 30 (7%) patients had HNSTS. The median age of our patients was 37 years, which is less than the reported range of 55–59 years;<sup>[2]</sup> this could partly be attributed to a minimum age cutoff of 14 years used in our study, increased number of synovial sarcoma which is more common in teens and young adults or younger population structure of our country.

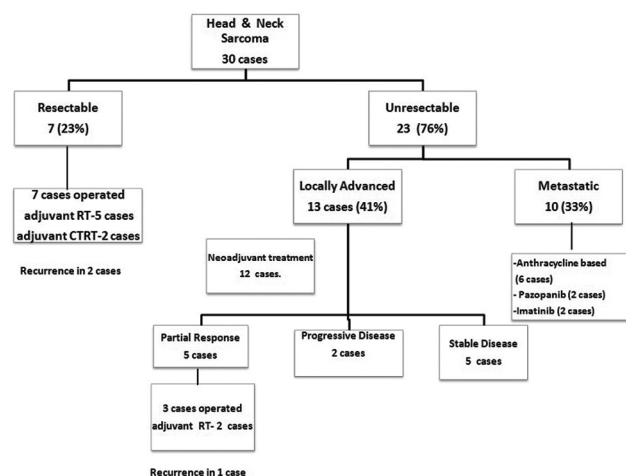
HNSTS are commonly seen in the scalp, face, neck, and paranasal sinuses.<sup>[10]</sup> The most common site of tumor in our study was neck, followed by face in contrast to other series, where face and scalp were most common.<sup>[5,7]</sup> The distribution of histology is variable in the available literature. In one of the largest study by Mattavelli *et al.* where 167 patients of HNSTS over a 20 years period with a median follow-up of 5.5 years were studied, the most common histologic types are DFSP, leiomyosarcoma, and MPNST.<sup>[5]</sup> In our series, the most common histology is synovial sarcoma similar to Tejani *et al.*<sup>[7]</sup> Lymph node involvement is 10% in our series similar to that in reported literature.<sup>[11]</sup>

Mattavelli *et al.* reported a median survival of 14 months after local recurrence and 7 months after distance metastases.<sup>[5]</sup> Our

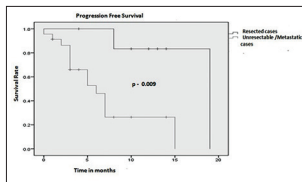
**Table 1: Demographic and clinical characteristics of head-and-neck soft-tissue sarcoma cases**

Variables	Number of cases (%)
Median age, range (years)	37 (14-73)
Sex	
Male	21
Stage	
Localized	
Resectable	7 (24)
Unresectable	13 (43)
Metastatic	10 (33)
Subsite	
Neck	11 (36)
Face	8 (26)
Scalp	5 (16)
Tongue	2 (6)
Orbit	2 (6)
Others*	2 (6)
Histology	
Synovial sarcoma	8 (26)
PUS	5 (16)
MPNST	3 (10)
RMS	3 (10)
Angiosarcoma	3 (10)
DFSP	2 (6)
Leiomyosarcoma	2 (6)
Others <sup>†</sup>	4 (13)
Metastatic site	
Lymph node	3
Lungs	5
Bones	4
Others (brain, breast)	2

\*Supraglottis, parotid, <sup>†</sup>Epithelioid sarcoma, alveolar soft part sarcoma, mesenchymal chondrosarcoma (2 cases). PUS=Pleomorphic undifferentiated sarcoma, MPNST=Malignant peripheral nerve sheath tumor, RMS=Rhabdomyosarcoma, DFSP=Dermatofibrosarcoma protuberans



**Figure 1: Flowchart depicting the overview of treatment of cohort**



**Figure 2: Figure showing the difference in progression free survival in resected and unresected/metastatic patients**

study showed a statistically significant difference in PFS of 13 months between resectable and unresectable HNSTS. In our study, local relapses are more than distant metastases unlike the existing literature for extremity sarcomas. Increased local failure rates in HNSTS highlight the fact that local control is crucial in the management of these tumors. Unlike extremity sarcomas where amputation is among the modalities of local control, surgical resection with negative margins is the main stay of treatment in HNSTS. Routine neck lymph node dissection is not recommended in these patients as lymph node involvement is uncommon. Vital structures and anatomical complexity in the region could pose a big challenge in achieving negative margin and thus affect the disease outcome. Barker *et al.* reported that with addition of adjuvant RT in cases with positive margins there is an increase in local control rate of tumor from 25% to 54%.<sup>[12]</sup> Till date, all available case series in HNSTS have predominantly resectable STS with <5% study population receiving neoadjuvant therapy.<sup>[5,7]</sup> To the best of our knowledge, our study is the only one highlighting the role of chemotherapy in the management of unresectable HNSTS.

There is no randomized study regarding neoadjuvant therapy in HNSTS owing to its heterogeneity and rarity. In our study, 41% of unresectable cases had partial response and 23% of them were operated following neoadjuvant therapy. One can suggest with these findings that the role of neoadjuvant therapy still holds promise in HNSTS. Neoadjuvant chemotherapy can be considered in inoperable locally advanced tumor to achieve negative margins or in tumor resection which requires disfiguring surgery. The use of neoadjuvant therapy should be decided on a case to case basis. Adjuvant/neoadjuvant chemotherapy should be considered in patients with high-risk HNSTS, after clearly explaining the expected risks and benefits until robust data are available. Retrospective nature, small heterogeneous sample, and short follow-up are the limitations of the study.

## Conclusion

Discussion with a surgeon, medical oncologist, radiation oncologist, speech and swallowing therapist, and palliative care specialist should be integral part of the management of patients with HNSTS. The results of the multimodality approach cannot be overemphasized and early referral to tertiary cancer centers for better management of these tumors is very important. Future prospective studies in HNSTS are required to have robust evidence in management of these patients.

## Financial support and sponsorship

Nil.

## Conflicts of interest

There are no conflicts of interest.

## References

1. Siegel RL, Miller KD, Jemal A. Cancer statistics, 2017. *CA Cancer J Clin* 2017;67:7-30.
2. Singer S, Tap WD, Crago AM, O'Sullivan B. Soft tissue sarcoma. In: DeVita VT Jr., Lawrence TS, Rosenberg SA, editors. *DeVita, Hellman, and Rosenberg's Cancer: Principles & Practice of Oncology*. USA: Wolters Kluwer; 2015. p. 1254.
3. SEER. Soft Tissue Sarcomas, Cancer Statistic Review; 1975–2010. Available from: <http://www.seer.cancer.gov/csr/19752010/resultsmerged/sect34softtissuesarcomas.pdf>. [Last cited on 2018 Jun 08].
4. O'Sullivan B, Griffin AM, Dickie CI, Sharpe MB, Chung PW, Catton CN, *et al.* Phase 2 study of preoperative image-guided intensity-modulated radiation therapy to reduce wound and combined modality morbidities in lower extremity soft tissue sarcoma. *Cancer* 2013;119:1878-84.
5. Mattavelli D, Miceli R, Radaelli S, Mattavelli F, Cantù G, Barisella M, *et al.* Head and neck soft tissue sarcomas: Prognostic factors and outcome in a series of patients treated at a single institution. *Ann Oncol* 2013;24:2181-9.
6. Mendenhall WM, Mendenhall CM, Werning JW, Riggs CE, Mendenhall NP. Adult head and neck soft tissue sarcomas. *Head Neck* 2005;27:916-22.
7. Tejani MA, Galloway TJ, Lango M, Ridge JA, von Mehren M. Head and neck sarcomas: A comprehensive cancer center experience. *Cancers (Basel)* 2013;5:890-900.
8. Sidappa KT, Krishnamurthy A. Adult soft tissue sarcomas of the head and neck. *Indian J Cancer* 2011;48:284-8.
9. Liuzzi JF, Da Cunha M, Salas D, Siso S, Garriga E. Soft-tissue sarcomas in the head and neck: 25 years of experience. *Ecancermedicalscience* 2017;11:740.
10. Galy-Bernadoy C, Garrel R. Head and neck soft-tissue sarcoma in adults. *Eur Ann Otorhinolaryngol Head Neck Dis* 2016;133:37-42.
11. Barker JL Jr., Paulino AC, Feeney S, McCulloch T, Hoffman H. Locoregional treatment for adult soft tissue sarcomas of the head and neck: An institutional review. *Cancer J* 2003;9:49-57.
12. de Bree R, van der Valk P, Kuik DJ, van Diest PJ, Doornaert P, Buter J, *et al.* Prognostic factors in adult soft tissue sarcomas of the head and neck: A single-centre experience. *Oral Oncol* 2006;42:703-9.