

Samter–Beer triad presenting as Kounis type I variant of syndrome



Imen Hamdi ^{a,*}, Chadia Chourabi ^a, Taha Yassine Jabloun ^a, Mehdi Ghommidh ^a, Dhaker Lahidheb ^a, Wafa Fehri ^a, Habib Haouala ^a

^a Cardiology Department, Military Hospital of Tunis, Tunis

^a Tunisia

Introduction

Kounis syndrome (KS) was first described in 1991 by Kounis and Zavras. It has been established as an acute coronary syndrome triggered by allergic or hypersensitivity reactions resulting in mast cell and platelet activation. Various causes have been found to trigger KS including drugs, various conditions (bronchial asthma, urticarial, food allergy), environmental exposure and stent implantation. Clinical manifestations of Kounis syndrome include the spectrum of acute coronary syndromes, including coronary spasm, acute myocardial infarction (MI), or stent thrombosis. KS is an infrequently diagnosis among patients with MI. Herein, we report a case of Kounis syndrome in the setting of Samter-Beer triad of asthma, nasal polyps, and aspirin allergy.

Case report

We report a case of a 54-year-old woman with past history of Samter Beer triad (asthma, nasal polyps, and Aspirin allergy), diagnosed in 2002 treated with beta 2 agonists and inhaled corticosteroids. She did not have history of conventional risk factors for coronary artery disease. She was admitted in Pneumology department during two weeks for a severe worsening of her asthma. She

had developed allergic skin reaction to Penicillin. Twenty days after, she was admitted to our institute's emergency room for severe chest pain during more than 30 minutes. She had previously experienced less severe episodes of chest pain, occurred at rest with no identifiable trigger, neglected by her. On arrival, her heart rate was 90 beats/minute, and her systolic blood pressure was 130/70 mm Hg. There were no heart murmurs, gallops, or rubs. She did not have pruritus or rash. 12 lead ECG documented extensive anterior ST elevation myocardial infarction **Fig. 1**. Blood investigations revealed significant increase in her troponin level (2264 µg/l, reference value <19 µg/l) and raised eosinophil count (1757/mm³). Echocardiogram revealed moderate reduction in left ventricular ejection fraction (45%) with regional wall motion abnormalities in anterior wall and apex (**Fig. 3**). She was medicated initially with Clopidogrel and heparin and she immediately underwent coronarography which did not show any sign of coronary atherosclerosis (**Fig. 2**). After the procedure the chest pain resolved completely and the ECG showed isoelectric ST segment. Cardiac Magnetic Resonance was consistent with ischemic lesion in anterior descending artery territory (**Fig. 4**). Coronary artery vasospasm due to hyper-eosinophilia was strongly suspected. Alternative causes of coronary

Disclosure: Authors have nothing to disclose with regard to commercial support.

Received 1 February 2018; revised 4 March 2018; accepted 14 March 2018.
Available online 24 March 2018

* Corresponding author at: Cardiology Department, Military Hospital of Tunis, Mont Fleury, 1008 Tunis, Tunisia.
E-mail address: imen_hamdi83@hotmail.com (I. Hamdi).



P.O. Box 2925 Riyadh – 11461KSA
Tel: +966 1 2520088 ext 40151
Fax: +966 1 2520718
Email: sha@sha.org.sa
URL: www.sha.org.sa



1016-7315 © 2018 The Authors. Production and hosting by Elsevier B.V. on behalf of King Saud University. This is an open access article under the CC BY-NC-ND license (<http://creativecommons.org/licenses/by-nc-nd/4.0/>).

Peer review under responsibility of King Saud University.
URL: www.ksu.edu.sa
<https://doi.org/10.1016/j.jscha.2018.03.002>



Production and hosting by Elsevier

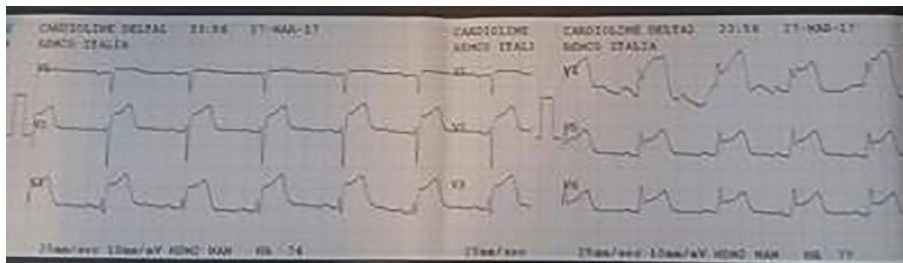


Figure 1.

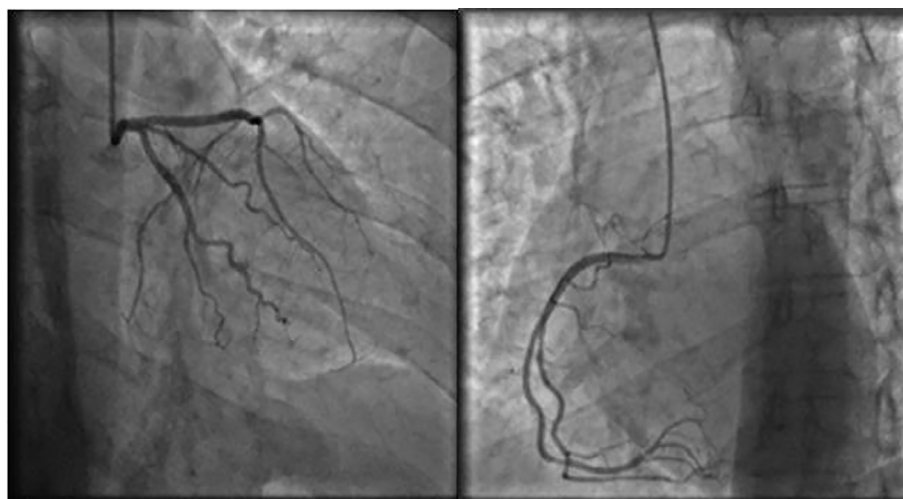


Figure 2.

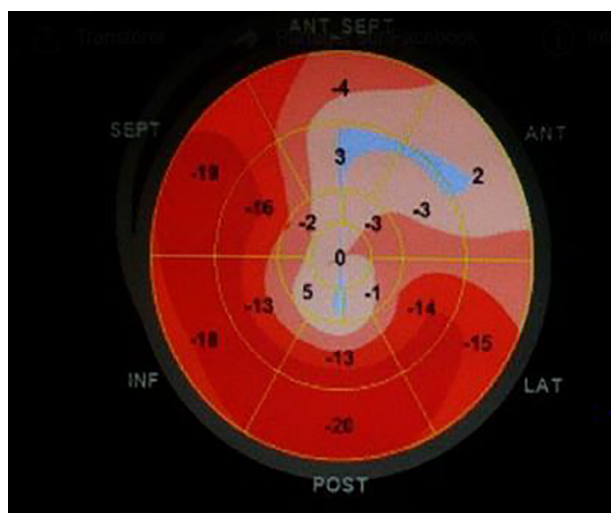


Figure 3.

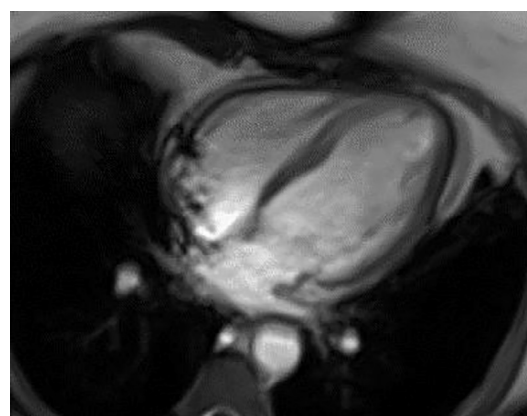


Figure 4.

vasospasm such as smoking, potassium or magnesium electrolyte disturbances, cocaine use were excluded. The patient was treated with Molsidomine (6 mg/day), Diltiazem (180 mg/day) and intravenous Hydrocortisone Hemisuccinate. (40 mg, 3 times/day, for 2 days).

During the monitoring, another episode of chest pain with ST-elevation on the ECG was documented, treated with intravenous Isosorbide Dinitrate with immediate pain relief.

She was discharged one week later with Molsidomine (6 mg/day) and Diltiazem (180 mg/day) and Trinitrine patch. For her asthma, she were

kept under inhaled corticosteroids, H1 antagonists and Montelukast (leukotriene receptor antagonist) and advised against the use of all NSAID and Aspirin. At 10-month follow-up, the patient had had 1no further angina pectoris.

Discussion

In 1991, Kounis and Zavras described “the coincidental occurrence of chest pain and allergic reactions accompanied by clinical and laboratory findings of classical angina pectoris caused by inflammatory mediators released during the allergic insult” [1]. Kounis-Zavras syndrome is the term used for allergic angina pectoris or allergic myocardial infarction and nowadays this syndrome also is described for involvement of other arteries such as mesenteric and cerebral arteries [2]. The ischemia in allergic reaction is secondary to the release of inflammatory mediators, including histamine, tryptase, chymase, platelet-activating factor, cytokines, and prostaglandins, and leukotriene synthesis, which leads to coronary vasospasm [3]. Three variants of KS have been described [4]. The type I variant (coronary spasm) includes patients with normal or nearly normal coronary arteries without risk factors for coronary artery disease. The type II variant (coronary thrombosis) includes patients with preexisting atheromatous coronary artery disease. The type III variant includes patients with stent thrombosis.

Many etiologies have been reported [5], including drugs (antibiotics, analgesics, contrast media...), various conditions (angioedema, bronchial asthma, rhinitis, nasal polyp, urticaria, food allergy...), environmental exposure (stings of ants, bees, latex contact, viper venom poisoning...) and stent implantation (nickel, chromium...).

Our patient was diagnosed as having Samter-Beer triad because she had asthma, eosinophilia, nasal polyps and Aspirin allergy. The link between asthma, nasal polyps, and aspirin sensitivity was first described in 1922 by French clinician-scientist M. Fernando Widal [6]. His single case report included challenges with aspirin and antipyrine (a COX-1 inhibitor) with observed respiratory reactions. The article was published in a French journal and was not translated into English until 1993. In 1968, Samter and Beers, not knowing about the Widal publication, believed that they were the first to discover the link between asthma, nasal polyps, and aspirin sensitivity and named it ‘Samter-Beer triad’ [7]. The sharp rise in cysteinyl leukotrienes that occurs with non-steroidal anti-

inflammatory drug ingestion in Samter’s triad has been shown to cause myocardial ischemia in patients with anatomically normal coronary arteries [8].

Reports of coronary spasm cases induced by Samter’s triad are few. When patients are suspected as acute coronary syndrome, aspirin will be given soon, though aspirin could be dangerous sometimes like this case. The initial cardiac studies include the routine diagnostic tests for patients with acute coronary syndromes (ECG and cardiac enzymes). The allergy work-up includes assays for serum histamine, tryptase, IgE antibody, and complement proteins (C4 and C1-esterase inhibitor levels) and eosinophil counts... These patients will need systematically cardiac catheterization to assess the coronary anatomy.

The treatment is challenging, since it needs to consider both cardiac and allergic syndromes simultaneously [9]. In type I variant Kounis syndrome, intravenous corticosteroids and antihistamines are recommended [10]. The use of adrenaline is controversial. Revascularization or antithrombotics may be appropriate in type II variants.

Without angiographic evidence or a prior history of an allergic angina-type syndrome, it is difficult to start treating the patient in the emergency department. Once vasospasm is diagnosed through cardiac catheterization, Nitrates and calcium channel blockers are the main treatments. Sublingual or intravenous nitroglycerin often promptly abolishes episodes of angina, and long-acting nitrates are useful in preventing recurrence. Calcium antagonists are extremely effective in preventing the coronary artery spasm, and maximally tolerated doses should be prescribed.

For cardiologists, it is prudent to know that Kounis syndrome exists and can be dangerous. Patients with chronic sinusitis with nasal polyps are at risk of developing salicylate intolerance and allergic reaction with Kounis syndrome. The treatment of these allergic angina pectoris syndromes involves managing both the acute coronary syndrome and the allergic syndrome simultaneously.

References

- [1] Kounis NG, Zavras GM. Histamine-induced coronary artery spasm: the concept of allergic angina. *Br J Clin Pract* 1991;45(2):121–8.
- [2] Goto M, Matsuzaki M, Fuchinoue A, et al.. Chronic atherosclerotic mesenteric ischemia that started to develop symptoms just after anaphylaxis. *Case Rep Gastroenterol* 2012;6:300–8.

- [3] Kounis NG. Kounis syndrome (allergic angina and allergic myocardial infarction): a natural paradigm? *Int J Cardiol* 2006;110:7–14.
- [4] Kounis NG. Kounis syndrome: an update on epidemiology, pathogenesis, diagnosis and therapeutic management. *Clin Chem Lab Med* 2016.
- [5] Kounis GN, Kounis SA, Hahalis G, Kounis NG. Coronary artery spasm associated with eosinophilia: another manifestation of Kounis syndrome? *Heart Lung Circ* 2009;18:163–4.
- [6] Widal MF. Idiosyncratic anaphylaxis. *Presse Med* 1922;30:189–92.
- [7] Samter M, Beers Jr RF. Intolerance to aspirin. Clinical studies and consideration of its pathogenesis. *Ann Intern Med* 1968;68(5):975–83.
- [8] Szczeklik A, Nizankowska E, Mastalerz L, Bochenek G. Myocardial ischemia possibly mediated by cysteinyl leukotrienes. *J Allergy Clin Immunol* 2002;109(3):572–3.
- [9] Cevik C, Nugent K, Shome GP, Kounis NG. Treatment of Kounis syndrome. *Int J Cardiol* 2010;143(3):223–6.
- [10] Kounis NG. Coronary hypersensitivity disorder: the Kounis syndrome. *Clin Ther* 2013;35:563–71.