

Case Report

Bronchopulmonary arteriovenous malformation presenting as cryptogenic hemoptysis in a patient with bicuspid aortic valve

Ujjwal Gorski¹, Madhurima Sharma², Tejeshwar Singh Jugpal¹, Ashish Bhalla³, Manavjit Singh Sandhu¹

¹Department of Radiodiagnosis, Post Graduate Institute of Medical Education and Research, Chandigarh, India, ²Radiodiagnosis, Tanda Medical College, Tanda, Himachal Pradesh, India, ³Department of Internal Medicine, Post Graduate Institute of Medical Education and Research, Chandigarh, India

ABSTRACT

We report the case of a 44-year-old male patient with bicuspid aortic valve, presenting with hemoptysis. Catheter angiography revealed an abnormal communication between bronchial and pulmonary artery, which remained undetected on computed tomography angiography. Angioembolization was done using polyvinyl alcohol and gelfoam particles. This is the first case in literature describing bronchial arteriovenous malformation associated with bicuspid aortic valve.

KEY WORDS: Arteriovenous malformation, bicuspid aortic valve, bronchial, bronchial artery embolization, hemoptysis

Address for correspondence: Dr. Ujjwal Gorski, Department of Radiodiagnosis, Post Graduate Institute of Medical Education and Research, Chandigarh - 160 012, India. E-mail: ujjwalgorski@gmail.com

Submitted: 27-May-2019 **Accepted:** 29-Sep-2019 **Published:** 04-May-2020

INTRODUCTION

Bronchial arteriovenous malformation (AVM) or bronchopulmonary arterial fistula is one of the rare causes of hemoptysis. It is considered a subtype of pulmonary AVM. In literature, 4% of pulmonary AVMs have been reported to have systemic arterial supply and rarely bronchial artery can be the artery feeding the AVM.^[1] Terminology of this rare entity is confusing and it has been called by various names such as angioma, hemangioma, fistula, and malformation.^[1-3] We report an interesting case of bronchial AVM in an adult with bicuspid aortic valve, presenting as cryptogenic hemoptysis.

CASE REPORT

A 44-year-old male patient presented in the outpatient department of our institute with hemoptysis for the last

1 month. Hemoptysis had increased in severity for the last 2 days with associated postural symptoms. The patient was a known case of bicuspid aortic valve and had undergone aortic valve replacement 3 years back. No other significant medical history was present. On examination, the patient had tachycardia (pulse rate: 106/min) and blood pressure was 100/68 mmHg. Chest examination was unremarkable.

Subsequently, the patient was admitted for further workup. Hemoglobin of the patient was 10 g/dl. Coagulation profile was normal. Oxygen saturation at room air was normal (98%). Chest X-ray (not shown here) showed inhomogeneous radiopacity in the left lower zone. Bronchoscopy was done for the patient, which showed a large clot in the lingular segmental bronchus without any

This is an open access journal, and articles are distributed under the terms of the Creative Commons Attribution-NonCommercial-ShareAlike 4.0 License, which allows others to remix, tweak, and build upon the work non-commercially, as long as appropriate credit is given and the new creations are licensed under the identical terms.

For reprints contact: reprints@medknow.com

How to cite this article: Gorski U, Sharma M, Jugpal TS, Bhalla A, Sandhu MS. Bronchopulmonary arteriovenous malformation presenting as cryptogenic hemoptysis in a patient with bicuspid aortic valve. *Lung India* 2020;37:257-9.

Access this article online	
Quick Response Code: 	Website: www.lungindia.com
	DOI: 10.4103/lungindia.lungindia_243_19

active bleed. Computed tomography (CT) angiography was done for the patient (GE Lightspeed VCT, USA). No evidence of bronchial artery hypertrophy or dilatation was seen. Collapse of the lingula was seen. In addition, there was aneurysmal dilatation of the ascending aorta [Figure 1].

Followed by this, the patient was taken up for catheter angiography due to the persistence of hemoptysis and postural symptoms. Digital subtraction angiography was performed through retrograde puncture of the right common femoral artery. Initial diagnostic run of the left bronchial artery showed irregularity and mild dilatation of the distal bronchial artery, which showed abnormal communication with left lower lobe branch of the pulmonary artery. Based on these findings, a diagnosis of bronchial AVM was made. Subsequently, the fistulous tract and left bronchial artery was embolized using polyvinyl alcohol (500–700 μ m) and gelfoam particles. Postembolization run showed no opacification of the fistulous tract [Figure 2]. No recurrence of hemoptysis was reported.

DISCUSSION

Massive hemoptysis is a medical emergency requiring prompt diagnosis and treatment. Imaging studies (X-ray and CT) and bronchoscopy are useful in localization of bleed.^[4] CT angiography is not only useful in localization of bleed but also effective in determining the cause and mechanism of bleed.^[5] However, in up to 25% of cases, the cause of hemoptysis is not revealed by these investigations and is termed as cryptogenic hemoptysis.^[6] Management of cryptogenic hemoptysis remains controversial. In cases of massive hemoptysis, a diagnostic bronchial angiography followed by embolization is recommended.^[7]

Bronchial AVM is one of the rare causes of cryptogenic hemoptysis, where X-ray and CT may be completely normal. Although the exact incidence of bronchial AVM is not known, we have only few case reports describing this rare entity. We have limited knowledge about pathogenesis of this entity. Most bronchial AVMs are thought to be congenital or developmental in origin.^[8] It is believed that bronchopulmonary anastomoses exist in normal lungs at precapillary level^[9] and may enlarge with age in few cases.^[10] Congenital bronchial AVMs are

unilateral (usually on the right side in the middle or lower lobes) and are more common in males.^[1,2] Unlike pulmonary AVM, they do not have association with Osler–Weber–Rendu syndrome.^[11] Bronchial arterial malformations can be acquired secondary to tuberculosis (TB), pneumonia, actinomycosis, neoplasm, or trauma.^[12] In our index case, there was no history of TB, recent infection, or trauma. Except for collapse of the lingula (likely secondary to bronchial obstruction by blood clots), no other abnormality was detected in both the lungs. Hence, we assumed it to be a case of congenital bronchial AVM.

Bronchial AVMs usually present with hemoptysis, cough, or chest pain.^[1,2] However, rarely, they can be detected as incidental finding.^[1] Chest radiograph can be normal or can show parenchymal infiltrates or increased vascular markings.^[1] CT angiography can show abnormal vascular channels with feeding bronchial artery^[12] or direct fistulous communication between bronchial and pulmonary artery.^[8] However, CT angiography may not always depict the vascular abnormality and bronchial AVMs may go unrecognized like in our case.^[13] Due to systemic arterial supply, bronchial AVMs are more prone to rupture than pulmonary AVM and require more definitive management.^[11] Angioembolization is usually the first-line treatment. Surgery is reserved for recurrent cases.

Our case has certain interesting points. First of all, it depicts the limitation of CT in diagnosing this rare entity. Moreover, it highlights the importance of catheter angiography in cases of cryptogenic hemoptysis. However, the decision to proceed with catheter angiography depends on symptoms and hemodynamic stability of the patient. Second interesting finding is its association with bicuspid aortic valve. To our knowledge, this is the first case in literature describing coexisting bronchial AVM with bicuspid aortic valve. Based on the available literature, it is difficult to say whether this is incidental finding or a rare association. Only bronchial artery anomaly described in association with bicuspid aortic valve is in the form of a major aortopulmonary collateral artery arising from the bronchial artery and draining into the right pulmonary artery.^[14] However, the patient has multiple associated vascular anomalies.^[14] In our case, no other significant cardiac or vascular anomaly was present. Other possibility is that the fistula could have been acquired secondary to

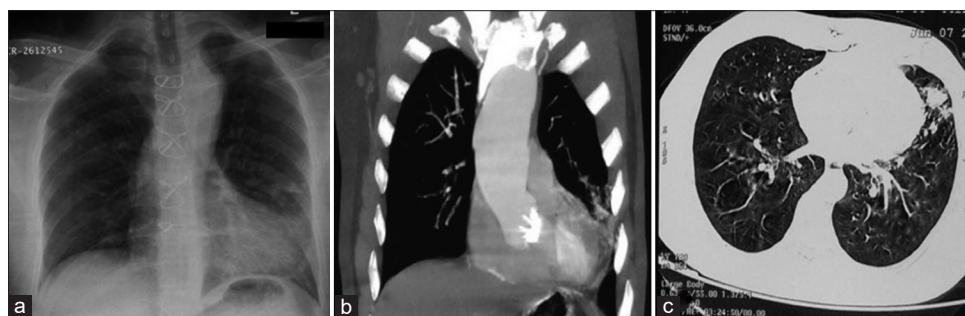


Figure 1: (a) Plain radiograph of the chest shows a focal patchy peripheral area of consolidation in the left middle zone. Note made of sternal suture. (b) Maximum intensity projection coronal image and (c) axial image of the thorax show focal area of consolidation in the lingula. There is also aneurysmal dilatation of the ascending aorta

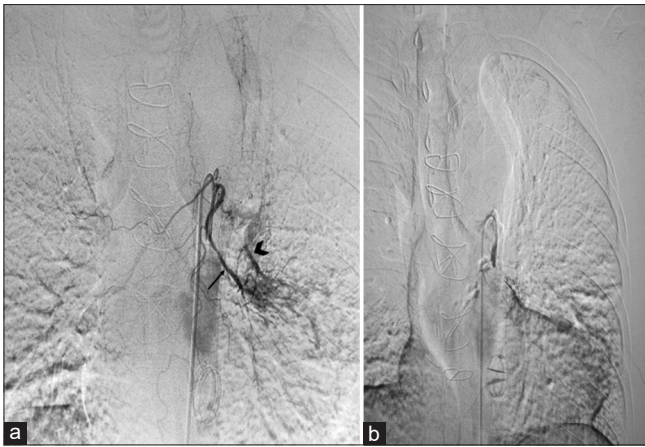

Figure 2: (a) Digital subtraction angiography of the left bronchial artery shows the presence of abnormal communication between the left bronchial artery (arrow) and left lower lobe branch of the pulmonary artery (arrowhead); (b) Post embolization image shows no filling of the abnormal communication

increased hemodynamic stress in bronchial artery due to associated bicuspid aortic valve and thoracic aortopathy.

CONCLUSION

Bronchial AVM is a rare cause of cryptogenic hemoptysis, which may remain undiagnosed on CT angiography. Catheter angiography can show abnormal fistulous communication between bronchial and pulmonary artery. Due to associated high systemic pressure, prompt treatment of this entity is desirable.

Declaration of patient consent

The authors certify that they have obtained all appropriate patient consent forms. In the form the patient(s) has/have given his/her/their consent for his/her/their images and other clinical information to be reported in the journal. The patients understand that their names and initials will not be published and due efforts will be made to conceal their identity, but anonymity cannot be guaranteed.

Financial support and sponsorship

Nil.

Conflicts of interest

There are no conflicts of interest.

REFERENCES

1. Pouwels HM, Janevski BK, Penn OC, Sie HT, ten Velde GP. Systemic to pulmonary vascular malformation. *Eur Respir J* 1992;5:1288-91.
2. Soda H, Oka M, Kohno S, Watanabe M, Takatani H, Hara K. Arteriovenous malformation of the bronchial artery showing endobronchial protrusion. *Intern Med* 1995;34:797-800.
3. Iwasaki M, Kobayashi H, Nomoto T, Arai T, Kondoh T. Primary racemose hemangioma of the bronchial artery. *Intern Med* 2001;40:650-3.
4. Samara KD, Tsetis D, Antoniou KM, Protopapadakis C, Maltezas G, Siafakas NM. Bronchial artery embolization for management of massive cryptogenic hemoptysis: A case series. *J Med Case Rep* 2011;5:58.
5. Chalumeau-Lemoine L, Khalil A, Prigent H, Carette MF, Fartoukh M, Parrot A. Impact of multidetector CT-angiography on the emergency management of severe hemoptysis. *Eur J Radiol* 2013;82:e742-7.
6. Savale L, Parrot A, Khalil A, Antoine M, Théodore J, Carette MF, et al. Cryptogenic hemoptysis: From a benign to a life-threatening pathologic vascular condition. *Am J Respir Crit Care Med* 2007;175:1181-5.
7. Jeudy J, Khan AR, Mohammed TL, Amorosa JK, Brown K, Dyer DS, et al. ACR appropriateness criteria hemoptysis. *J Thorac Imaging* 2010;25:W67-9.
8. Uchiyama D, Fujimoto K, Uchida M, Koganemaru M, Urae T, Hayabuchi N, et al. Bronchial arteriovenous malformation: MDCT angiography findings. *Am J Roentgenol* 2007;188:W409-11.
9. Hasegawa I, Kobayashi K, Kohda E, Hiramatsu K. Bronchopulmonary arterial anastomosis at the precapillary level in human lung. Visualization using CT angiography compared with microangiography of autopsied lung. *Acta Radiol* 1999;40:578-84.
10. Burke CM, Safai C, Nelson DP, Raffin TA. Pulmonary arteriovenous malformations: A critical update. *Am Rev Respir Dis* 1986;134:334-9.
11. van Derploeg DG, Strong WR, Krohmer SJ, O'Connor WN, Martin JT. Congenital bronchial artery to pulmonary artery fistula presenting as hemoptysis. *Ann Thorac Surg* 2015;99:e19-20.
12. Yon JR, Ravenel JG. Congenital bronchial artery-pulmonary artery fistula in an adult. *J Comput Assist Tomogr* 2010;34:418-20.
13. Nugent Z, Oliveira V, Maclusky I, Amaral J, Connolly B, Yang CL. Bronchial artery-pulmonary artery malformation as a cause of cryptogenic hemoptysis. *Pediatr Pulmonol* 2013;48:930-3.
14. Cayre RO, Bayol AP, Obregon R, Alday LE. A unique aortic arterial meshwork with a major aortopulmonary collateral artery, a major arteriovenous collateral artery, and a coronary arteriovenous fistula in a young man with a bicuspid aortic valve. *Pediatr Cardiol* 2013;34:2017-20.