

Unusual cause of acute low-back pain: sudden annulus fibrosus rupture

Ali Fahir Ozer,¹ Tunc Oktenoglu,² Mehdi Sasani,² Tuncay Kaner,³ Omur Ercelen,⁴ Nazan Canbulat⁵

¹Neurosurgery Department, Koc University School of Medicine;

²Neurosurgery Department, American Hospital; ³Neurosurgery Department, Istanbul Medeniyet University School of Medicine; ⁴Anesthesiology and Pain Department, American Hospital;

⁵Physical Treatment and Rehabilitation Department, American Hospital, Istanbul, Turkey

Abstract

Low-back pain is a common problem in neurosurgery practice, and an algorithm has been developed for assessing these cases. However, one subgroup of these patients shares several clinical features and these individuals are not easy to categorize and diagnose. We present our observations for 8 of these patients, individuals with low-back pain caused by atypical annulus fibrosus rupture (AAR). The aim of this study is to show the consequences of overlooked annular tears on acute onset of low back pain. Eight patients with acute-onset severe low-back pain were admitted. Physical examinations were normal and each individual was examined neurologically and assessed with neuroradiologic studies [plain x-rays, magnetic resonance imaging (MRI), discography and computed tomography (CT) discography]. AAR was ultimately diagnosed with provocative discography. In all cases, MRI showed a healthy disc or mild degeneration, whereas discography and CT discography demonstrated disc disease. Anterior interbody cage implantation was performed in 3 of the 8 cases and posterior dynamic stabilization was carried out in 3 cases. The other 2 individuals refused surgery, and we were informed that one of them developed disc herniation at the affected level 1 year after our diagnosis. Clinical and radiological outcomes were evaluated. In cases where AAR is suspected, MRI, discography, and CT discography should be performed in addition to routine neuroradiologic studies.

Introduction

Chronic discogenic pain has many known and suspected causes. One of the proposed

cause is the tearing of the annulus fibrosus of the disc, due to gradual disc degeneration, which results in decreased resistance to loading and altered histochemical structure.^{1,2} In cases of torn annulus fibrosus, magnetic resonance imaging (MRI) typically shows no obvious disc herniation, but only disc degeneration. The pain is not radicular, but it has somatotopic characteristics and is most likely transmitted by the paravertebral sympathetic chain.^{1,3}

Most individuals, admitted to hospital with low-back pain, have a long history of unsuccessful non-operative therapy. Many of these cases are eventually managed surgically out of desperation on both the surgeon's and the patient's part. However, another group of these patients exists. Some individuals who present with low-back pain have no history of this problem and have developed acute pain after a sudden abnormal low-back movement, heavy lifting, or trauma. In such cases, computed tomography (CT), myelography, and MRI are usually normal or show minimal degenerative changes. Most of these patients experience no radicular pain and have no symptoms or other findings that suggest radicular compression; thus, they are often diagnosed with muscle spasm or facet joint pain. However, clinical reports and our observations suggest that, at least in some cases, the pain is due to atypical annular rupture (AAR).^{4,6}

The aim of this article is to present our clinical experience with AAR and to underline that this is a rare and unique clinical entity. AAR should be suspected in any patient who develops acute-onset low-back pain after sudden axial loading on the back, who exhibits no obvious cause of pain on plain x-rays and MRI, and who does not respond well to conservative treatment.

Materials and Methods

Between the years 2000 and 2008, 8 patients with the singular issue of sudden-onset low-back pain were admitted to the Neurosurgery Department of VKV American Hospital and underwent comprehensive workup. The details of these cases are presented below.

Patient #1

A 30-year-old woman presented with acute-onset low-back pain. She had developed this sharp pain 1 month earlier while performing aerobic exercises. Prior to presentation, the patient had had two visits to a physical therapist. She had been advised to undergo bed rest and treatment with non-steroidal anti-inflammatory drugs (NSAIDs), and a physical therapy program. Neither conservative therapy nor physical therapy was helpful. T2-weighted MRI showed intradiscal signal changes at the L3-4 and L4-5 levels. Discography and CT discogra-

Correspondence: Ali Fahir Ozer, Koc University School of Medicine, Department of Neurosurgery, Rumelifeneri Yolu, Sariyer, Istanbul 34450, Turkey.
Tel. +90.212.3381401 - Fax: +90.212.3381559.
E-mail: alifahirozer@gmail.com

Key words: atypical annulus fibrosus rupture, CT discography, low-back pain.

Conflict of interests: the authors report no potential conflict of interests.

Received for publication: 4 April 2012.

Revision received: 24 May 2012.

Accepted for publication: 25 May 2012.

This work is licensed under a Creative Commons Attribution NonCommercial 3.0 License (CC BY-NC 3.0).

©Copyright A.F. Ozer et al., 2012
Licensee PAGEPress, Italy
Orthopedic Reviews 2012; 4:e22
doi:10.4081/or.2012.e22

phy revealed escape of contrast material into the epidural space at the L4-5 level (Figure 1). During injection into the L4-5 intervertebral disc, the patient's pain increased significantly. She underwent surgery with anterior interbody cage technique at the L4-L5 level and was discharged on the 4th postoperative day. Preoperative visual analog scale (VAS) score 9 decreased 2, similarly Oswestry Disability Index (ODI) 92 come to 16 at postoperative one year. This patient remains pain-free at 7 years of follow-up.

Patient #2

A 35-year-old woman experienced acute onset of low-back pain after heavy lifting. The patient received conservative therapy (naproxen sodium, mephenoxalone and paracetamol) and underwent 1 month of physical therapy. Neither of these modes of treatment was helpful. Lumbar MRI revealed nothing abnormal. Discography and CT discography showed escape of contrast into the L5-S1 epidural space (Figure 2). Injection of contrast into the L5-S1 disc caused the patient's pain to increase significantly. Surgical intervention was carried out with anterior interbody cage technique at the L5-S1 level. The patient was discharged on the 4th postoperative day and remains pain-free at 7 years of follow-up. Preoperative VAS score 8 decreased 1, similarly ODI 80 come to 12 at postoperative one year.

Patient #3

A 23-year-old man was admitted after he developed sudden-onset severe low-back pain

while playing soccer. He was offered conservative NSAID treatment (diclofenac potassium 50 mg 3×1 and tizanidine hydrochloride 2 mg 2×) and physical therapy. The patient was admitted to our department 6 weeks after the pain began. Neurological examination and MRI revealed no abnormalities; however, discography and CT discography showed escape of contrast medium into the L5-S1 epidural space (Figure 3). Injection of contrast into the L5-S1 intervertebral disc resulted in significant low-back pain. The patient was operated on with an anterior interbody cage technique and was discharged on the 4th postoperative day. He is currently pain-free after 5 years of follow up. Preoperative VAS score 10 decreased 2, similarly ODI 72 come to 8 at postoperative one year.

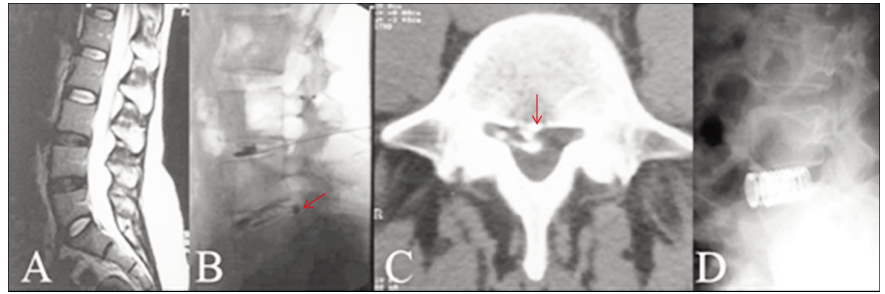


Figure 1. A) Sagittal T2-weighted magnetic resonance imaging showing degeneration of the L3-4 and L4-5 intervertebral discs and mild loss of lumbar lordosis; B) discography demonstrating the tear in the annulus fibrosus of the L4-5 intervertebral disc; C) computed tomography discography showing escape of contrast medium into the spinal canal; D) A postoperative lateral lumbar radiograph of the patient.

Patient #4

A 22-year-old man developed acute low-back pain while doing intense military exercises. He was treated with bed rest and analgesics (diclofenac potassium 50 mg 3×1 and tizanidine hydrochloride 2 mg 2×1). The patient was admitted to our clinic 1 month after the onset of pain. His daily activities were significantly limited by its severity and he was also experiencing severe, painful muscle spasms while coughing. There were no abnormal findings on neurological examination or MRI, but discography and CT revealed a tear in the annulus fibrosus of the L4-5 intervertebral disc (Figure 4). Injection into the L4-5 disc caused intense pain. The patient was offered surgical intervention, but did not accept this because of issues related to his job. He was offered medical and physical therapy, but 1 year after initial onset he was still suffering low-back pain. Subsequently, he underwent surgery at another center for disc herniation at L4-5 level. Preoperative VAS score 10 decreased 1, similarly ODI 64 come to 12 at postoperative one year.

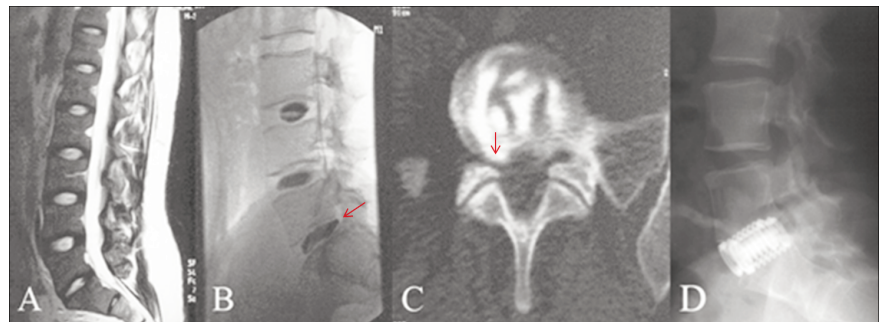


Figure 2. A) Sagittal T2-weighted magnetic resonance imaging showing loss of lumbar lordosis; B) discography showing an annulus fibrosus tear of the L5-S1 disc; C) computed tomography discography showing contrast material in the spinal canal (note the annulus tear near the right foramen of the foraminal location); D) a postoperative lateral lumbar radiograph of the patient.

Patient #5

A 32-year-old man was admitted to our clinic with acute low-back pain. The pain had come on suddenly while he was lifting weights at the gym. The patient underwent conservative treatment and 4 weeks of physical therapy, but there was no response to either regimen. Neurologic examination and MRI revealed nothing abnormal. Discography and CT discography showed an annulus fibrosus tear in the L5-S1 disc (Figure 5). During injection into the L5-S1 disc, the patient's pain spiked significantly. He was offered surgical treatment but declined. Medical and physical therapy were offered and he was still experiencing low-back pain 8 months after the initial onset. Preoperative VAS score 10 decreased 2, similarly ODI 70 come to 6 at postoperative one year.

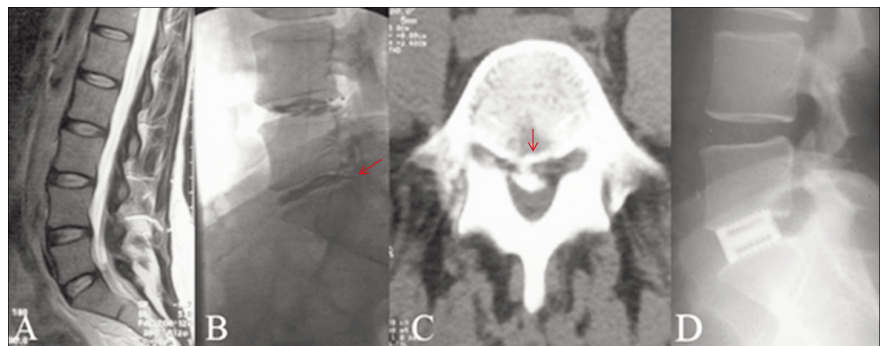


Figure 3. A) Sagittal T2-weighted magnetic resonance imaging showing mild loss of lordosis; B) discography showing an annulus fibrosus tear in the L5-S1 disc (note the contrast medium in the spinal canal); C) computed tomography discography showing contrast material in spinal canal (note the central location of the annulus fibrosus tear); D) a postoperative lateral lumbar radiograph of the patient.

Patient #6

A 27-year-old woman presented to our department with acute low-back pain. The pain had started acutely after exercise and had been present for 1 month. There was no response to conservative medical treatment or physical therapy. Her neurologic examination was normal. Lumbar MRI showed L4-L5 disc degeneration, and discography and CT demonstrated escape of contrast into the L4-L5 epidural space (Figure 6). The patient underwent surgery with posterior dynamic stabilization (Saphinas system- Medikon company). She was discharged on the 3rd postoperative day and was pain-free at 17 months of follow-up. Preoperative VAS score 10 decreased 3, similarly ODI 64 come to 4 at postoperative one year.

Patient #7

A 25-year-old woman presented with acute-onset low-back pain. She had developed sudden pain after heavy lifting. She did not respond to repeated conservative therapy or physical therapy. Neurologic examination and MRI were normal but discography and CT discography showed a lateral tear in the annulus fibrosus of the L4-L5 disc (Figure 7). Surgical intervention was carried out with posterior dynamic stabilization (Saphinas system- Medikon company). The patient was discharged on the 7th postoperative day and is pain-free at 1 year of follow up. Preoperative VAS score 8 decreased 1, similarly ODI 60 come to 2 at postoperative one year.

Patient #8

A 45 year old woman presented with acute-onset of low back pain.

First attack occurred one month ago. Neurologic examination was normal at the time and her pain improved with anti-inflammatory drugs and analgesics. However, she admits anxiety lest a sudden onset of back pain should start. She felt a sudden back pain following a minor back movement one day before she was admitted to the hospital, her neurologic exam was free of pathology but she described severe back pain.

MRI examination showed mild degeneration findings of L4-5 disc and discography revealed an anterior defect of annulus with positive pain provocation (Figure 8). Surgical intervention was carried out with posterior dynamic stabilization (Cosmic system-Ulrich Company).

The patient was discharged on the 3rd postoperative day and was pain-free at her 1 month of follow up. Preoperative VAS score 9 decreased 1, similarly ODI 56 come to 4 at postoperative one year.

Results

All these patients' clinical and radiological outcomes were evaluated. In all cases, MRI during case work-up suggested a healthy disc or only mild degeneration, whereas discography and subsequent CT discography demonstrated disc disease. We performed interbody fusion and instrumentation until 2003 therefore three of the 8 patients underwent anterior interbody cage placement. After that in such chronic instability we performed transpedicular dynamic stabilization in our routine practice. So that last 3 patients underwent posterior dynamic stabilization, and 2 refused surgery. As noted, we learned that one of the indi-

viduals who declined surgical treatment developed disc herniation at the same level 1 year later. The patients' clinical histories are summarized in Table 1. All these patients were very painful preoperative period and most of them were examined in emergency service. The pain decreased sharply just after the operation and all the patients remains pain-free at 2-7 years of follow-up. Radiological outcomes were satisfactory.

Discussion

The literature contains no reports on large series of patients with low-back pain associat-

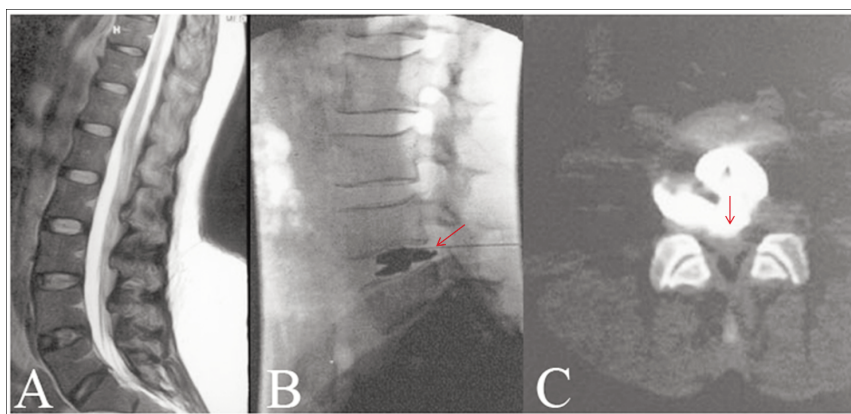


Figure 4. A) Sagittal T2-weighted magnetic resonance imaging showing nothing abnormal; B) discography showing contrast medium in spinal canal; C) computed tomography discography demonstrating a wide-based annulus fibrosus tear.

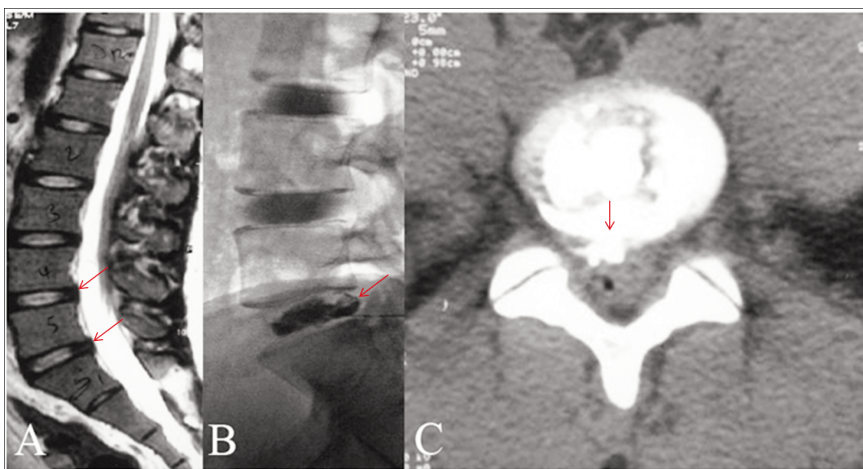


Figure 5. A) Sagittal T2-weighted magnetic resonance imaging showing only mild bulging of L4-5 and L5-S1 intervertebral discs; B) Discography revealing an annulus fibrosus tear in the L5-S1 disc; C) computed tomography discography showing contrast material in the spinal canal.

ed with AAR. These tears of the annulus fibrosus are diagnosed with discography, and numerous authors have stated that such cases are difficult to diagnose on MRI.^{4,5} In our clinic, we routinely performed discography and CT discography in appropriate cases and found that a unique group of patients emerged. In all instances, MRI indicated normal to mild degeneration of intervertebral discs and no clear sign of an annular defect; however, discography demonstrated an annulus fibrosus tear. These patients shared several clinical and demographic features: i) otherwise healthy individuals approximately 30 years of age; ii) no previous distinct history of low-back pain; iii) initiation of pain was associated with an abnormal low-back movement, heavy lifting, or exercise. In all cases, there was no radicular pain, MRI was either normal or showed only nonspecific changes, and conservative measures and physical therapy were unsuccessful.

MRI and CT discography may both be important tools for evaluating discogenic pain.⁷ It is particularly difficult to identify the cause of low-back pain with MRI if the patient has multiple degenerated discs. Demonstration of a high-intensity zone on MRI has been shown to indicate back pain;⁸ however, we observed no high-intensity zones on MRI in our 8 patients. There is conflict about these zones in the literature for 15 years. Some authors state that presence of a high-intensity zone supports the diagnosis of annular rupture, but postulate that if the tear is under the anterior longitudinal ligament then no high-intensity zone will be visible on MRI.⁹ On the other hand, recent studies have revealed that high-intensity zones can be seen on MRI in the absence of low-back pain and are not associated with any particular group of clinical symptoms.¹⁰⁻¹² In a cadaver study, Yu *et al.* identified 3 types of annulus fibrosus tears.¹³ One of these, Type I tears (concentric tears), is characterized by rupture of the transverse fibers that connect adjacent lamellae in the annulus, with no disruption of the longitudinal fibers. The authors noted that these tears were not seen on MRI, and this is in line with the MRI findings in our 8 cases.

There is still some debate about the value of discography as a diagnostic tool for investigating painful black disc disease.¹⁴ After injecting contrast medium into the disc, appearance of contrast in the epidural or paravertebral space at the affected level supports the clinical diagnosis of AAR.^{4,5} However, it has also been reported that contrast can escape into the epidural space as a result of benign disc degeneration. In such cases, discography can give a false-positive result.^{14,15} Carregee *et al.*¹⁶ concluded that specificity of discography have led us to proceed much more cautiously in interpreting the results of discography. Chronic low back pain illness seriously chal-

lenges the specificity of provocative discography in identifying a clinically relevant spinal pathology.¹⁷ Discography is difficult to evaluate as a diagnostic procedure and there are no data on false-positive discography results in patients with healthy intervertebral discs.

As noted in our cases, discography can also be used as a provocative test.¹⁸ Injection of contrast material into the intervertebral disc typi-

cally results in increased intradiscal pressure. This can cause severe pain and may pinpoint the source of a patient's low-back pain. However, when a patient has chronic disc degeneration due to multiple annulus fibrosus tears, the injected material can easily escape into the epidural space and, thus, does not cause increased intradiscal pressure in these cases. Conversely, in the case where a healthy

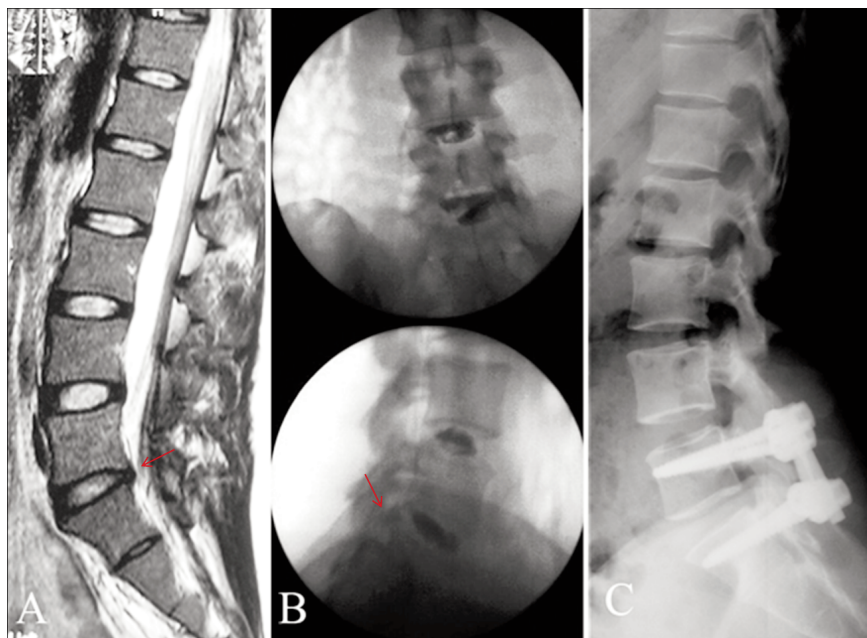


Figure 6. A) Sagittal T2-weighted magnetic resonance imaging showing degeneration of the L5-S1 intervertebral disc and mild loss of lumbar lordosis; B) Discography demonstrating the annulus fibrosus tear of the L5-S1 intervertebral disc; C) A postoperative lateral lumbar radiograph of the patient.

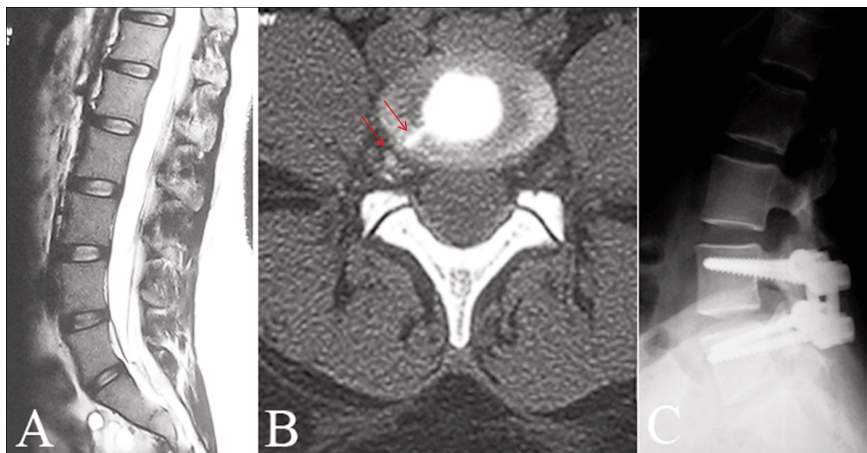


Figure 7. A) Normal sagittal T2-weighted magnetic resonance imaging; B) computed tomography discography showing contrast medium in the spinal canal and vertebral foramen (note the lateral location of the annulus fibrosus tear); C) a postoperative lateral lumbar radiograph of the patient.

disc sustains an annulus rupture, discography can be more useful as significant pain is generated during the test and contrast medium appears in the epidural space. Therefore, in cases of acute-onset low-back pain where there is no other cause of lumbar pain and MRI indicates a healthy disc with only minor changes, discography may be the only tool that is diagnostic.¹⁹ Discography can pinpoint the source of pain and demonstrate AAR, as demonstrated in our 8 cases. In cases of suspected AAR, it is important to rule out other possible causes of pain, such as soft-tissue injury, pathologies of the coxofemoral joint, and painful sacroileitis. It is also recommended to perform CT discography to determine the location and shape of the annulus fibrosus tear, and we did this in our cases as well.^{18,20}

The treatment algorithm for patients with confirmed AAR is the same as that used in cases of painful black disc disease. The first step in treating AAR is conservative treatment with minimum 6 weeks of conservative treatment and bed rest. The second step is to use techniques such as intradiscal electrothermal treatment, and these may be helpful.^{2,21}

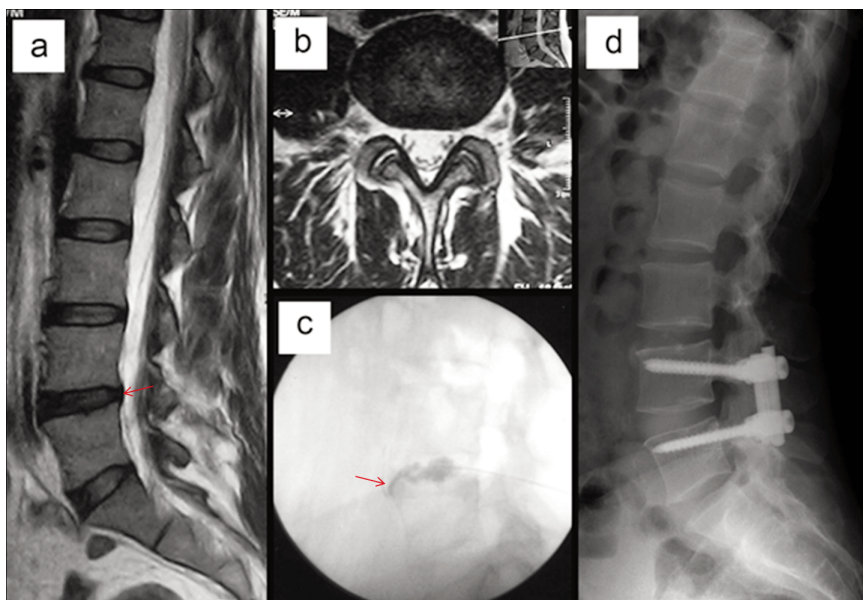


Figure 8. A) Mild degeneration findings of L4-5 disc with sagittal T2 weighted magnetic resonance imaging view; B) axial view; C) leakage of contrast medium through anterior annulus defect; d)postoperative stabilization of the patient's with dynamic screws (Cosmic-Ulrich company).

Table 1. Patient demographic data.

Case No.	Age (yrs)	Sex	Radiologic Findings (MRI/discography, CT discography)	Spinal Level	Complaints	Treatment	Complications	Outcome
1	30	F	Intradiscal signal changes/contrast in the L4-L5 epidural space	L3-L4 and L4-L5	Acute onset of low-back pain	Surgery - anterior interbody cage at L4-L5	None	Improved
2	35	F	Normal/contrast in the L5-S1 epidural space	L5-S1	Acute onset of low-back pain	Surgery - anterior interbody cage at L5-S1	None	Improved
3	23	M	Normal/contrast in the L5-S1 epidural space	L5-S1	Acute onset of severe low-back pain	Surgery - anterior interbody cage at L5-S1	None	Improved
4	22	M	Norma/annulus fibrosus tear of the L4-L5 intervertebral disc	L4-L5	Acute onset of low-back pain	Declined surgical treatment; medical and physical therapy offered	None	One year after initial pain onset, still suffering low-back pain
5	32	M	Normal/annulus fibrosus tear of the L5-S1 disc	L5-S1	Acute onset of low-back pain	Declined surgical treatment; medical and physical therapy offered	None	Eight months after initial pain onset, still suffering low-back pain
6	27	F	L4-L5 disc degeneration/contrast in the L4-L5 epidural space	L4-L5	Acute onset of low-back pain	Surgery - posterior dynamic stabilization system	None	Improved
7	25	F	Normal/lateral annulus fibrosus tear in the L4-L5 disc	L4-L5	Acute onset of low-back pain	Surgery - posterior dynamic stabilization system	None	Improved
8	45	F	Intradiscal signal changes	L4-L5	Acute onset of low-back pain	Surgery - posterior dynamic stabilization system	None	Improved

MRI, magnetic resonance imaging; CT, computed tomography.

The anatomical characteristics of the affected region are very complex. Widespread distribution of nociceptive afferents of the annulus fibrosus and nearby ligaments technically limit access to the annulus from any direction.²² For patients who do not respond to steps 1 or 2 of treatment, surgical stabilization of the painful segment is the next option. This typically involves one of the various fusion techniques, posterior dynamic stabilization, or disc replacement depending on the surgeon's experience.

Conclusions

Discography should be used in any case of suspected annulus fibrosus rupture. Patients with AAR should be comprise as a distinct subgroup of individuals with low-back pain. MRI is not always helpful, especially if low quality (e.g. 1.5 Tesla) or insufficient sequences were presented for diagnosing annulus fibrosus tears. Conservative treatment and minimally invasive pain therapies, such as intradiscal electrothermal treatment, should be tried initially. If symptoms persist, surgery is recommended.

References

1. Bogduk N, Windsor M, Ingles A. The innervation of the cervical intervertebral disc. *Spine* 1988;13:2-8.
2. Saal JA, Saal JS. Intradiscal electrothermal treatment for chronic discogenic lowback pain. A prospective outcome study with minimum 1 year follow-up. *Spine* 2000;25:2622-7.
3. Suseki K, Takahashi X, Takahashi K. Innervation of the lumbar facet joints. Origins and functions. *Spine* 1997;22:477-85.
4. Schneiderman G, Flanigan B, Kungston S, et al. Magnetic resonance imaging in the diagnosis of disc degeneration. Correlation with Discography. *Spine* 1987;12:276-81.
5. Zucherman J, Derby R, Hsu K, et al. Normal MRI with abnormal discography. *Spine* 1988;13:1355-9.
6. Hyodo H, Sato T, Sasaki H, Tanaka Y. Discogenic pain in acute nonspecific low-back pain. *Eur Spine J* 2005;14:573-7.
7. Vernon-Roberts B, Pirie CJ. Degenerative changes in the intervertebral discs of the lumbar spine and their sequelae. *Rheumatol Rehabil* 1977;16:13-21.
8. Aprill C, Bogduk N. High intensity zone. A diagnostic sign of painful lumbar disc on magnetic resonance imaging. *Br J Radiol* 1992;65:361-9.
9. Saifuddin A, Mc Sweney E, Lehovsky J. Development of lumbar-high intensity zone on axial loaded magnetic resonance imaging. *Spine* 2003;28:448-52.
10. Carragee EJ, Hannibal M. Diagnostic evaluation of low back pain. *Orthop Clin North* 2004;35:7-16.
11. Munter FM, Wasserman BA, Wu HM, Yousem DM. Serial MR imaging of anular tears in lumbar intervertebral discs. *Am J Neuroradiol* 2002;23:1105-9.
12. Rankine JJ, Gill KP, Hutehinson CE. The clinical significance of the high intensity zone on lumbar spine magnetic imaging. *Spine* 1999;24:1913-9.
13. Yu S, Sether LA, Ho PS, et al. Tears of the annulus fibrosus. correlation between MR and pathologic findings in cadavers. *AJNR Am J Neuroradiol* 1988;9:367-70.
14. Wolfer LR, Derby R, Lee JE, Lee SH. Systematic review of lumbar provocation discography in asymptomatic subjects with a meta-analysis of false-positive rates. *Pain Physician* 2008;11:513-38.
15. Nachemson A. Lumbar discography where are we today. *Spine* 1989;14:555-7.
16. Carragee EJ, Alamin TF. Discography: a review. *Spine J* 2001;1:364-72.
17. Carragee EJ, Alamin TF, Miller J, Grafe M. Provocative discography in volunteer subjects with mild persistent low back pain. *Spine J* 2002;2:387-8.
18. Carragee EJ, Lincoln T, Parmar VS, Alamin T. A gold standard evaluation of the discogenic pain diagnosis as determined by provocative discography. *Spine* 2006;31:2115-23.
19. Montes Garcia C, Nava Granados LF. Evocative lumbar discography. *Acta Ortop Mex* 2007;21:85-9.
20. Suchs BL, Vanharanta H, Spivey MA, et al. Dallas discogram description. A new classification of CT/discography in low back disorders. *Spine* 1987;12:287-94.
21. Pomerantz SR, Hirsch JA. Intradiscal therapies for discogenic pain. *Semin Musculoskelet Radiol* 2006;10:125-35.
22. Lee J, Lutz GE, Campbell D. Stability of the lumbar spine after intradiscal electrothermal therapy. *Arch Phys Med Rehabil* 2001;82:120-3.