


## SURGICAL TECHNIQUE

# Combination of Clavicular Hook Plate with Coracoacromial Ligament Transposition in Treatment of Acromioclavicular Joint Dislocation

Aikebaier Tuxun<sup>1</sup>, Ajimu Keremu<sup>1</sup>, Pazila Aila<sup>1</sup>, Maimaitiaili Abulikemu<sup>1</sup>, Zengru Xie<sup>2</sup>, Palati Ababokeli<sup>2</sup> 

<sup>1</sup>Department of Orthopedics, The First People's Hospital of Kashgar Prefecture, Kashgar and <sup>2</sup>Department of Orthopedic Center, The First Affiliated Hospital of Xinjiang Medical University, Urumqi, China

**Objective:** To evaluate the clinical efficacy of Arbeitsgemeinschaft für Osteosynthesefragen (AO) clavicular hook plate (CHP) combined with coracoacromial ligament transposition for Rockwood III-V dislocation of AC joint, providing an alternative choice for AC joint dislocation treatment.

**Methods:** Twenty-five patients diagnosed with Rockwood III-V dislocation of acromioclavicular (AC) joint, including 18 males and seven females, aged  $43.5 \pm 2.4$  years old on average, who had undergone open reduction and AO CHP in combination with coracoacromial (CC) ligament transposition between January 2010 and December 2015, were retrospectively analyzed. Among them, 17 cases were diagnosed as type III, five cases were type IV, and three cases were type V. The surgery mainly included three main steps: bone flap incision, drilling in the clavicle, and hook plate fixation and AC joint reposition. The treatment efficacy was evaluated through clinical examinations and imaging studies for the shoulder joint, including gross observation and measuring coracoid clavicle distance (CC-Dist) using orthophoria X-ray before and 1 year after the surgery, and University of California (UCLA) shoulder rating scale.

**Results:** All the patients were followed up three to four times in 18 months (12–24 months) on average, and the UCLA rating results showed that there were 17 excellent cases (68%), five good cases (20%), and three fair cases (12%). The CC-Dist values after the surgery reduced to  $9.7 \pm 0.7$  mm, which was significantly ( $P < 0.05$ ) lower compared to that before the surgery ( $15.8 \pm 1.6$  mm). Most (88%) of the cases showed almost normal joint function and good anatomical arrangement of the acromioclavicular joint, without any secondary dislocation, and for them,  $12 \pm 2$  weeks on average were needed to regain the normal function of shoulder joint movement.

**Conclusion:** Due to the stable fixation, fewer complications, and satisfactory therapeutic effect with great clinical value, the combination of AO CHP and CC ligament transposition is expected to be used for treating Rockwood III-V dislocation of AC joint.

**Key words:** Acromioclavicular dislocation; Clavicular hook plate; Coracoacromial ligament transposition; Coracoclavicular ligament; Reconstruction

## Introduction

Acromioclavicular (AC) joint dislocation is a fairly common injury in orthopaedic disorders, accounting for about 12%–16% of shoulder injuries<sup>1</sup>. The grade of AC joint dislocation results from its direct stabilizers (joint capsule

and articular disc) damage, mostly due to coracoclavicular ligament rupture. In 1963, Tossy *et al.*<sup>2</sup> classified the AC joint dislocation into three degrees and considered that degree I or II should adopt conservative treatment, while degree III required open reduction and fixation instead.

**Address for Correspondence** Z Xie or P Ababokeli, Department of Orthopedic Center, The First Affiliated Hospital of Xinjiang Medical University, Urumqi, China 830054 Tel: 86-13175005186; Fax: 86-991-4361292; Email: xiezenru@126.com (Xie); polat2014@sina.cn or min4su@163.com (Ababokeli)

**Disclosure:** None.

Received 31 August 2020; accepted 22 November 2021

Rookwood then divided the dislocation into six types on the basis of the three-grade Tossy classification<sup>3</sup>.

Because of the unstable osseous structure of the AC joint, the firm connection between the clavicle and the scapula mainly depends on the surrounding ligaments, especially the coracoclavicular ligaments which are used to resist the stress of dislocation. It plays an important role in maintaining the stability of the distal AC joint<sup>4</sup>. Its fibers are divided into two parts, the conoid and trapezoid ligaments. If the two ligaments were ruptured, the distal clavicle will move upwards which gives rise to the AC joint dislocation<sup>5</sup>.

The treatment of AC joint dislocation is currently controversial. Severe AC joint dislocation will result in the destruction of anatomic structure of the joint capsules, AC ligament and coracoclavicular ligaments. Nevertheless, coracoclavicular ligaments play a central role in maintaining the stability of AC joint. Due to the anatomical location and other reasons, it is difficult to directly repair the coracoclavicular ligaments after dislocation, and the effect is not as good as people expected after conservative treatment. Therefore, most experts choose to perform surgical treatment for patients with severe AC joint dislocation, but there is still controversy regarding the specific details of the operation, complications, or whether internal fixation should be withdrawn or not. For patients who are diagnosed with Rockwood type I or II AC joint dislocation, non-surgical approach may be the optimal choice. However, scholars have been inclined to apply surgical methods to patients with Rockwood type III–V dislocation. In recent years, advantages like easy operating, higher joint mobility and clavicle-like design have been well-recognized by the orthopaedists when using internal fixation with clavicular hook plate for treating patients with moderate or severe AC joint dislocation<sup>6,7</sup>. However, the internal fixation alone without ligament repair and construction may not be sufficient to maintain the stability of AC joint and will result in a high recurrence rate of dislocation<sup>8</sup>. It has been proven that coracoacromial ligament transposition is an effective way to reconstruct the coracoclavicular ligament<sup>9</sup>.

In the present study, we aimed to: (i) evaluate the clinical efficacy of Arbeitsgemeinschaft für Osteosynthesefragen (AO) clavicular hook plate combined with coracoacromial ligament transposition for Rockwood III–V dislocation of AC joint; (ii) find a better, at least alternative, method to treat Rockwood III–V dislocation of AC joint with stable fixation, fewer complications, and satisfactory therapeutic effect; and, finally, (iii) trigger orthopaedists to explore more beneficial treatments for their patients.

## Patients and Methods

### Patient Population

Between January 2010 and December 2015, we treated 25 patients affected by AC joint dislocation. This research has been approved by the internal research board of the authors'

affiliated institutions and written informed consent has been obtained from each patient. Inclusion criteria: (i) severe AC joint dislocation (Rockwood III–V); (ii) underwent open reduction and clavicular hook plate in combination with coracoacromial ligament transposition; (iii) follow-up for more than 9 months. Exclusion criteria: (i) AC joint dislocation with neural or vascular injuries of the upper extremity; (ii) AC joint dislocation with other fractures and dislocations in ipsilateral upper extremity; (iii) AC joint dislocation with a history of chronic shoulder pain which will affect the postoperative functional assessment.

## Surgical Techniques

### Bone Flap Incision

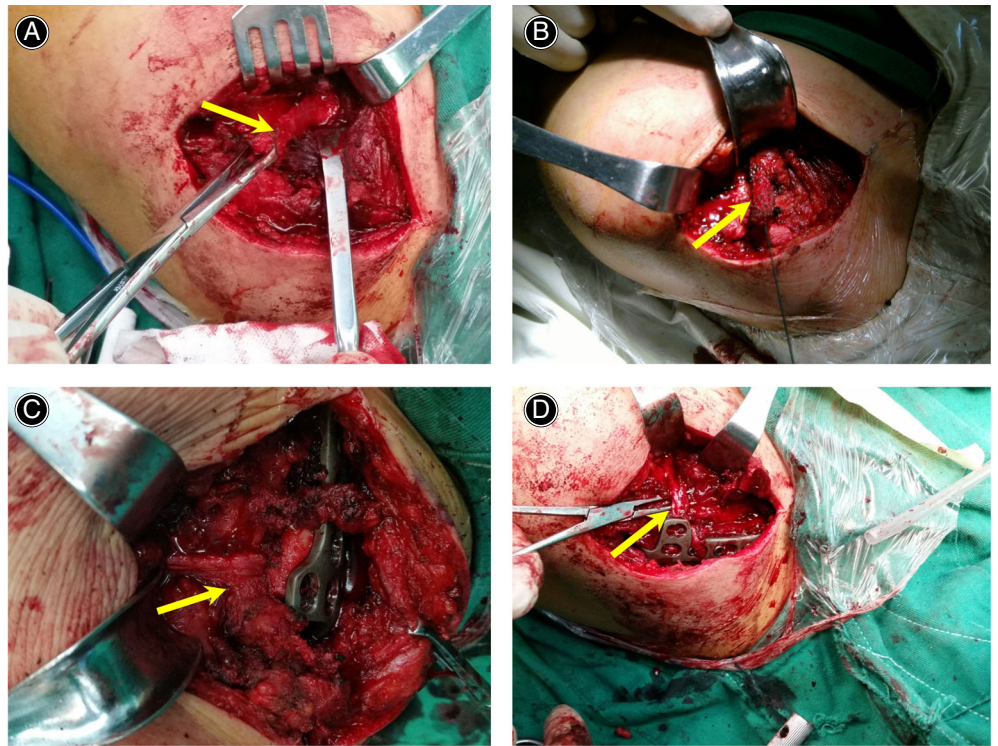
The surgery was performed in the supine position with brachial plexus and cervical plexus block anesthesia. Sterile preparation and draping are used as for common procedures. The AC joint, together with distal clavicle and coracoid, were exposed with an arc incision. After the frayed articular disc was removed, the coracoacromial ligament was exposed. A bone flap with a size of 1 cm × 1 cm was taken from where the coracoclavicular ligament attached to the summit of the acromion using an AO osteotome (SHINVA Medical Instrument, Shandong, China; Fig. 1A).

### Drilling in the Clavicle

After reposition of the AC joint and determination of the fixed position of the bone flap in the clavicle, we temporarily fixed the joint with a K-wire (Bojin Medical Instrument, Shanghai, China). According to the size of the bone flaps, drills (Bojin Medical Instrument) with diameters of 2.8 mm, 3.5 mm, 3.8 mm, and 4.2 mm were chosen to drill holes at the predetermined position of the distal clavicle, which is the anatomic landmark in conical nodules of the clavicle by X-ray (SIEMENS, Erlangen, Germany; Fig. 2). Because the distal bone of the clavicle is relatively thin, the holes were drilled obliquely in the clavicle in order to increase the contact area between the cavity and the bone flap.

### Hook Plate Fixation and AC Joint Reposition

The ligament coracoclavicular was sewed into a shape of a bundle with hemstitch suture (Fig. 1B). The bone flap was trimmed into a wedge and then put into the cavity. The hook part of the plate (Johnson & Johnson Medical Devices Companies, Shanghai, China) was inserted into the posterior face of AC joint (Fig. 1C). It is required to push the hook towards the back of the shoulder, so that the collisions of hook tip and humeral head can be avoided. After confirming that no impact has occurred, the plate was finally locked and fixed (Fig. 1D). At this time, it can be seen that the AC joint is completely repositioned. The damaged AC joint capsule was sutured with Ethicon #1 sutures (Ethicon LLC, Lote Bravo, Ciudad Juarez, Chihuahua, Mexico), and the broken deltoid and trapezius muscles were carefully sutured. To better understand the key



**Fig. 1** Surgical procedure.

(A) Coracoclavicular ligament with bone flap was taken with osteotome; (B) Coracoclavicular ligament was sewed with Ethicon sutures to form a bundle-shape; (C) The bone flap was inserted into the cavity drilled in the clavicle and the clavicular hook plate was fixed; and (D) The well-fixed coracoclavicular ligament with appropriate tension after transposition.

procedures in the surgery, please see the surgical diagrams shown in Fig. 3.

### **Postoperative Evaluation**

#### *Postoperative Rehabilitation*

All patients were handled with antibiotics for 1 day and had their drainage catheters removed after the surgery. The patients were prohibited from moving by fixation with triangle bandage for 3 weeks and started voluntary exercise on the elbow, wrist, and hand of the affected limb the same day after surgery. Pronation and supination of the shoulder joint

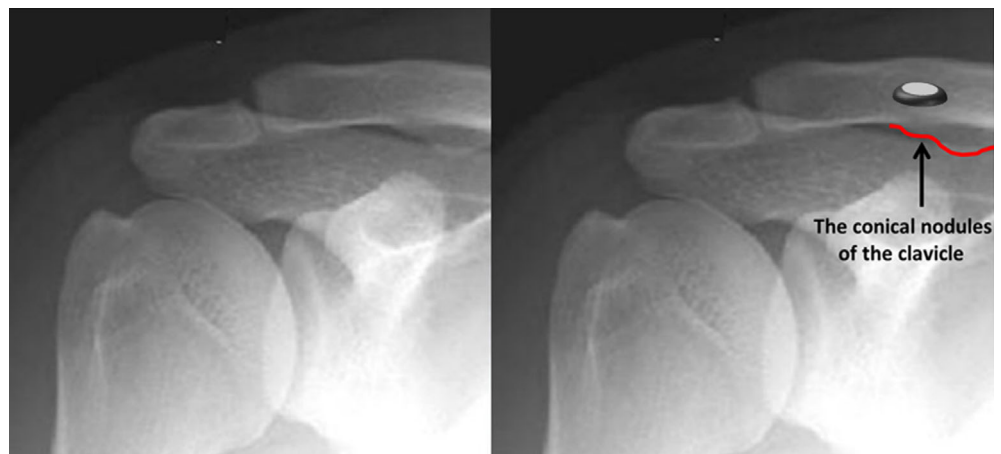
started at 6 to 8 months. The clavicular hook plates were removed 6 to 12 months after the operation.

#### *Clinical Examinations*

Follow-up clinical examinations were performed after surgery: orthophoria X-ray imaging of the shoulder joint was performed regularly; regular ultrasound examination was performed at 3 and 6 months, respectively.

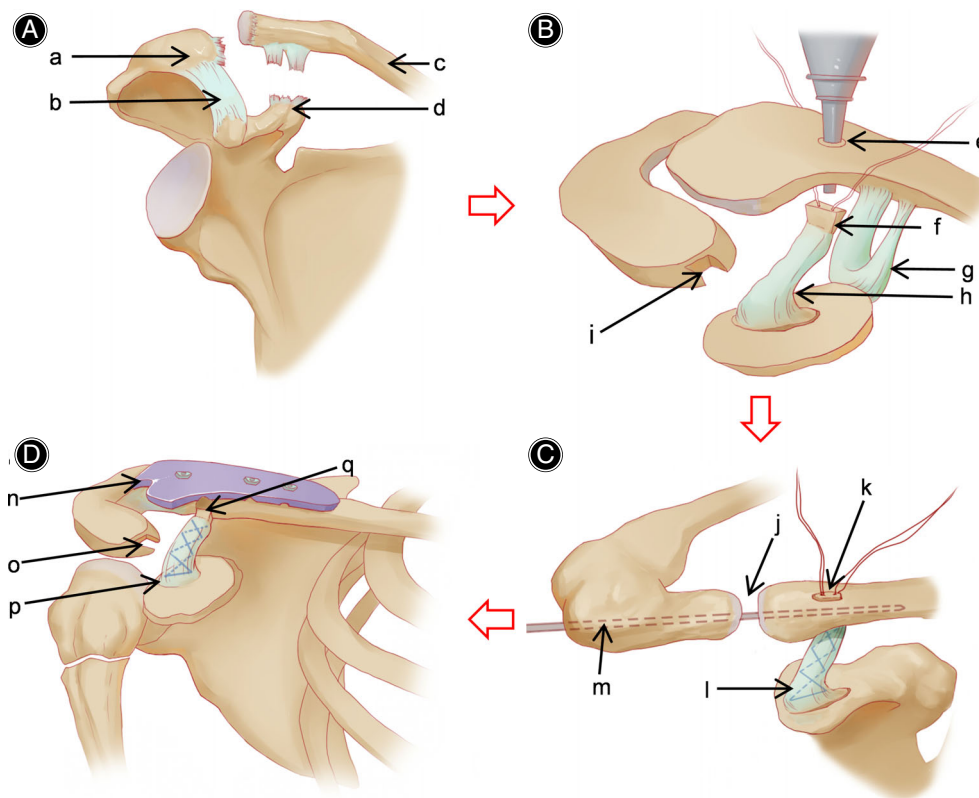
#### *Imaging Examinations*

The time that the recovery of shoulder joint function takes for each patient was calculated, and based on the X-ray



**Fig. 2** X-ray images of conical nodules of the clavicle demonstrating the position of reconstructed ligament before (left) and after (right) drilling the hole.





**Fig. 3** Surgical diagrams and procedures: (A) AC joint dislocation and coracoclavicular ligament rupture: (a) Acromion; (b) Coracoacromial ligament; (c) Clavicle; (d) Coracoclavicular ligament (broken). (B) Bone flap establishment, suture, and transposition of coracoacromial ligament. (e) hole in clavicle; (f) transposed bone flap of coracoacromial ligament; (g) broken coracoclavicular ligament; (h) transposed coracoacromial ligament; (i) the position where bone flap was obtained in the acromion of scapula. (C) Acromioclavicular joint reduction, coracoacromial ligament bone flap transfer, and simultaneous temporary fixation with K-wire. (j) acromioclavicular joint; (k) transposed coracoacromial ligament together with bone flap planted in the hole drilled in clavicle; (l) transposed coracoacromial ligament; (m) temporarily fixed K-wire; (D) Acromioclavicular joint restoration, coracoacromial ligament transposition, and hook plate fixation; (n) clavicle hook plate; (o) the position where bone flap was obtained in the acromion of scapula; (p) transposed coracoacromial ligament; (q) transposed coracoacromial ligament together with bone flap planted in the hole drilled in clavicle.

images, the distance between the upper plane of coracoid and the lower plane of clavicle (also called coracoid clavicle distance, CC-Dist) was also calculated.

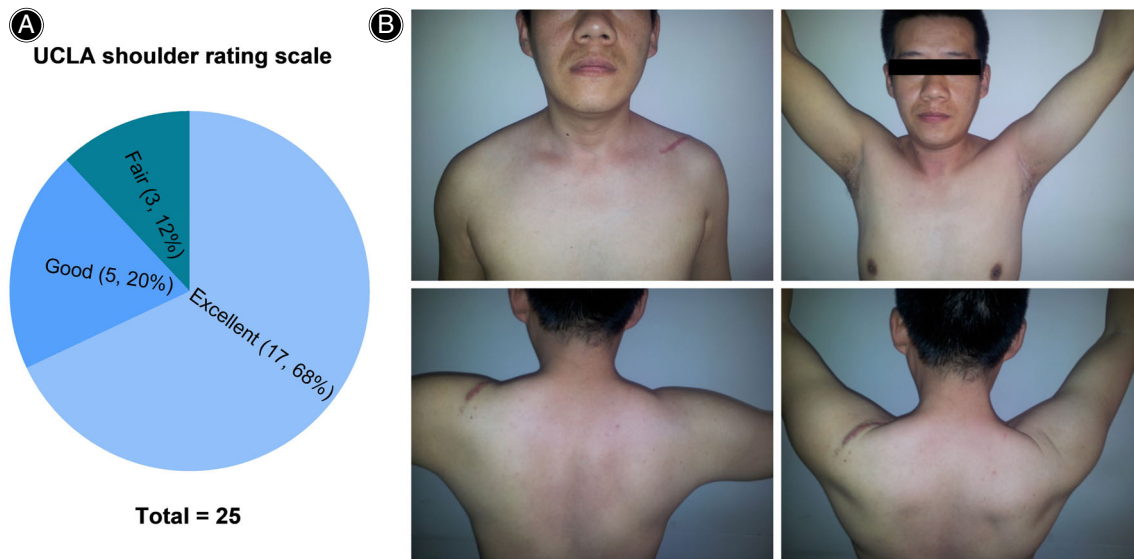
#### University of California (UCLA) Shoulder Rating

Apart from clinical examinations and imaging examinations, patients were also evaluated according to the UCLA shoulder rating scale proposed by Ellman *et al.*<sup>10</sup>. There are five sections in the UCLA shoulder rating scale, including pain, function, active forward flexion, strength of forward flexion, and satisfaction of patients. It has a total score of 35 points and can be divided into three levels: scores ranging from 34 to 35 points are in an excellent level, while scores between 29 and 33 points are in a good level, and the rest are fair or poor cases. To evaluate ligament reconstruction, MRI (SIEMENS) was performed on patients who were difficult to diagnose. Apart from the

UCLA shoulder rating scale, postoperative X-ray and stress radiography (SIEMENS) after removal of internal fixation in secondary surgery were also performed to evaluate the shoulder function of the patient.

#### Statistical Analysis

In this study, descriptive statistical analysis was mainly applied. The distribution of patients' age, post-surgery shoulder joint function score, and the CC-Dist value before and after surgery were analyzed using SPSS19.0 software (IBM SPSS, IBM Corp, Armonk, NY). Measurement data were expressed as mean  $\pm$  SD (standard deviation), and demonstrated in histograms to describe the numbers of patients in each group and their concentration and dispersion profile. Student *t*-test was used to analyze the difference between pre-surgery and post-surgery data, and  $P < 0.05$  was considered statistically significant.



**Fig. 4** Evaluation after surgery. (A) UCLA rating results after surgery for all cases. (B) The appearance and function of the patient's shoulder after hook plate was removed for 5 months.

## Results

### General Results

There were 18 males and seven females with an average age of  $43.5 \pm 2.4$  years (ranging from 28 to 51 years). According to the Rockwood classification, 17 (68%) patients were diagnosed with type III dislocation, five (20%) had type IV dislocation, and three (12%) had type V dislocation. The fall injuries were involved in 13 (52%) patients. Five (20%) patients were mauled by others and seven (28%) were drifting-down injuries.

### Intraoperative Results

In surgery, we found that the coracoacromial ligament had certain toughness and flexibility, and after successful ligament transposition, it would replace coracoclavicular ligaments under no tension to maintain the stability of

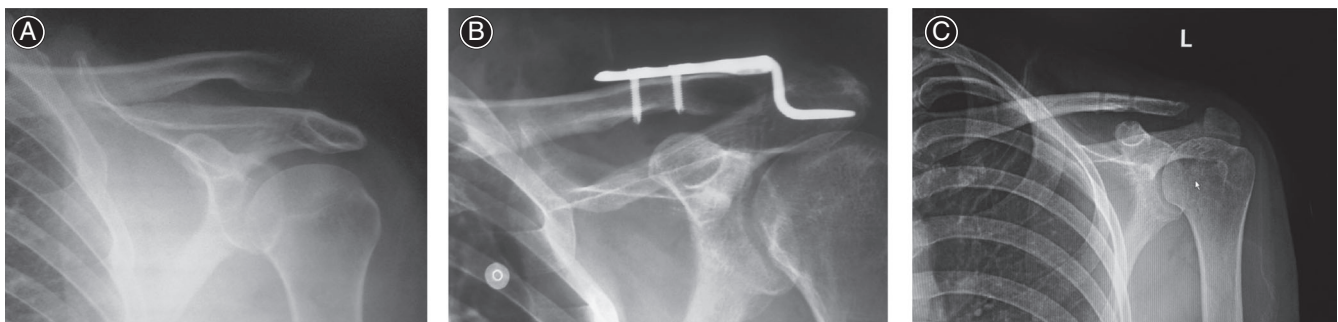
acromioclavicular joint. A difficulty we encountered in surgery was the precise localization of bone flap slicing and clavicle bone tunnel.

### Overall Postoperative Recovery Rate

All the cases were followed up for 12–24 months (18 months in average), in which time there were 17 excellent cases, five good cases, and three fair cases graded using UCLA system 6 months after the surgery. The excellent and good rate reached up to 88% (Fig. 4A).

### Recovery Time

For these patients, about  $12 \pm 2$  weeks were needed to regain the normal function of shoulder joint movement. Among them, two cases were of good status but felt mild pain which was aggravated by further exercise, and one case showed limited mobility and mild pain.



**Fig. 5** Imaging materials before and after surgery. (A) Preoperative acromioclavicular joint dislocation X-ray of a patient; (B) Postoperative acromioclavicular joint dislocation X-ray of a patient; (C) X-ray film of a patient after removal of plate in second operation.

**Recovery Status After Clavicular Hook Plate Removal**

Six to 12 months after the surgery, a second operation was performed to remove clavicular hook plate, after which time most of the excellent and good cases showed almost normal joint function, compared with their contralateral joint (Fig. 4B). No shoulder joint deformity was found in the patients and no re-dislocation was observed in both X-ray and stress X-ray (Fig. 5).

**Coracoid Clavicle Distance**

Regular ultrasound examination was performed at 3 and 6 months, respectively, after surgery, and the results showed the transposition of the coracoacromial ligament between coracoid and distal clavicle, good continuity, and homogeneous echogenicity. The results of postoperative X-ray showed that, 1 year after the surgery, the distance between the upper plane of coracoid and the lower plane of clavicle (also called coracoid clavicle distance, CC-Dist) significantly decreased to  $9.7 \pm 0.7$  mm from  $15.8 \pm 1.6$  mm before the surgery.

**Complications**

Three months after surgery, some of the patients had mild acromioclavicular joint discomfort and partially limited abduction of shoulder joint or upper body, and obtained remarkable remission after they were treated with non-steroidal anti-inflammatory drugs for 2–4 weeks and underwent professional rehabilitation training simultaneously. Ability of life and work of all the patients we followed up recovered as before.

**Discussion****Therapeutic Principle for Different Types of AC Joint Dislocation**

For type I and type II acute AC joint dislocation, treatment is usually conservative, whereas surgical treatment is recommended in type IV, V, and VI patients. This view is generally accepted by orthopaedists around the world<sup>11</sup>. Although doctors have failed to reach a consensus on the treatment of type III acute dislocation, younger patients who undertake energy-consuming jobs still prefer to do operations after being diagnosed with type III dislocation due to the improvement of the surgical method and the development of minimally invasive techniques<sup>12</sup>. Supported by some researchers, our suggestion is that the treatment can start with an initial nonoperative management for 2 or 3 weeks<sup>13</sup>. If short-term conservative treatment fails with persistent pain, surgical treatment should be chosen.

The purpose of surgical treatment of AC joint dislocation is to stabilize the position of distal clavicle, restore the AC joint anatomy and function<sup>14</sup>. At present, there are two main types of surgical treatment for such injuries. The first one is to achieve AC joint reduction by internal fixation<sup>15</sup>. The second type is to reconstruct the AC joint by using

ligament grafts and then restore the function of the joint after tendon-bone healing<sup>16</sup>.

**The Clavicular Hook Plate Fixation and Ligament Reconstruction in the Treatment of AC Joint Dislocation**

The clavicular hook plate is designed on the grounds of the topographic anatomic structure of the AC joint, to indirectly fix the joint. This clavicle-shaped plate can contribute to early postoperative exercises and functional recovery<sup>17</sup>. Compared with the traditional Kirschner wire tension band fixation, it is more in line with the normal physiological structure of the AC joint, with the advantages of simple surgical procedures, strong stability, and allowing early functional exercise. The follow-up cases also showed a high recovery rate, and it was therefore approved by most of the surgeons. We performed the same plate fixation to maintain the stability of the AC joint in 25 patients<sup>7</sup>.

Currently, there is a heated debate on whether coracoclavicular ligament reconstruction is necessary for clavicular hook plate fixation<sup>18</sup>. If the ligaments around the AC joint are not repaired, redislocation of the joint may occur after removal of the internal fixation. Complete AC joint dislocation is accompanied by the rupture of the coracoclavicular ligaments. Thus, the author believes that the coracoclavicular ligaments should be reconstructed simultaneously during the fixation. In 1972, Weaver and Dunn<sup>19</sup> first reported the coracoclavicular ligament reconstruction. The AC joint dislocation was treated by resecting the distal 2 cm of distal clavicle and detaching the acromial end of the coracoacromial ligament while attaching the remaining ligament to the remaining clavicle with sutures. Modern variations of Weaver–Dunn procedures include using coracoclavicular screw, drilling holes in the clavicle, and wrapping ligation material around coracoid to stabilize the joint. Millett *et al.*<sup>20</sup> transferred the coracoacromial ligament to the clavicle, while using the absorbable sutures to protect the reconstructed structure. All the procedures discussed above achieved good results.

We believe that the rupture of the coracoclavicular ligaments need to be repaired in accordance with the principle of ligament repair, of which the most important thing is a tension-free healing after reconstruction. The traditional Weaver–Dunn surgery<sup>21</sup> is a method of reconstructing the coracoclavicular ligaments by transposition of coracoacromial ligament without use of internal fixation which conforms to the normal anatomical structure of the AC joint. However, it changes the position of coracoacromial ligament which reduces the function of coracoacromial arch. Additionally, coracoacromial ligament, which is relatively thinner than other ligaments, has a poor postoperative stability and biomechanical strength. The modified Weaver–Dunn procedure requires higher surgical skills and longer operation time. Other surgical technique for acute acromioclavicular dislocations is also used nowadays, such as arthroscopic coracoclavicular and acromioclavicular ligament reconstruction. It is characterized with accurate positioning on the coracoid base, less trauma, quick recovery, good biological properties,



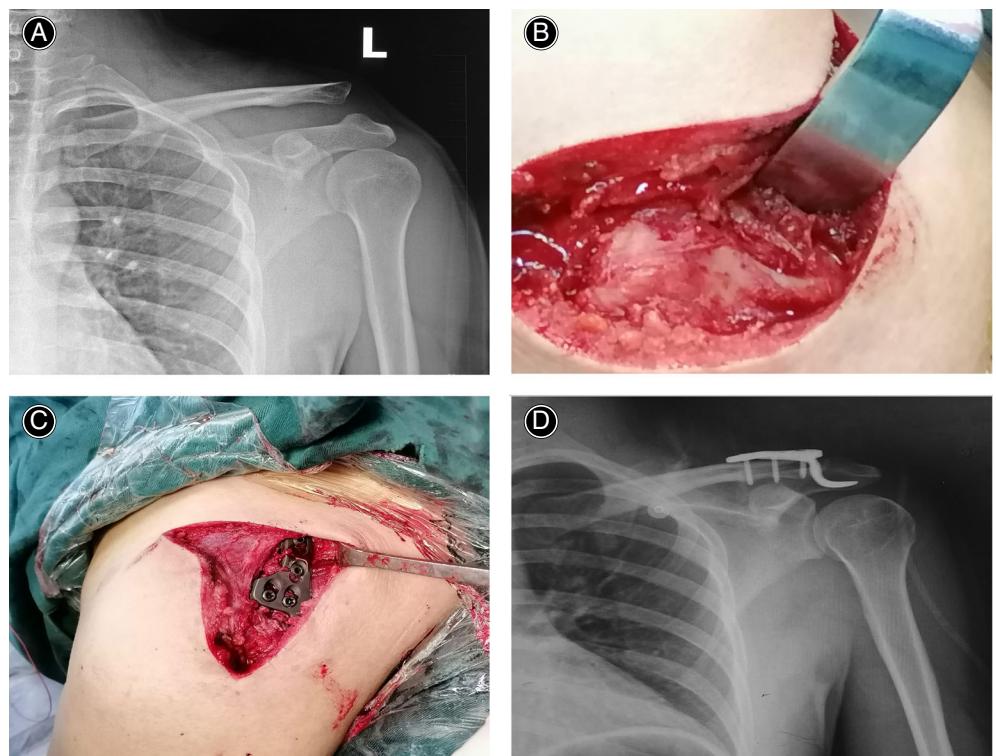
no immune rejection, and obviously less shoulder pain. What's more, it is not necessary to reperform the surgery to remove the internal fixation. For young adults, it is an ideal treatment. However, the expense is relatively high, and the stress that the clavicle can bear is reduced by clavicle bone tunnel, leading to the risk of clavicle fracture. Besides, the requirement for clavicle bone tunnel is strict. If the position of the tunnel is inappropriate (forward or backward), the application of interference screw may cause the collapse of the tunnel, resulting in the failure of fixation. Also, reconstruction failure can be caused by the possibility of incomplete healing of the tendon-bone<sup>22</sup>. In our study, we use the combination of the clavicular hook plates and modified Weaver–Dunn procedure<sup>23</sup>. By drilling holes in the clavicle and locking stitch suturing of coracoacromial ligament with bone flap, ligament transposition and clavicle bony healing were achieved, which increased the stability of the ligament. Our method is able to effectively conquer the above-mentioned challenges, including clavicle fracture, rejection, tendon wear, and rupture caused by allogeneic tendon reconstruction, and therefore reduce the surgical cost in the end. In addition, we successfully avoided the redislocation after plate removing.

In this study, our results suggested a good anatomical alignment of the acromioclavicular joint without any secondary dislocation, indicating the successful reconstruction of the acromioclavicular ligament. To better display the procedure and efficacy of the surgery, the X-ray imaging before and after surgery and the surgery process

of another case (male, aged 26, fall injury) was additionally shown in Fig. 6.

#### **Best Time to Remove the Plate After Surgery**

Whether internal fixation should be removed after surgery is still in dispute. Kashii *et al.*<sup>24</sup> believe that due to the fact the plate hook is put under acromion, there may be abrasions at the posterior and tendon junctions of the supraspinatus muscle. Therefore, the plate needs to be removed after the surgery within 3 to 4 months in order to prevent acromion from being worn out. Some researchers<sup>25</sup> who followed up the patients with severe AC joint dislocation after clavicular hook plate fixation found plate displacement, acromial fractures, and rotator cuff injury. The joint parts of the hooks and acromion have been scuffed up, which indicates that the clavicular hook plate has inhibited the movement of the shoulder joint. Furthermore, a biomechanical study has shown that semitendinosus anatomic reconstruction has greater tensile strength than coracoclavicular ligament, up to  $948 \pm 148$  N, and the tensile strength of coracoacromial ligament reconstruction equals that of coracoclavicular ligament, which fully meet the biomechanical needs of immediate functional rehabilitation exercise after surgery<sup>26</sup>. Taken together, removing the plate has positive effects for improving the function of the shoulder joint, therefore it is recommended by many clinicians that the internal fixation should be removed early, which will result in lower occurrence rate of re-dislocation<sup>27</sup>.



**Fig. 6** A male case (aged 26) with fall injury underwent the surgery. (A) X-ray imaging before surgery; (B, C) Coracoclavicular ligament reconstruction and fixation in surgery; (D) X-ray imaging after surgery.

### Limitations of the Study

In our present study, we showed some promising evidence that our method works in the treatment of Rockwood III–V dislocation of AC joint. There are also some limitations in the study—small sample size, short follow-up time, and no control group—which leaves us with more progress to make. Meanwhile, randomized controlled trials or even further multi-centric clinical studies are required to prove the surgical feasibility as well as the reliability of the theory being bio-mechanically tested.

### Conclusions and Suggestions for the Treatment of AC Joint Dislocation

To summarize the clinical experience of the treatment of these patients, we concluded that patients suffering from AC joint dislocation in Rockwood III–V type can be treated properly by the combination of clavicular hook plate and the coracoacromial ligament transposition. In order to avoid the occurrence of osteoarthritis of the AC joint and the chronic injury of the supraspinatus tendon, we support that the internal fixation should be removed after surgery. However, removal of the internal fixations should be completed after bone healing due to the use of bone flaps, otherwise it will result in failure of the ligament restoration. Considering the

time taken for bone healing, we suggest that the clavicular hook plate can be removed 4 to 5 months or no later than 6 months after the surgery. The bone flap at that time has already achieved bony union in the bone cavity. Removing the plate was beneficial to the recovery of the coracoclavicular ligament tension after transposition, and further increased ligament elasticity and strength.

In summary, despite the aforementioned limitations, the combination of AO clavicular hook plate with coracoacromial ligament transposition can be at least alternatively used for treating Rockwood III–V dislocation of acromioclavicular joint. This surgical technique, characterized by stable fixation, less complications, and satisfactory treatment effect, has the potential of great clinical value. Still, this improved procedure needs continuous and in-depth research in clinical practices, which will help us to draw more comprehensive and systematic conclusions.

### Acknowledgments

This research was supported by grants from Xinjiang Tianshan Innovative Team Plan (Grant No. 2017D14015) and National Key Research and Development Plan (Grant No. 2017YFB1304205).

### References

- Kim AC, Matcuk G, Patel D, et al. Acromioclavicular joint injuries and reconstructions: a review of expected imaging findings and potential complications. *Emerg Radiol*, 2012, 19: 399–413.
- Tossy JD, Mead NC, SIGMoND HM. Acromioclavicular separations: useful and practical classification for treatment. *Clin Orthop Relat Res*, 1963, 28: 111–119.
- Stucken C, Cohen SB. Management of acromioclavicular joint injuries. *Orthop Clin North Am*, 2015, 46: 57–66.
- Johansen JA, Grutter PW, McFarland EG, Petersen SA. Acromioclavicular joint injuries: indications for treatment and treatment options. *J Shoulder & Elbow Surg*, 2011, 20: 70–82.
- Salzmann GM, Walz L, Buchmann S, Glabgyl P, Venjakob A, Imhoff AB. Arthroscopically assisted 2-bundle anatomical reduction of acute acromioclavicular joint separations. *Am J Sports Med*, 2010, 41: 1179–1187.
- Dou Q, Ren X. Clinical therapeutic effects of AO/ASIF clavicle hook plate on distal clavicle fractures and acromioclavicular joint dislocations. *Pak J Med Sci*, 2014, 30: 868–871.
- Kim YG, Lee HJ, Kim DW, Dan J. A comparison of results between AO hook plate and TightRope for acute acromioclavicular joint dislocation. *J Korean Fract Soc*, 2017, 30: 16–23.
- Scheibel M, Dröschel S, Gerhardt C, Kraus N. Arthroscopically assisted stabilization of acute high-grade acromioclavicular joint separations. *Am J Sports Med*, 2011, 39: 1507–1516.
- Wang ZZ, Tuoheti Y, Xu C, et al. Conjoined tendon and coracoacromial ligament transfer in the treatment of RockwoodIII acromioclavicular joint dislocation: anatomical and clinical validation. *Chin J Tissue Eng Res*, 2015, 164: 283–293.
- Ellman H, Hanker G, Bayer M. Repair of the rotator cuff. End-result study of factors influencing reconstruction. *J Bone Joint Surg Am*, 1986, 68: 1136–1144.
- Larsen E, Bjerg-Nielsen A, Christensen P. Conservative or surgical treatment of acromioclavicular dislocation. A prospective, controlled, randomized study. *J Bone Joint Surg Am*, 1986, 68: 205–216.
- Giuseppe LU, Ciuffreda M, Rizzello G, Mannering N, Maffulli N, Denaro V. Surgical versus conservative management of type III acromioclavicular dislocation: a systematic review. *Br Med Bull*, 2017, 122: 31–49.
- Imhoff AB, Feucht MJ, Aboalata M. *Surgical Atlas of Sports Orthopaedics and Sports Traumatology*. Surgical Atlas of Sports. Berlin, Germany: Springer; 2015.
- Heikenfeld R, Listringhaus R, Godolias G. Arthroscopic treatment of acute traumatic AC joint dislocation (SS-41). *Arthroscopy J Arthroscopic & Relat Surg*, 2010, 23: e21-e.
- Jiang D, Meng N, Liu X, Xiong J, Lu J. Treatment of severe acromioclavicular joint dislocation with internal fixation of tension band wiring. *J Clin Orthop*, 2001, 4: 299–300.
- Mckee MD. Operative fixation of chronic acromioclavicular joint dislocation with hook plate and modified ligament transfer. *J Orthop Trauma*, 2016, 30: S7–S8.
- Li J, Chen X, Kang H, Li H. The outcome of clavicular hook plate fixation for acromioclavicular dislocation associated with coracoid process fracture. *Asia-Pac J Sports Med*, 2017, 9: 120.
- Rollo J, Raghunath J, Porter K. Injuries of the acromioclavicular joint and current treatment options. *Dent Traumatol*, 2005, 7: 217–223.
- Weaver JK, Dunn HK, Weaver JK, Dunn HK. Treatment of acromioclavicular injuries, especially complete acromioclavicular separation. *J Bone Joint Surg Am*, 1972, 54: 1187–1194.
- Millett PJ, Sepp B, Reuben G, Pacheco IH. Acromioclavicular joint reconstruction with coracoacromial ligament transfer using the docking technique. *BMC Musculoskelet Disord*, 2009, 10: 1–8.
- Bradley JP, Elkousy H. Decision making: operative versus nonoperative treatment of acromioclavicular joint injuries. *Clin Sports Med*, 2003, 22: 277–290.
- Jones HP, Lemos MJ, Schepsis AA. Salvage of failed acromioclavicular joint reconstruction using autogenous semitendinosus tendon from the knee: surgical technique and case report. *Am J Sports Med*, 2001, 29: 234–237.
- Payvandi S, Jeong J, Seitz WH Jr. Treatment of complete acromioclavicular separations with a modified weaver and dunn technique. *Tech Hand Up Extrem Surg*, 2008, 12: 59–64.
- Kashii M, Inui H, Yamamoto K. Surgical treatment of distal clavicle fractures using the clavicular hook plate. *Clin Orthop Relat Res*, 2006, 447: 158–164.
- Muramatsu K, Shigetomi M, Matsunaga T, Murata Y, Taguchi T. Use of the AO hook-plate for treatment of unstable fractures of the distal clavicle. *Arch Orthop Trauma Surg*, 2007, 127: 191–194.
- Thomas K, Litsky A, Jones G, Bishop JY. Biomechanical comparison of coracoclavicular reconstructive techniques. *Am J Sports Med*, 2011, 39: 804–810.
- Rolf O, von Weyhern AH, Ewers A, Boehm TD, Gohlke F. Acromioclavicular dislocation Rockwood III–V: results of early versus delayed surgical treatment. *Arch Orthop Trauma Surg*, 2008, 128: 1153–1157.