



Segmental Arterial Mediolytic: A Case Study and Review of the Literature in Accurate Diagnosis and Management

Rebekah Tan

Department of Vascular Surgery, Sir Charles Gairdner Hospital, Nedlands, Australia

Segmental arterial mediolysis (SAM) is a rare noninflammatory, nonarteriosclerotic arteriopathy of an unknown etiology. It most commonly affects the medium-sized vessels of the abdomen and is characterized by the disruption of the arterial medial layer. Although histological confirmation remains the gold standard in diagnosis, the use of computed tomography angiography (CTA) has greatly aided the diagnosis and surveillance of SAM. Given its rarity and angiographic similarities to other vasculopathies, the diagnosis of SAM can be challenging and is often missed. We describe the case of a 46-year-old male patient who presented to our institution with abdominal pain and multiple foci of intra-abdominal arterial dissections on CTA. We report the acute management via endovascular intervention and review the literature with respect to the diagnosis and management of this rare condition. SAM remains an uncommon yet significant disease process requiring prompt and accurate diagnosis. Initiation of immediate treatment is crucial, given the knowledge gap about its natural progression.

Key Words: Segmental arterial mediolysis, Endovascular, Dissection

Received June 18, 2019

Revised July 29, 2019

Accepted July 31, 2019

Corresponding author: Rebekah Tan

Department of Vascular Surgery, Sir Charles Gairdner Hospital, Hospital Avenue, Nedlands, Perth 6009, Western Australia, Australia

Tel: 61-416009979

Fax: 61-864573333

E-mail: Rebekah_2104@hotmail.com

<https://orcid.org/0000-0002-3664-7581>

Copyright © 2019, The Korean Society for Vascular Surgery

This is an Open Access article distributed under the terms of the Creative Commons Attribution Non-Commercial License (<http://creativecommons.org/licenses/by-nc/4.0>) which permits unrestricted non-commercial use, distribution, and reproduction in any medium, provided the original work is properly cited.

Vasc Specialist Int 2019;35(3):174-179 • <https://doi.org/10.5758/vsi.2019.35.3.174>

INTRODUCTION

Segmental arterial mediolysis (SAM) was first described as a distinct entity by Slavin and Gonzalez-Vitale in 1976 [1,2]. Originally named segmental mediolytic arteritis, the disease was renamed when it was observed that the pathological process was different from that of arteritis [1,2]. A similar pathological process was described by Gruenwald in 1949, in neonatal epicardial coronary arteries, which is accepted as the first description of SAM in the literature [3]. It is an idiopathic, nonarteriosclerotic, noninflammatory vascular disease of an unknown origin involving the visceral arteries of the abdomen, with rare involvement of the renal, iliac, intracranial, pulmonary, and coronary arteries. Predominantly affecting the outer layer of the media, smooth muscle cell vacuolar degeneration occurs, resulting in me-

dial disruption, intramural hemorrhage, and per-adventitial deposition. Gaps may then develop into saccular aneurysms or thrombosis as a result of fibrin, thrombus, or granulation tissue formation [4]. It is characterized by dissections, aneurysms, or stenosis that are found incidentally on imaging or in acute presentations in cases with end-organ ischemia or life-threatening hemorrhage [5]. Histological confirmation is the gold standard for diagnosis; however, is not always available.

CASE

A 46-year-old male patient with well-controlled hypertension, but who is otherwise fit and healthy, presented to our emergency department with sudden-onset epigastric pain. The pain started after completing a weight exercise at

the gym, radiated across the abdomen, and progressively worsened. Physical examination revealed a blood pressure of 140/84 mmHg, with otherwise normal vital signs. Abdominal examination revealed epigastric tenderness without any palpable masses, guarding, or peritonism. All laboratory tests were normal including full blood count, urea and electrolytes, C-reactive protein, lipase, liver function, and vasculitis screening. A bedside ultrasound in the emergency department showed irregularities of the superior mesenteric artery (SMA). Computed tomography angiography (CTA)

showed an acute dissection of the celiac trunk commencing 15 mm from its origin (Fig. 1), extending into the origin of the common hepatic and splenic arteries, and a long segment dissection involving the SMA commencing at the origin to the level of L2, with a thrombosed false lumen (Fig. 2). Conservative management was initiated, with aggressive blood pressure control aiming for a systolic blood pressure of 100 to 120 mmHg. Further, heparin infusion was commenced in the intensive care unit where continuous blood pressure monitoring was carried out.

SAM was diagnosed on the basis of the patient's history, clinical examination, CTA findings, and ruling out of other causes. Immunological laboratory tests were performed to exclude autoimmune or inflammatory causes of vasculopathy. Further investigations of hypertension, including renal tract ultrasound, urine catecholamine test, and renin-aldosterone ratio determination, yielded normal findings.

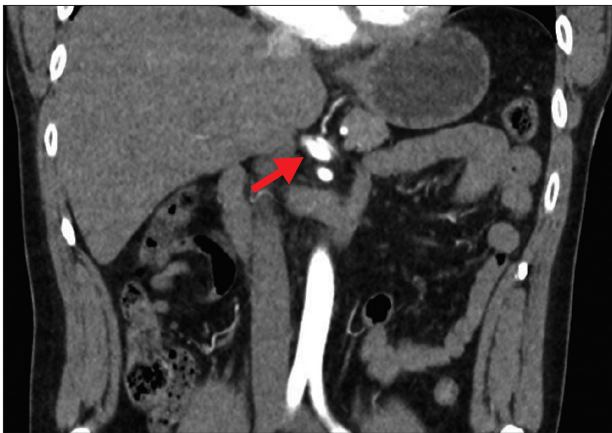


Fig. 1. Presentation to the emergency department: abdominal computed tomography scan showing dissection of the celiac trunk, commencing 15 mm from its origin. Coronal section showing coeliac trunk dissection (arrow).

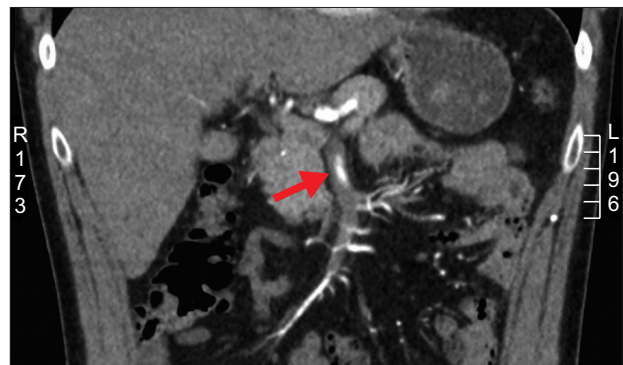


Fig. 3. Day 11 of admission: dissection of the superior mesenteric artery (SMA), with no opacification of false lumen, and with associated high-grade occlusion of the SMA at 4 cm from its origin (arrow).

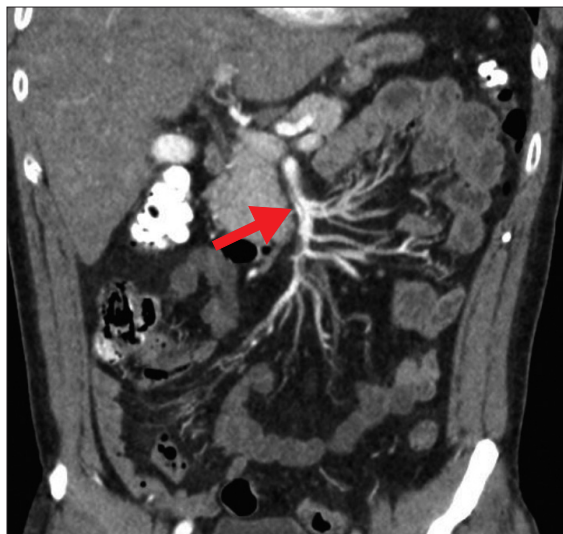


Fig. 2. Presentation to the emergency department: abdominal computed tomography scan showing dissection of the superior mesenteric artery commencing just beyond the origin to the level of L2/L3, with opacification of false lumen (arrow).

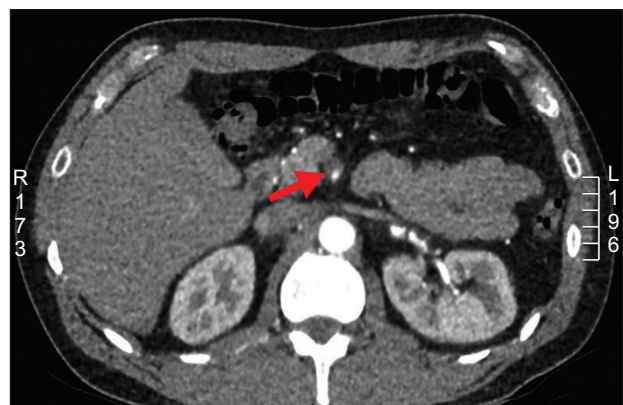

Fig. 4. Axial view: dissection of the superior mesenteric artery (SMA), with no opacification of false lumen, and with associated high-grade occlusion of the SMA at 4 cm from its origin (arrow).

Serial CTA scans were performed to monitor the progression of arterial dissection owing to ongoing abdominal pain. On day 11 of admission, the patient experienced gradually worsening abdominal pain, one episode of diarrhea after a meal, and elevated lactate levels. Because of the suspicion of an ischemic event, CTA was performed, which showed new thrombosis of the false lumen within the SMA, with underfilling of the SMA distally (Fig. 3, 4). The patient underwent angiography and endovascular stenting of the aneurysmal section of the SMA with a 6×40 mm Tigris® stent (Gore-Tex, Newark, DE, USA) distally and a 7×80 mm Tigris® stent extended proximally. A completion angiogram showed much improved filling of the SMA and distal branches. The patient underwent surveillance CTA at 6 weeks from presentation, which showed stable disease, patent SMA stent, and filling of the distal branches (Fig. 5-7).

DISCUSSION

SAM was first described in 1976 by Slavin and Gonzalez-Vitale in elderly patients [1]. Although increasingly diagnosed, it remains a rare vasculopathy characterized by non-inflammatory degeneration of the medial layer of muscular arteries and, occasionally, the adjacent veins. This lesion is postulated to develop as a result of cytoplasmic vacuolar degeneration of arteriolar smooth muscle cells. Integration of these vacuoles then leads to disruption of the media, intramural hemorrhage, fibrin deposition at the adventio-medial junction, and formation of granulation tissue [6]. The most commonly affected vessels are the visceral arteries, followed by the renal, intracranial, abdominal muscular, internal carotid, iliac, pulmonary, and vertebral arteries, and

multivessel involvement is not unusual.

1) Presentation

The severity of presentations range from abdominal discomfort (the most common) to hematochezia, stroke, hemoptysis, headache, back pain, or even more catastrophic presentations such as hemorrhage in the abdomen, retroperitoneum, or brain due to aneurysmal rupture or dissection [7].

2) Diagnosis

Although the diagnosis is usually made on the basis of the patient's history, clinical examination, and radiological

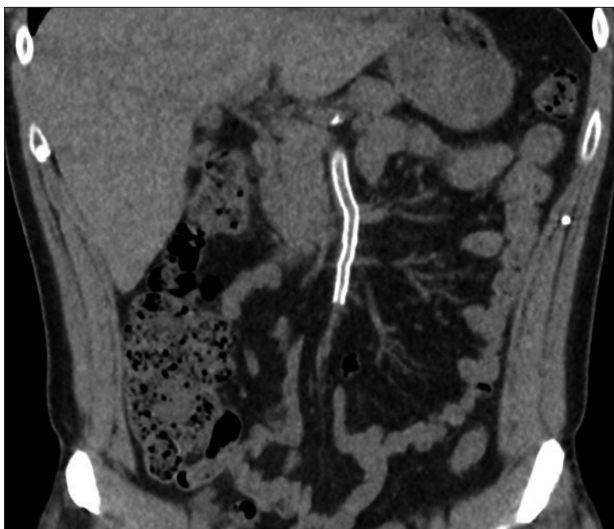


Fig. 5. At 1 month after stent insertion: stent placement in the superior mesenteric artery.

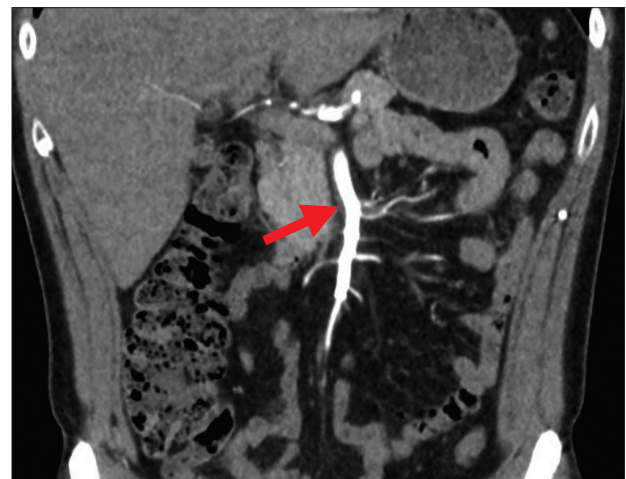

Fig. 6. At 1 month after stent insertion: patent superior mesenteric artery (SMA) stent with adequate perfusion of the major branches arising from the SMA. There is also adequate perfusion of the abdominal organs and bowel, with no evidence of ischemia (arrow).

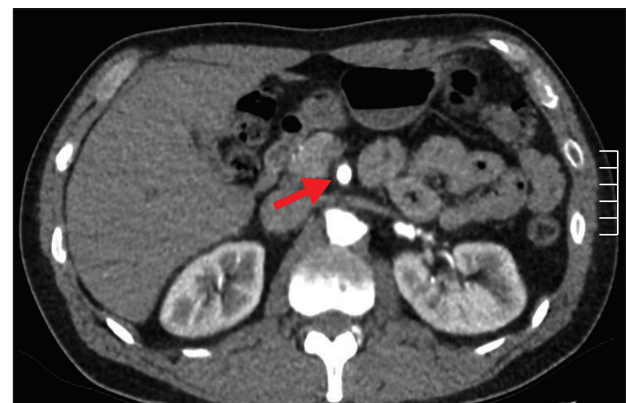


Fig. 7. At 1 month after stent insertion: patent superior mesenteric artery stent (arrow).

features, histology is the gold standard in diagnosing SAM. Histologically, a diagnosis can be accurately made according to the presence of fibrin and collagen deposits and destruction of smooth muscle cytoplasm of the media in the acute phase, and resolution of the acute features with considerable vessel remodeling in the late phase [1]. Another key histological finding is the absence of inflammatory cells. Histological diagnosis, however, is only available in patients who require surgery for the resection of vessels damaged by SAM or in post-mortem cases.

CTA can accurately reveal patterns consistent with SAM. The hallmark of angiographic diagnosis is lysis of the medial layer of the arterial wall, resulting in stenosis, occlusion, aneurysmal formation, arterial dilatation, and dissection [1,2,7]. The large abdominal aortic branches, considered to be medium-sized vessels, are the most commonly affected sites in SAM. Numerous lesions are often identified, affecting arteries in a segmental, skip pattern, with the diseased segments demonstrating involvement of the circumference or only a portion of the arterial wall [1,2]. Arterial dissections account for the majority of the reported cases of SAM, followed by pseudoaneurysms. When dissection of peripheral arteries unrelated to the aorta is observed, a diagnosis of SAM should be considered [5,7,8].

Naidu et al. [8] and Michael et al. [9] have shown that CTA provides the spatial resolution and vessel detail required for the acute diagnosis of SAM. Serial CTA is found to be superior to conventional angiography, as it able to evaluate perivascular inflammation, vessel wall thickening, and rapidly evolving lesions [9]. The incidence and prevalence of SAM is not known and very likely underestimated, as the patients may be asymptomatic or CTA is not routinely carried out for the investigation of abdominal pain. Although magnetic resonance imaging, with its lack of ionizing radiation, may seem a preferable option, it lacks the spatial resolution and detail associated with CTA [9].

3) Differential diagnoses

SAM can mimic other distinct disease processes, and discrimination of SAM is pertinent because the management options are vastly different. In the presence of suspicion of ischemia downstream of the affected vessel, atherosclerosis may be considered the main culprit. Nonetheless, the distribution of disease is very different between SAM and atherosclerosis. While atherosclerosis typically occurs at branch points of vessels and throughout multiple regions of the vascular tree, SAM is usually confined to vessels of one anatomic site [10]. Furthermore, atherosclerosis occurs in middle-aged persons with coexisting cardiovascular risk factors, whereas SAM may present at any age and in other-

wise fit and healthy individuals [11].

Systemic inflammatory vasculitides (e.g., Takayasu's arteritis, Bechet's disease, polyarteritis nodosa, Henoch-Schonlein purpura, and Wegener's granulomatosis) often have imaging findings that overlap with those of SAM [12]. Nonetheless, these vasculitides, which are treated with corticosteroids and immunosuppressive agents, should be excluded early by correlating clinical and laboratory test findings. Not only do corticosteroids and immunosuppressive agents, used to treat vasculitides, not add any benefit in the management of SAM, but they may also expose the patient to undesired risks such as infection, poor wound healing, and potentially worsened prognosis [13].

Another differential diagnosis, with similar angiographic findings to SAM, is fibromuscular dysplasia (FMD) [2,10]. The presence of beading or webs on imaging are seen in both conditions and distinguishing between diagnoses can be challenging [2,14]. Although a definite diagnosis can be made on the basis of histology, this is often not possible as few patients require surgical revascularization or organ resection. Clinically, FMD usually occurs in women in their second to third decade of life and has a predisposition to affect the carotid and renal arteries, causing premature hypertension [14]. SAM, in contrast to FMD, does not favor a certain age group nor sex, shows a predilection for the celiac artery and its branches, and more commonly progresses to arterial dissection and hemorrhage [2,15].

In patients with angiographic evidence of either multiple visceral aneurysms or an aneurysm at an arterial bifurcation, a mycotic aneurysm should be considered. This arises after infectious destruction of the arterial wall and is often associated with systemic infection. Aneurysms of SAM origin more typically have no preferential involvement of a bifurcating site [9].

Other differential diagnoses that are excluded are degenerative and connective tissue vasculopathies such cystic medial necrosis and cystic adventitial artery disease. While cystic medial necrosis more typically occurs in the aorta and great vessels of patients with Marfan's syndrome, cystic adventitial artery disease usually manifests in the extremity arteries of younger adult male patients [6]. On histology, mucopolysaccharides are found in both entities, but not in SAM [1,6].

4) Treatment

Owing to its relative rarity, the misdiagnosis of angiographic and clinical findings has led to incorrect diagnosis and hence incorrect treatment. The mortality rate is as high as 50% in patients who present with a life-threatening hemorrhage, and is much lower with early detection and

rapid commencement of therapy [15,16]. With advances in diagnostic and therapeutic techniques, early diagnosis and detection of disease progression have reduced the mortality rate to 25%. No formal guidelines for the management of SAM exist yet. In all reported cases, the management has been tailored to the specific clinical presentation. Urgent resuscitation and exploratory laparotomy are indicated in patients with life-threatening hemorrhage, and may often lead to the resection of the diseased vessel and associated ischemic end organ. Aneurysms and dissection should be monitored, and with progression of the lesion, thus increasing the risk of organ ischemia, endovascular treatment is the foremost therapeutic option with a relatively low morbidity rate [2,15,16].

As the natural course of the disease remains unpredictable, strict blood pressure control and close monitoring with periodic CTA are recommended [17]. In some reported cases, smaller aneurysms decreased in size and eventually resolved [9]. If ongoing surveillance via periodic CTA shows persistent or progressive vascular abnormalities, either a shorter interval between repeat imaging or definite treatment is required. In patients who have remained stable, it has been reported that conservative therapy with optimization of antihypertensive therapy, anticoagulation, and lifestyle modifications has been successful [18]. The elective surgical treatment of asymptomatic stable patients remains controversial. In a review of 111 patients by Naidu et al. [8], 20% (n=19) of patients had disease progression at a median of 14 months, 6 of whom had abdominal or flank pain and 13 were asymptomatic. Among the remaining 78 patients, 42 had stable disease, 26 had disease resolution, and 18 had a mix of stable disease and disease resolution on repeat imaging. A similar entity to SAM is spontaneous isolated dissection of the SMA (SIDSMA) [19,20]. SIDSMA may present similarly and is diagnosed on CTA with arterial dissection confined to the SMA. Given the rarity of this condition, there is no consensus on the optimal treatment strategy. Nonetheless, several case series have reported complete resolution of SMA dissection in as high as 90% of cases

that were conservatively managed [19,20]. Endovascular or surgical treatment was indicated for cases that progressed to persistent or progressive abdominal pain, bowel infarction, or arterial rupture [19,20].

The patient we reported above was initially managed conservatively with strict blood pressure control; however, definitive endovascular therapy was needed owing to progression of an SMA dissection with angiographic evidence of reduced flow distally. Furthermore, the patient's symptom of progressively worsening abdominal pain and associated increase in lactate levels established a diagnosis of bowel ischemia, warranting prompt intervention.

Given the lack of consensus guidelines for the diagnosis and management of SAM, larger multicenter observation registries are needed to provide better insight into the clinical and imaging characteristics as well as natural progression of SAM.

In conclusion, SAM is a diagnosis that should not be neglected in patients presenting with sudden-onset abdominal pain and abnormal angiographic findings. In cases in which other differential diagnoses have been excluded and a definite diagnosis has been made, early aggressive blood pressure management or definitive treatment, where indicated, is important in reducing the risk of mortality. Although the mainstay of treatment has generally been surgical intervention, the less invasive endovascular treatment is demonstrating an emerging role and is proving successful. In patients placed under disease surveillance, CTA scans at regular intervals are warranted to detect early disease progression.

CONFLICTS OF INTEREST

The author has nothing to disclose.

ORCID

Rebekah Tan

<https://orcid.org/0000-0002-3664-7581>

REFERENCES

- 1) Slavin RE, Gonzalez-Vitale JC. Segmental mediolytic arteritis: a clinical pathologic study. *Lab Invest* 1976;35:23-29.
- 2) Slavin RE, Saeki K, Bhagavan B, Maas AE. Segmental arterial mediolysis: a precursor to fibromuscular dysplasia? *Mod Pathol* 1995;8:287-294.
- 3) Gruenwald P. Necrosis in the coronary arteries of newborn infants. *Am Heart J* 1949;38:889-897.
- 4) Inayama Y, Kitamura H, Kitamura H, Tobe M, Kanisawa M. Segmental mediolytic arteritis. *clinicopathologic study and three-dimensional analysis. Acta Pathol Jpn* 1992;42:201-209.
- 5) Sakano T, Morita K, Imaki M, Ueno H. Segmental arterial mediolysis studied by repeated angiography. *Br J Radiol* 1997;70:656-658.
- 6) Heritz DM, Butany J, Johnston KW,

- Sniderman KW. Intraabdominal hemorrhage as a result of segmental mediolytic arteritis of an omental artery: case report. *J Vasc Surg* 1990;12:561-565.
- 7) Inada K, Maeda M, Ikeda T. Segmental arterial mediolysis: unrecognized cases culled from cases of ruptured aneurysm of abdominal visceral arteries reported in the Japanese literature. *Pathol Res Pract* 2007;203:771-778.
- 8) Naidu SG, Menias CO, Oklu R, Hines RS, Alhalabi K, Makar G, et al. Segmental arterial mediolysis: abdominal imaging of and disease course in 111 patients. *AJR Am J Roentgenol* 2018; 210:899-905.
- 9) Michael M, Widmer U, Wildermuth S, Barghorn A, Duewell S, Pfammatter T. Segmental arterial mediolysis: CTA findings at presentation and follow-up. *AJR Am J Roentgenol* 2006;187: 1463-1469.
- 10) Slavin RE. Segmental arterial mediolysis: course, sequelae, prognosis, and pathologic-radiologic correlation. *Cardiovasc Pathol* 2009;18:352-360.
- 11) Slovut DP, Olin JW. Fibromuscular dysplasia. *N Engl J Med* 2004;350: 1862-1871.
- 12) Ryan JM, Suhocki PV, Smith TP. Coil embolization of segmental arterial mediolysis of the hepatic artery. *J Vasc Interv Radiol* 2000;11:865-868.
- 13) Lie JT. Systemic, cerebral, and pulmonary segmental mediolytic arteriopathy: villainous masqueraders of vasculitis. *Cardiovasc Pathol* 1996;5:305-314.
- 14) Kalva SP, Somarouthu B, Jaff MR, Wicky S. Segmental arterial mediolysis: clinical and imaging features at presentation and during follow-up. *J Vasc Interv Radiol* 2011;22:1380-1387.
- 15) Baker-LePain JC, Stone DH, Mattis AN, Nakamura MC, Fye KH. Clinical diagnosis of segmental arterial mediolysis: differentiation from vasculitis and other mimics. *Arthritis Care Res (Hoboken)* 2010;62:1655-1660.
- 16) Tameo MN, Dougherty MJ, Calligaro KD. Spontaneous dissection with rupture of the superior mesenteric artery from segmental arterial mediolysis. *J Vasc Surg* 2011;53:1107-1112.
- 17) Kim HS, Min SI, Han A, Choi C, Min SK, Ha J. Longitudinal evaluation of segmental arterial mediolysis in splanchnic arteries: case series and systematic review. *PLoS One* 2016;11: e0161182.
- 18) Soulen MC, Cohen DL, Itkin M, Townsend RR, Roberts DA. Segmental arterial mediolysis: angioplasty of bilateral renal artery stenoses with 2-year imaging follow-up. *J Vasc Interv Radiol* 2004;15:763-767.
- 19) Yun WS, Kim YW, Park KB, Cho SK, Do YS, Lee KB, et al. Clinical and angiographic follow-up of spontaneous isolated superior mesenteric artery dissection. *Eur J Vasc Endovasc Surg* 2009;37:572-577.
- 20) Cho BS, Lee MS, Lee MK, Choi YJ, Kim CN, Kang YJ, et al. Treatment guidelines for isolated dissection of the superior mesenteric artery based on follow-up CT findings. *Eur J Vasc Endovasc Surg* 2011;41:780-785.