

Increased incidence of distal humeral fracture surgery and decreased incidence of respective corrective osteotomy among Finns aged 0 to 18 years between 1987 and 2016: a population-based study

A. Salonen¹
S. T. Niemi²
P. Kannus^{2,3}
E. Laitakari¹
V. M. Mattila³

Abstract

Purpose Previous studies on paediatric and adolescent distal humeral fractures have reported an increase in surgical treatment activity. This increase could be hypothesized to reduce the incidence of corrective osteotomies. The aim of this study was to determine the incidence and trends of the primary surgical treatment of distal humeral fractures and corrective osteotomies in children and adolescents.

Methods All Finns 18 years of age or younger who underwent treatment for distal humeral fracture between 1987 and 2016 were included in this population-based study. Surgical treatment data were obtained from the National Hospital Discharge Register of Finland. In calculating annual surgery incidence rates, the annual mid-year populations were obtained from the Official Statistics Finland. Surgical treatment was categorized into four groups; reposition and casting, osteosynthesis, external fixation and corrective osteotomy.

Results During the 30-year study period, 9017 surgical procedures were performed in Finland with the primary or secondary diagnosis code being a distal humeral fracture. Of these, 6961 (77.2%) were osteosynthesis and the incidence of osteosynthesis (per 100 000 person-years) increased fourfold

from 8.2 in 1987 to 34.1 in 2016. In the same 30-year study period, the total number of corrective osteotomies was low (151) with annual variation from one to 16. The incidence of corrective osteotomies (per 100 000 person-years) decreased sevenfold from 0.7 to 0.1.

Conclusion The incidence of surgical treatment with osteosynthesis in distal humeral fractures increased fourfold in Finland between 1987 and 2016. During the same time period, the number of corrective osteotomies diminished significantly.

Level of Evidence: IV

Cite this article: Salonen A, Niemi ST, Kannus P, Laitakari E, Mattila VM. Increased incidence of distal humeral fracture surgery and decreased incidence of respective corrective osteotomy among Finns aged 0 to 18 years between 1987 and 2016: a population-based study. *J Child Orthop* 2019;13:399-403. DOI: 10.1302/1863-2548.13.190049

Keywords: children; distal humeral fracture; osteosynthesis; osteotomy

Introduction

Distal humeral fractures constitute up to 5% of all paediatric and adolescent fractures, with a peak incidence at the age of four to eight years.¹⁻³ Of these, supracondylar fractures make up over 50% of the total, with an incidence of 308 per 100 000 person-years.¹ Previously, we have reported that both the incidence and primary operative treatment of these fractures have increased. The incidence of osteosynthesis (per 100 000 person-years) increased fivefold between 1987 and 2010 (from six to 30) in children younger than seven years, and twofold (from 14 to 34) in children aged seven to 12 years.⁴

The complication rate in distal humeral fracture treatment, in both conservative and surgical treatment, varies from 3% to 57%.⁵⁻⁷ The most recognizable permanent complications especially concerning supracondylar fractures, i.e. cubitus varus and extension-type malunion, are caused by inadequate fracture reduction in the frontal or sagittal plane.⁷⁻¹⁰ Although the sagittal plane deformity may remodel in children younger than ten years by

¹ Department of Pediatric and Adolescent Surgery, Pediatric Clinic and Pediatric Research Centre, Tampere University Hospital, Tampere, Finland

² Tampere Research Center of Sports Medicine, UKK Institute, Tampere, Finland

³ Department of Orthopaedics and Traumatology, Department of Trauma, Musculoskeletal Surgery and Rehabilitation, Tampere University Hospital, Tampere, Finland

Correspondence should be sent to: A. Salonen, Department of Pediatric and Adolescent Surgery, Pediatric Clinic and Pediatric Research Centre, Tampere University Hospital, Teiskontie 35, 33521 Tampere, Finland.
E-mail: anne.salonen@pp7.inet.fi

up to 20°, the cubitus varus deformity has very limited remodelling capacity.¹⁰⁻¹² Both types of malunions can result in permanent incomplete function of the elbow.^{13,14} The decision for correction osteotomy is considered on an individual basis as there are no well-established indication criteria for the procedure.¹⁵ Correction methods for a malunited distal humeral fracture involve several types of wedge osteotomy as well as external fixation.¹⁶⁻¹⁹ The complication rate concerning late deformity correction is reported to be as high as 34%.^{15,20}

Based on the findings of previous studies, the incidence of surgically treated distal humeral fractures has increased.⁴ The aim of this population-based study was to determine whether the incidence of primary operative treatment with osteosynthesis is still increasing in Finland. We hypothesized that an increase, if present, could result in a decrease in the incidence of subsequent corrective osteotomies.

Material and methods

This study covered the entire paediatric and adolescent population (aged 18 years or younger) of Finland during a 30-year period between 01 January 1987 and 31 December 2016. Procedure codes concerning distal humeral fractures were obtained from the statutory, computer-based National Hospital Discharge Register of Finland (NHDR). The register, founded in 1967, collects information from all hospital categories, including public, private and military hospitals. The NHDR contains data on the age, sex and domicile of patients as well as length of hospital stay, primary and secondary diagnosis and operations performed during the hospital stay. The validity of the NHDR is excellent with respect to both the coverage and accuracy of the database.²¹⁻²³

The main outcome variable in this study was the number of surgical procedures with a main diagnosis of a distal humeral fracture. During the study period, the diagnosis and procedure codes changed from International Classification of Diseases (maintained by WHO) (ICD)-9 (from 1987 to 1996) to ICD-10 (from 1997 to 2016). The distal humeral fracture diagnoses used in this study were 8124A and 8125A (ICD-9 codes) while in ICD-10 coding, S42.4 was used. The procedure codes included reposition and casting (ICD-9 codes 9123, ICD-10 code NBJ41), osteosynthesis (ICD-9 code 9128, ICD-10 code NBJ64), external fixation (ICD-9 code 9130, ICD-10 code NBJ70) and corrective osteotomy (ICD-9 code 9112, ICD-10 code NBK30). For further analysis, patients were classified into three age groups: 0 to 6 years, 7 to 12 years and 13 to 18 years.

To calculate the incidence rates of different procedures, the annual mid-year population of Finland was obtained from the Official Statistic of Finland, an electronic national

population register.²⁴ Statistical analysis was performed using IBM SPSS Statistics version 25 (SPSS, Chicago, IL, USA). Thus, the incidence figures were the true final results of the entire adolescent population in Finland rather than cohort-based estimates with sampling variability and, therefore, 95% confidence intervals were not calculated.

Results

During the 30-year study period, a total of 9017 surgical procedures related to distal humeral fractures were performed. Surgery was more common among boys (n = 5238; 58%) than girls (n = 3779; 42%). The trends in primary surgical procedures are presented in Figure 1. The incidence of reposition and casting remained at a steady level, the incidence of osteosynthesis clearly increased and the incidence of corrective osteotomies decreased (Fig. 1). Altogether, 1857 (21%) reposition and casting procedures were performed during the study period, with a slight fall in incidence from 6.2 to 4.2 per 100 000 person-years. The incidence decreased most in children aged seven to 12 years, from 8.8 to 4.9 per 100 000 person-years. External fixation procedures were performed 48 (0.5%) times on 22 girls and 26 boys during the study period. The incidence of external fixation was thus very low, as the peak incidence in children aged 0 to six years was 1.1 per 100 000 person-years in 1997.

The incidence of osteosynthesis and corrective osteotomy

During the study period, a total of 6961 (77%) osteosynthesis procedures were performed on 4138 (59%) boys and 2823 (41%) girls. The total incidence of osteosynthesis increased fourfold from 8.2 to 34.1 per 100 000 person-years (Fig. 2). In the oldest age group, adolescents

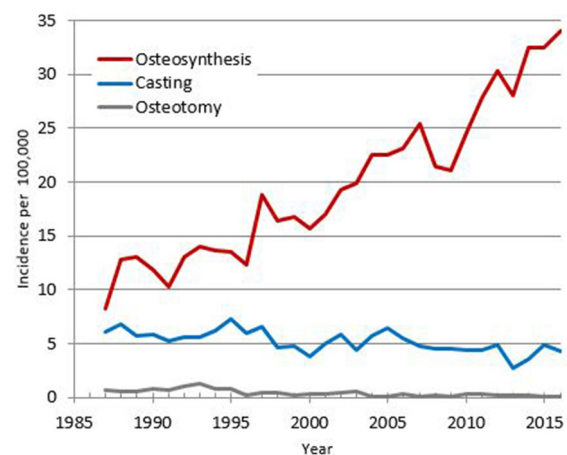


Fig. 1 The incidence of osteosynthesis, casting and corrective osteotomy among girls and boys aged 0 to 18 years between 1987 and 2016.

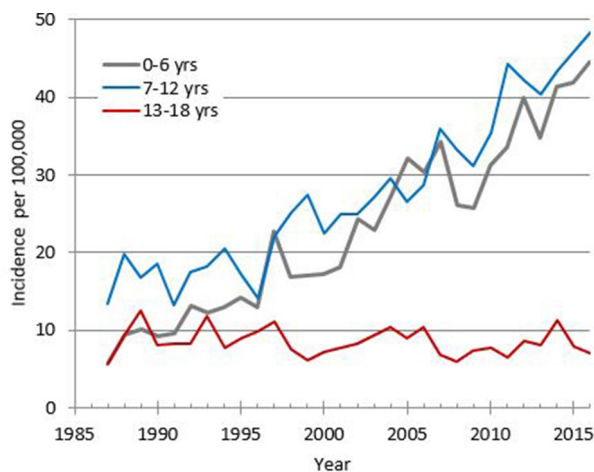


Fig. 2 The incidence of osteosynthesis among girls and boys aged 0 to 18 years between 1987 and 2016, showing three age groups.

aged 13 to 18 years, the incidence remained steady by time with a mean incidence of 9.2 per 100 000 person-years, while the incidence of osteosynthesis increased in the two younger age groups. In children aged 0 to six years, the incidence (per 100 000 person-years) rose almost eightfold, from 5.8 in 1987 to 44.6 in 2016, and in children aged 7 to 12 years, the incidence rose almost fourfold, from 13.4 to 48.4, respectively.

The total number of corrective osteotomies performed during the 30-year study period was 151 (81 boys, 54% and 70 girls, 46%). The incidence of osteotomies decreased sevenfold from 0.7 per 100 000 person-years to 0.1 per 100 000 person-years (Fig. 3). The incidence of osteotomies was highest in the two oldest study groups. In adolescents aged 13 to 18 years old, the incidence ranged from 1.6 per 100 000 person-years in 1987 to 0 per 100 000 person-years in 2016. In children aged seven to 12 years old, the incidence ranged from 1.5 per 100 000 person-years to 0 per 100 000 person-years over the same period.

Discussion

The study described the incidence and trends of primary surgically treated distal humeral fractures and corrective osteotomies among children and adolescents aged 0 to 18 years in Finland between 1987 and 2016. The main outcome was that the overall incidence of osteosynthesis increased while simultaneously the incidence of corrective osteotomy decreased.

Based on the study by Mäyränpää et al,²⁵ the total incidence of paediatric upper-extremity fractures in Finland increased 39% between 1983 and 2005. Moreover,

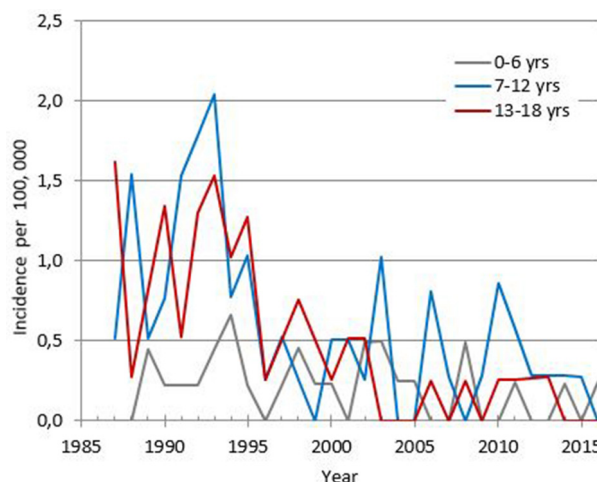


Fig. 3 The incidence of corrective osteotomy among girls and boys aged 0 to 18 years between 1987 and 2016, showing three age groups.

Helenius et al²⁶ reported that the hospitalization of upper-extremity fractures in Finnish children increased by 23% (and surgical treatment by 30%) between 1997 and 2005. In our earlier study concerning the surgical treatment of distal humeral fractures, the incidence of primary osteosynthesis increased markedly in children younger than 13 years: a fourfold increase in children younger than seven years (from six per 100 000 person-years to 30 per 100 000 person-years) and a twofold increase in children aged seven to 12 years (from 14 per 100 000 person-years to 34 per 100 000 person-years) between 1987 and 2010.⁴ Comparing these results with those in the present study, it seems that the incidence of osteosynthesis is still increasing in patients younger than 13 years.

Upper-extremity fractures account for nearly 70% of all childhood fractures and supracondylar fracture is the most common fracture in the elbow region.^{1,2,26} To date, there have been several studies concerning supracondylar fractures treated operatively with closed reduction and osteosynthesis with Kirschner-wires.⁸⁻¹⁰ Although the outcome of fractures treated with osteosynthesis is reported to be good, as judged by Flynn's criteria and Baumann's angle, both closed and open operative techniques are demanding with an increased risk of iatrogenic ulnar nerve injury, soft-tissue infection and loss of reduction.²⁷⁻³³ Cubitus varus and valgus malunion after insufficient reduction are often permanent and may require later correction osteotomy as the function of the elbow remains inadequate.⁷⁻¹⁰ In the studies by Pham et al (2017)³⁴ and Spencer et al (2012),³⁵ Blount's method (reposition and immobilization with collar and sling without osteosynthesis) was reported to be an effective and safe method for even Gartland types II, IIB and III supracondylar fractures. Although the functional results in these studies were mainly good, the

reported complications, such as secondary displacements and cubitus varus, were reported. In the study by Vallila et al (2015),²⁸ the overall complication rate was 1.4%. The study comprised all treated fracture types, i.e. supracondylar, lateral condylar and epicondylar fractures. Of the reported complications, 63% were related to supracondylar fractures, and, of these, 30% were malunions leading to osteotomy. All these fractures were primary treated equally with either reposition and casting or closed or open osteosynthesis.

The decision to perform an osteotomy is always made on an individual basis, and when performed, the patient often requires longer follow-up.¹⁵ There have been several studies concerning different techniques for late osteotomies.^{17-19,36} In a systematic review by Solfelt et al (2014),¹⁵ 40 studies of corrective osteotomies were evaluated. Four principal osteotomy techniques were identified: dome, lateral wedge, distraction osteogenesis and complex osteotomies. All the techniques were equal when they were compared for effectiveness and safety with overall complication rate 14.5%.

To the best of our knowledge, the incidence of distal humeral osteotomies has not previously been recorded. Based on the results of our current study, the incidence of osteotomies performed is very low and it decreased remarkably during the study period, whereas the incidence of osteosynthesis increased.

The strength of this present study is the use of data from the Finnish NHDR, which has provided a very good database of surgical procedures for 30 years. Moreover, the accuracy and coverage of the Finnish NHDR data are reported to be excellent.²¹⁻²³

In addition, treatment has been equally accessible for all Finnish citizens and treatment methods are standardized.

A limitation of this study is the lack of separation between supracondylar, lateral condylar and medial epicondylar fractures as they are classified under the same ICD-9 and ICD-10 codes. Additionally, the procedure codes are equal to all fracture types. Further, the incidence reported in our study is based on all procedure codes indicating that individual patients and their procedure could not be identified and matched.

To summarize, the incidence of osteosynthesis of distal humeral fracture in Finnish children is increasing along with a subsequent decrease in the incidence of corrective osteotomy. The increasing incidence of osteosynthesis can be explained by the awareness of long-term complications. Distal humeral fractures, especially supracondylar fractures, require a precise and stable position to prevent permanent malunion because the remodeling potential of this fracture is very limited. Also, the development of children's anaesthesia, pain managements and operative technique as well as an overall increased trend favouring surgical treatment may have also increased the incidence

of osteosynthesis as the primary method of choice. A causal relationship between the increased incidence of primary osteosynthesis and corrective osteotomies is possible, although difficult to establish and needs further prospective randomized controlled trials.

Received 31 March 2019; accepted after revision 4 July 2019.

COMPLIANCE WITH ETHICAL STANDARDS

FUNDING STATEMENT

No benefits in any form have been received or will be received from a commercial party related directly or indirectly to the subject of this article.

OA LICENCE TEXT

This article is distributed under the terms of the Creative Commons Attribution-Non Commercial 4.0 International (CC BY-NC 4.0) licence (<https://creativecommons.org/licenses/by-nc/4.0/>) which permits non-commercial use, reproduction and distribution of the work without further permission provided the original work is attributed.

ETHICAL STATEMENT

Ethical approval: This article does not contain any studies with human participants or animals performed by any of the authors.

Informed consent: Not required, the study is completely anonymized register study.

ICMJE CONFLICT OF INTEREST STATEMENT

None declared.

AUTHOR CONTRIBUTIONS

STN and PK: Responsible authors of National Hospital Discharge Register.

EL: Commentator, Co-writer.

VMM: Responsible person in Orthopaedics and Traumatology Research Center in Tampere University Hospital.

REFERENCES

1. **Houshian S, Mehdi B, Larsen MS.** The epidemiology of elbow fracture in children: analysis of 355 fractures, with special reference to supracondylar humerus fractures. *J Orthop Sci* 2001;6:312-315.
2. **Hedström EM, Svensson O, Bergström U, Michno P.** Epidemiology of fractures in children and adolescents. *Acta Orthop* 2010;81:148-153.
3. **Landin LA.** Fracture patterns in children. Analysis of 8,682 fractures with special reference to incidence, etiology and secular changes in a Swedish urban population 1950-1979. *Acta Orthop Scand Suppl* 1983;202:1-109.
4. **Salonen A, Pajulo O, Lahdes-Vasama T, Välipakka J, Mattila VM.** Increased incidence of distal humeral fractures and surgical treatment in 0- to 18-year-old patients treated in Finland from 1987 to 2010. *J Child Orthop* 2013;7: 559-564.
5. **Skaggs DL, Flynn JM.** Trauma about the elbow: Overview, supracondylar and transphyseal fractures. In: Skaggs DL, Flynn JM, eds. *Staying out it trouble in pediatric orthopaedics*. Philadelphia, PA: Lippincott Williams & Wilkins, 2006:52-63.
6. **Wilkins KE.** Residuals of elbow trauma in children. *Orthop Clin North Am* 1990;21: 291-314.

7. **Oppenheim WL, Clader TJ, Smith C, Bayer M.** Supracondylar humeral osteotomy for traumatic childhood cubitus varus deformity. *Clin Orthop Relat Res* 1984;188:34-39.
8. **Pirone AM, Graham HK, Krajchich JI.** Management of displaced extension-type supracondylar fractures of the humerus in children. *J Bone Joint Surg [Am]* 1988;70-A:641-650.
9. **Sankar WN, Hebel NM, Skaggs DL, Flynn JM.** Loss of pin fixation in displaced supracondylar humeral fractures in children: causes and prevention. *J Bone Joint Surg [Am]* 2007;89-A:713-717.
10. **Bahk MS, Srikumaran U, Ain MC, et al.** Patterns of pediatric supracondylar humerus fractures. *J Pediatr Orthop* 2008;28:493-499.
11. **Otsuka NY, Kasser JR.** Supracondylar fractures of the humerus in children. *J Am Acad Orthop Surg* 1997;5:19-26.
12. **Omid R, Choi PD, Skaggs DL.** Supracondylar humeral fractures in children. *J Bone Joint Surg [Am]* 2008;90-A:1121-1132.
13. **Guven MF, Kaynak G, Inan M, et al.** Results of displaced supracondylar humerus fractures treated with open reduction and internal fixation after a mean 22.4 years of follow-up. *J Shoulder Elbow Surg* 2015;24:640-646.
14. **Sinikumpu J-J, Victorzon S, Pokka T, et al.** The long-term outcome of childhood supracondylar humeral fractures: A population-based follow up study with a minimum follow up of ten years and normal matched comparisons. *Bone Joint J* 2016;98-B:1410-1417.
15. **Solfelt DA, Hill BW, Anderson CP, Cole PA.** Supracondylar osteotomy for the treatment of cubitus varus in children: a systematic review. *Bone Joint J* 2014;96-B:691-700.
16. **Sudhakar U.** Prospective study of cubitus varus deformity, its etiopathology, clinical study and treatment. *Init J Res Med Sci* 2017;5:201-205.
17. **Belthur MV, Iobst CA, Bor N, et al.** Correction of cubitus varus after pediatric supracondylar elbow fracture: alternative method using the Taylor spatial frame. *J Pediatr Orthop* 2016;36:608-617.
18. **Farr S, Ganger R, Girsch W.** Distal humeral flexion osteotomy for the treatment of supracondylar extension-type malunions in children. *J Pediatr Orthop B* 2018;27:115-120.
19. **Bellemore MC, Barrett IR, Middleton RW, Scougall JS, Whiteway DW.** Supracondylar osteotomy of the humerus for correction of cubitus varus. *J Bone Joint Surg [Br]* 1984;66-B:566-572.
20. **Raney EM, Thielen Z, Gregory S, Sobralke M.** Complications of supracondylar osteotomies for cubitus varus. *J Pediatr Orthop* 2012;32:232-240.
21. **Salmela R, Koistinen V.** Is the discharge register of general hospitals complete and reliable? *Sairaala* 1987;49:480-482.
22. **Keskimäki I, Aro S.** Accuracy of data on diagnoses, procedures and accidents in Finland Hospital Discharge Register. *Int J Health Sci* 1991;2:15-21.
23. **Mattila VM, Sillanpää P, Iivonen T, et al.** Coverage and accuracy of diagnosis of cruciate ligament injury in the Finnish National Hospital Discharge Register. *Injury* 2008;39:1373-1376.
24. **No authors listed.** Official Statistic of Finland, statistics Finland, Helsinki (2017). <http://stat.fi/> (date last accessed 09 July 2019).
25. **Mäyränpää MK, Mäkitie O, Kallio PE.** Decreasing incidence and changing pattern of childhood fractures: A population-based study. *J Bone Miner Res* 2010;25:2752-2759.
26. **Helenius I, Lamberg TS, Kääriäinen S, Impinen A, Pakarinen MP.** Operative treatment of fractures in children is increasing. A population-based study from Finland. *J Bone Joint Surg [Am]* 2009;91-A:2612-2616.
27. **Boyd DW, Aronson DD.** Supracondylar fractures of the humerus: a prospective study of percutaneous pinning. *J Pediatr Orthop* 1992;12:789-794.
28. **Vallila N, Sommarhem A, Paavola M, Nietosvaara Y.** Pediatric distal humeral fractures and complications of treatment in Finland: a review of compensation claims from 1990 through 2010. *J Bone Joint Surg [Am]* 2015;97:494-499.
29. **Liu RW, Roccoft J, Bastrom T, Yaszay B.** Surgeon learning curve for pediatric supracondylar humerus fractures. *J Pediatr Orthop* 2011;31:818-824.
30. **Flynn JC, Matthews JG, Benoit RL.** Blind pinning of displaced supracondylar fractures of the humerus in children. Sixteen years' experience with long term follow up. *J Bone Joint Surg [Am]* 1974;56-A:263-272.
31. **Del Valle-Hernández E, Marrero-Barrera PA, Beaton D, et al.** Complications associated with pediatric supracondylar humeral fractures. *PR Health Sci J* 2017;36:37-40.
32. **Dekker AE, Krijnen P, Schipper IB.** Results of crossed versus lateral entry K-wire fixation of displaced pediatric supracondylar humeral fractures: A systematic review and meta-analysis. *Injury* 2016;47:2391-2398.
33. **Ozkoc G, Gonc U, Kayaalp A, Taker K, Peker TT.** Displaced supracondylar humeral fractures in children: open reduction vs. closed reduction and pinning. *Arch Orthop Trauma Surg* 2004;124:547-551.
34. **Pham TT, Accadbled F, Abid A, et al.** Gartland types IIB and III supracondylar fractures of the humerus in children: is Blount's method effective and safe? *J Shoulder Elbow Surg* 2017;26:2226-2231.
35. **Spencer HT, Dorey FJ, Zions LE, et al.** Type II supracondylar humerus fractures: can some be treated nonoperatively? *J Pediatr Orthop* 2012;32:675-681.
36. **Slongo T.** Treatment of posttraumatic cubitus varus in children and adolescents. Supracondylar humeral osteotomy using radial external fixation. *Oper Orthop Traumatol* 2015;27:194-209.