



## EUS-guided drainage of a 20-cm biloma by use of a lumen-apposing metal stent

Paul Cassis, MD, Sardar Musa Shah-Khan, MD, John Nasr, MD

With the advent of laparoscopic surgery, postoperative bile-duct injuries have become more common over the past several decades.<sup>1</sup> Recent studies have suggested that the incidence of bile-duct injury resulting from laparoscopic cholecystectomies ranges from 0.3% to 0.6%.<sup>2</sup> Disruption of the biliary ductal anatomy can lead to intra-abdominal leakage of bile and the formation of a biloma. A biloma is defined as “any well-demarcated collection of bile outside the biliary tree.”<sup>3</sup> If left untreated, bilomas can lead to significant morbidity and mortality. The rate of bile leakage can be slow or rapid, with the latter frequently resulting in peritonitis. Slow leaks often induce an inflammatory response leading to fibrosis and encapsulation of the fluid collection.<sup>1</sup> Although most bilomas are diagnosed within days to weeks, some case reports have documented bilomas going unrecognized for years.<sup>4</sup> Traditionally, many bilomas were treated with percutaneous drainage performed by an interventional radiologist or surgeon. With the advancement in endoscopic techniques, EUS-guided drainage has emerged as a safe alternative for drainage of large intra-abdominal fluid collections.<sup>5,6</sup>

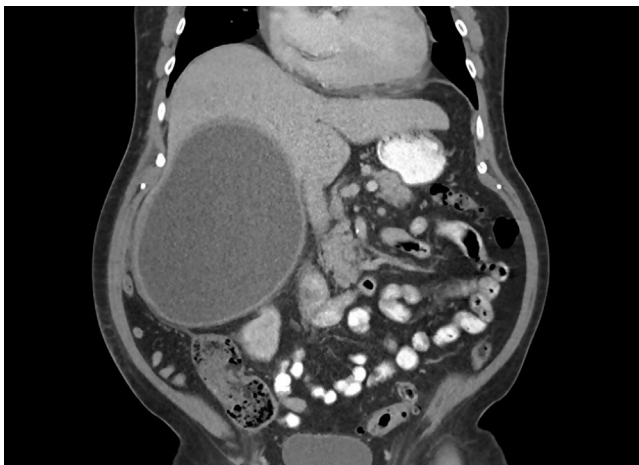We present the case of a 65-year-old man with a history of ascending cholangitis and choledocholithiasis who underwent ERCP with endoscopic sphincterotomy and common bile duct (CBD) stent placement. Soon after hospital discharge, he underwent an outpatient laparo-

scopic cholecystectomy. He underwent repeated ERCP 2 months later with successful stent removal.

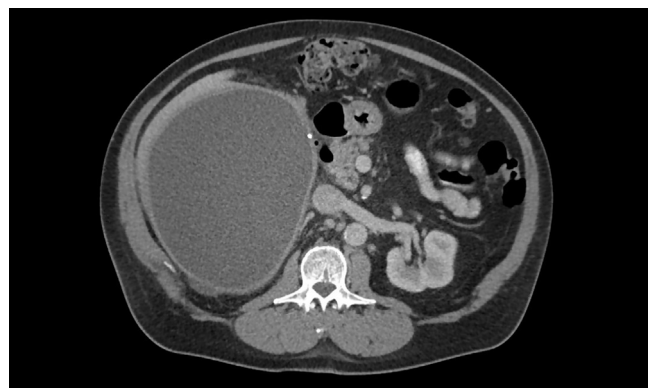The patient presented 4 months later with acute worsening of chronic right upper-quadrant abdominal pain. Complete blood count and liver chemistry test results were unremarkable except for a mild elevation of alkaline phosphatase (175 U/L). CT of the abdomen revealed a large hypodense fluid collection in the inferior aspect of the right hepatic lobe measuring  $19 \times 15.6 \times 20.1$  cm (Figs. 1 and 2). The fluid collection was concerning for an intrahepatic abscess versus a large biloma. After discussion with the hepatopancreaticobiliary surgery service, the decision was made to proceed with EUS-guided drainage of the fluid collection (Video 1, available online at [www.VideoGIE.org](http://www.VideoGIE.org)).

Upper EUS revealed an 11-cm anechoic fluid collection in the right hepatic lobe (US could not encompass the entire lesion). Under EUS guidance, a 15-mm  $\times$  10-mm lumen-apposing metal stent (LAMS) was placed by a free-hand technique, through the lateral wall of the duodenal bulb and into the fluid collection. Once the stent was in place, there was immediate drainage of approximately 1400 mL of turbid, bilious-appearing fluid. The procedure was terminated, and ERCP was performed promptly afterward.

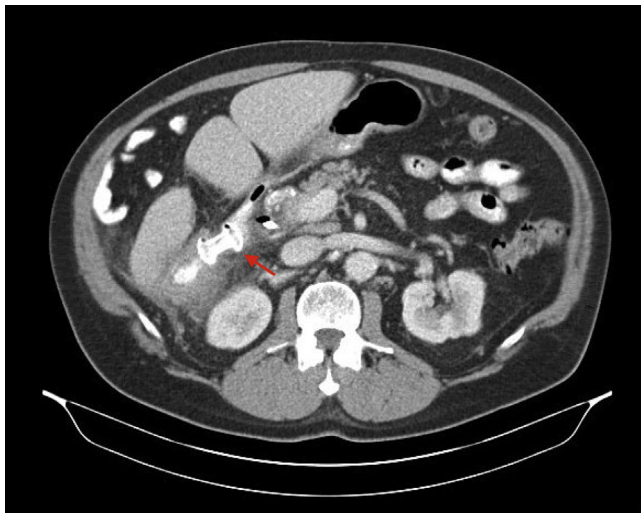
A cholangiogram revealed a low-grade leak from the cystic duct takeoff. The remainder of the biliary tree appeared normal, and balloon sweeps revealed clear bile. A 10F  $\times$  5-cm CBD stent was placed. The patient’s abdominal



**Figure 1.** Initial CT showing a large fluid collection inferior to the right hepatic lobe (coronal view).



**Figure 2.** Initial CT showing a large fluid collection inferior to the right hepatic lobe (axial view).



**Figure 3.** Follow-up CT showing near-complete resolution of the fluid collection (*red arrow*, lumen-apposing metal stent).

pain improved within the first 24 hours, and a follow-up CT scan at week 3 (*Fig. 3*) showed near-complete resolution of the biloma.

EUS-guided drainage has been demonstrated to be a safe and effective therapy for symptomatic bilomas, although most case reports describe the use of traditional double-pigtail stents.<sup>5</sup> It should be noted that endoscopic drainage of a biloma does not treat the underlying bile-duct injury. With the development of the LAMS and its large-bore design, endoscopic drainage of large, mature fluid collections has become more accessible.<sup>7</sup> Our case demonstrates the novel use of an LAMS in the treatment of a mature biloma and is another example of how EUS-guided drainage is a safe, minimally invasive alternative to percutaneous drainage.

## DISCLOSURE

*Dr Nasr is a consultant for Boston Scientific. All other authors disclosed no financial relationships relevant to this publication.*

*Abbreviations: CBD, common bile duct; LAMS, lumen-apposing metal stent.*

## REFERENCES

1. Knebel R, Cheng D, Nikpour A. Diagnosis and management of postoperative biliary leaks. *Semin Intervent Radiol* 2016;33:307-12.
2. Parshad R, Kannan U, Regmi S. An unusual presentation of biloma five years following cholecystectomy: a case report. *Cases J* 2009;2:8048.
3. Copelan A, Bahoura L, Tardy F, et al. Etiology, diagnosis, and management of bilomas: a current update. *Tech Vasc Interv Radiol* 2015;18:236-43.
4. Stojanovic M, Radojkovic M, Jeremic L. Double giant chronic bilomas with late presentation: 9 years after cholecystectomy. *Langenbecks Arch Surg* 2008;393:617-8.
5. Shami V, Talreja J, Mahajan A, et al. EUS-guided drainage of bilomas: a new alternative? *Gastrointest Endosc* 2008;67:136-40.
6. Tonozuka R, Itoi T, Tsuchiya T, et al. EUS-guided drainage of hepatic abscess and infected biloma using short and long metal stents (with videos). *Gastrointest Endosc* 2015;81:1463-9.
7. Alcaide N, Vargas-Garcia A, de la Serna-Higuera C, et al. EUS-guided drainage of liver abscess by using a lumen-apposing metal stent (with video). *Gastrointest Endosc* 2013;78:941-2.

Section of Digestive Diseases, Department of Medicine, West Virginia University, Morgantown, West Virginia, USA.

Copyright © 2019 American Society for Gastrointestinal Endoscopy. Published by Elsevier Inc. This is an open access article under the CC BY-NC-ND license (<http://creativecommons.org/licenses/by-nc-nd/4.0/>).

<https://doi.org/10.1016/j.vgje.2019.09.009>