



Contents lists available at [ScienceDirect](https://www.sciencedirect.com)

JPRAS Open

journal homepage: [www.elsevier.com/locate/jpra](http://www.elsevier.com/locate/jpra)



## Case Report

# Aggressive digital papillary adenocarcinoma and sentinel node biopsy: A case report and literature review

Priya Dhillon\*, Barry Powell, Syed Mehdi

*Department of Plastic Surgery, St George's Hospital, UK*

### ARTICLE INFO

#### Article history:

Received 6 January 2020

Accepted 5 March 2020

Available online 12 March 2020

#### Keywords:

Aggressive digital papillary adenocarcinoma

Sweat gland carcinoma

Sentinel node biopsy

### ABSTRACT

Aggressive digital papillary adenocarcinomas (ADPA) are malignant tumours of the sweat gland. Due to the high tendency to recur and metastasise, wide local resection of the lesion is recommended. However, there are a limited number of cases reporting the use of sentinel node biopsy in the management of ADPA, thus its effectiveness remains unclear. We present a case of ADPA of the right middle finger treated with digital amputation and sentinel node biopsy, and review the current literature focusing on the usefulness of sentinel node biopsy.

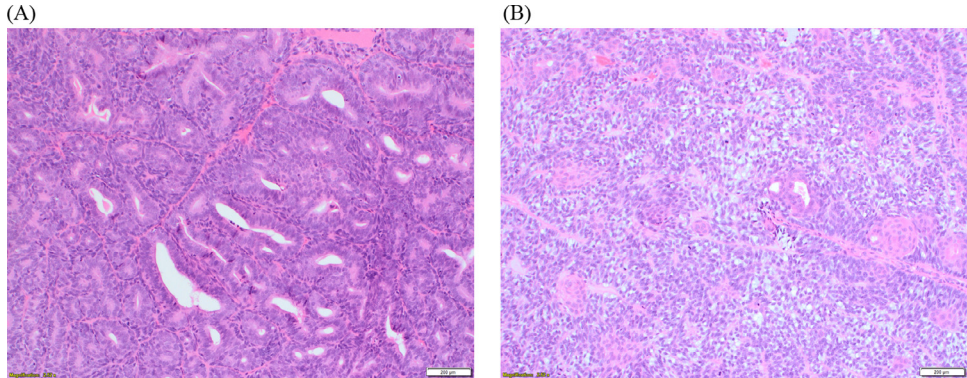
© 2020 The Authors. Published by Elsevier Ltd on behalf of British Association of Plastic, Reconstructive and Aesthetic Surgeons. This is an open access article under the CC BY-NC-ND license.

(<http://creativecommons.org/licenses/by-nc-nd/4.0/>)

## Introduction

Aggressive digital papillary adenocarcinoma (ADPA) is a rare cutaneous tumour of the sweat glands, first described by Helwig in 1979.<sup>1</sup> Based on the histological features, these tumours have a high tendency for local recurrence and metastasis.<sup>2</sup> This uncommon malignancy predominantly affects the distal extremities, and often presents as a painless, firm nodule on the volar surface of the digit.<sup>3</sup> Based on the literature, current guidelines for the management of ADPA recommend local control of the disease by wide local excision of the tumour or digit amputation, with long-term follow-up for recurrence or metastatic spread.<sup>3</sup> Lower rates of local recurrence were reported in patients who

\* Corresponding author.



**Figure 1.** Histological features of digital papillary adenocarcinoma. (A) The tissue section shows back-to-back glands with increased mitotic activity. (B) The image shows clear cell change and squamous metaplasia.

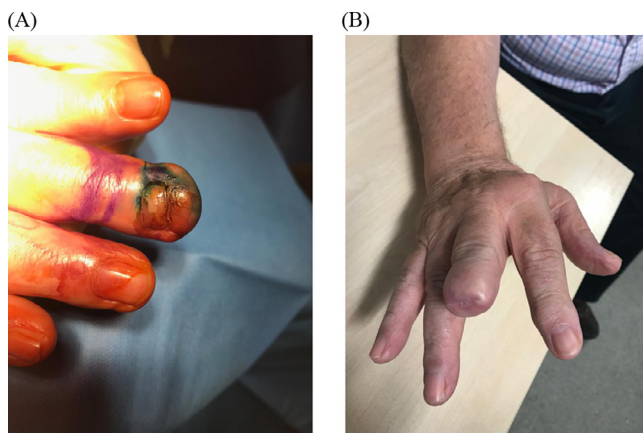
underwent further digital amputation or re-excision, compared with those patients who did not undergo further management.<sup>2</sup> However, there is limited evidence to suggest that sentinel node biopsy (SNB) should form a part of the management plan for ADPA. Currently only 19 cases of ADPA document the use of SNB, of which only 3 reported positive findings. We report a rare case of ADPA in a 76-year-old patient, managed surgically with amputation and SNB.

### Case report

A 76-year-old gentleman presented with a soft tissue lesion on the tip of his right middle finger, which had persisted for over 2 years. The patient was otherwise well, with no other symptoms. His past medical history includes hypertension and arthritis, as well as previous prostate cancer. A 1.5 × 1.5 cm soft tissue lump on the volar medial aspect of the tip of the right middle finger, with lifting of the nail, was noted on examination. Incisional biopsy of the lesion was performed and the tissue was sent for analysis (Figure 1). The histology of the resected specimen showed a basaloid tumour within the dermis, arranged in lobules containing ducts, papillae and sheets of clear cells with small islands of squamous metaplasia. There was mild-moderate atypia within the lesion, and focally, the ducts showed a back-to-back arrangement; all of which are features in keeping with ADPA. Immunohistochemistry staining showed the tumour cells positive for cytokeratin (CK) 7 and epithelial membrane antigen (EMA). Myoepithelial cells were positive for p63 and S100. Computer tomography (CT) and magnetic resonance imaging (MRI) did not demonstrate any evidence of metastatic disease. The case was discussed at the Skin Cancer Multidisciplinary Meeting and surgical management was recommended. The patient was treated with amputation of the finger at the distal interphalangeal (DIP) joint (Figure 2). Lymphoscintigraphy and sentinel node biopsy (SNB) were performed at the same time, in which 3 axillary nodes and 2 supratrochlear nodes were removed. Histopathology revealed negative margins at the amputation site with no involvement of the bone or joint. No lymphovascular or perineural invasion as identified. There was no evidence of metastatic carcinoma in any of the nodes. The patient is being closely followed clinically and has no signs of recurrence at 2 months.

### Literature review

An electronic literature review was conducted on PubMed to identify case reports describing ADPA with the use of SNB, using the search terms: “aggressive digital papillary adenocarcinoma” AND “sentinel node biopsy”. A summary of these cases is shown in Supplementary Table 1.



**Figure 2.** Surgical management of aggressive digital papillary adenocarcinoma (ADPA). (A) Pre-operative photo of biopsy-confirmed ADPA on the volar medial aspect of the tip of the right middle finger. (B) Post-operative photo of amputation of the right middle finger at the distal interphalangeal joint. (Patient consent was obtained for photo-documentation).

## Discussion

Aggressive digital papillary adenocarcinomas are rare tumours derived from eccrine sweat glands, usually involving the distal ends of digits. It is most common in men (with a 9:1 men to female ratio) and tends to occur in the 5th to 7th decade of life.<sup>4</sup> A study by Duke et al.<sup>2</sup> reported metastatic disease in 14%. 50% of patients not treated with further re-excision or digital amputation developed local recurrence, compared to only 5% local recurrence rate in those who did undergo subsequent re-excision or amputation. These findings highlight the importance of prompt surgical management in ADPA, in order to prevent the high rate of local recurrence and metastases. Metastases spread via the lymphatic or haematogenous route, most commonly to the lungs but also the lymph nodes.<sup>6</sup> Sentinel node biopsy is used to stage other cancers, detect early metastasis and initiate treatment sooner. However, the role of SNB in the routine management of ADPA is unclear, as its value has not been widely discussed in the literature.

From our literature review, only 19 cases report the use of SNB for ADPA. Malafa et al.<sup>7</sup> were the first to report the use of SNB in a 44-year-old gentleman with ADPA on the left second toe, whereby 2 nodes were removed and both were negative for metastatic disease.

Since then, only 3 cases have reported positive SNB findings. Bogner et al.<sup>5</sup> reported the first case of a positive SNB result in a 33-year-old lady with ADPA on the right little finger. A total of 5 nodes were biopsied, of which 2 had a positive result. Subsequently, the patient underwent a regional lymphadenectomy, in which all 14 nodes removed were found to be negative. At 3-month follow up, the patient had no evidence of residual or metastatic disease. The most recent report of a positive SNB result is that of a 47-year-old male with ADPA of the right middle finger.<sup>8</sup> 1 axillary sentinel node was biopsied and found to be positive, and so the patient underwent a right axillary lymph node dissection, which revealed no additional positive nodes. However, the report did not comment on local recurrence or metastases, making it difficult to appreciate the long-term benefit in a patient who was managed with a positive SNB result.

Of the 17 reports that commented on follow-up in patients, none of them reported instances of local recurrence or metastases. This data could imply that the use of SNB in patients with ADPA may be associated with a better outcome and prognosis, and thus should form an integral part of the management. However, it is important to note that the follow-up period in these reports range from 2 months to 5 years. Kao et al.<sup>9</sup> reported metastases in 41.2% of patients with ADPA as late as 19 years after initial treatment. Data is required from longer follow-up periods to properly assess the long-term

survival benefit in these patients. Moreover, there are currently not enough reports of patients with ADPA undergoing SNB, especially those with positive findings.

## Conclusion

The overall utility of sentinel node biopsy in the management of ADPA remains unclear. Although there are no established clinical guidelines, due to the highly aggressive nature of these tumours and the potential for recurrence and metastasis, wider excision should be the treatment of choice. Sentinel node biopsy may be useful for staging disease, and on the basis of more evidence, may contribute to better prognosis.

## Declaration of Competing Interest

None declared.

## Funding

None

## Ethical approval

Not required.

## Supplementary materials

Supplementary material associated with this article can be found, in the online version, at doi:[10.1016/j.jpra.2020.03.001](https://doi.org/10.1016/j.jpra.2020.03.001).

## References

1. Helwig EB. Aggressive digital papillary adenoma. Proceedings of the American Academy of Dermatology Clinical Pathology Conference; 1979.
2. Duke WH, Sherrod TT, Lupton GP. Aggressive digital papillary adenocarcinoma (aggressive digital papillary adenoma and adenocarcinoma revisited). *Am J Surg Pathol*. 2000;24:775–784.
3. Rismiller K, Knackstedt TJ. Aggressive digital papillary adenocarcinoma: population-based analysis of incidence, demographics, treatment, and outcomes. *Dermatol Surg*. 2018;44:911–917.
4. Balci MG, Tayfur M, Deger AN, Cimen O, Eken H. Aggressive papillary adenocarcinoma on atypical localization: a unique case report. *Med (Baltim)*. 2016;95:28.
5. Bogner PN, Fullen DR, Lowe L. Lymphatic mapping and sentinel lymph node biopsy in the detection of early metastasis from sweat gland carcinoma. *Cancer*. 2003;97:2285–2289.
6. Hsu HC, Ho CY, Chen CH, Yang CH, Hong HS, Chuang YH. Aggressive digital papillary adenocarcinoma: a review. *Clin Exp Dermatol*. 2010;35:113–119.
7. Malafa MP, McKesey P, Stone S, Dudley-Walker S, Cockerell CJ. Sentinel node biopsy for staging of aggressive digital papillary adenocarcinoma. *Dermatol Surg*. 2000;26:580–583.
8. Kempton SJ, Navarrete AD, Salyapongse AN. Aggressive digital papillary adenocarcinoma. *Ann Plast Surg*. 2015;75:34–36.
9. Kao GF, Helwig EB, Graham JH. Aggressive digital papillary adenoma and adenocarcinoma. a clinicopathological study of 57 patients, with histochemical, immunopathological, and ultrastructural observations. *J Cutan Pathol*. 1987;14:129–146.