

Radical and sparing surgical treatment of patients with upper urinary tract transitional cell carcinomas (UUT-TCC) – preliminary results

Zbigniew Jabłonowski, Robert Kędzierski, Marek Sosnowski

1st Department of Urology, Medical University of Łódź, Poland

KEY WORDS

transitional cell carcinoma ▶ upper urinary tract ▶ carcinoma of the ureter ▶ carcinoma of the renal pelvis

ABSTRACT

Introduction. Tumors originating from transitional epithelium of the renal pelvis and ureter are infrequent. Their course is asymptomatic at early stages of the disease, and diagnosis and institution of appropriate treatment delayed. The aim of the study is to assess the results of treatment in patients with upper urinary tract transitional cell carcinomas (UUT-TCC).

Material and methods. Fifteen patients treated in 2005–2010 for UUT-TCC were qualified for the retrospective study. Clinical symptoms, diagnostic methods, tumor location, clinical stage and histopathological characteristics of the tumors were assessed. Then, the instituted treatment and its results were analyzed.

Results. The average follow-up period was 51 month (range 6–65), UUT-TCC accounted for 6.7% of renal tumors treated. Concurrent treated vesical tumors were observed in 4 (26.7%) patients. Primary UUT-TCC was diagnosed in 10 (66.7%) patients. Radical surgery was performed in 10 (66.7%) patients, whereas 5 (33.3%) underwent sparing operations. Macroscopic hematuria was the predominant clinical symptom. In most cases T2–T3 clinical stage (60.0%) and high-grade (66.7%) were observed. Development of an upper urinary tract tumor after treatment of a vesical tumor was noted in 4 (26.7%) patients. During the follow-up period, urinary bladder carcinomas were diagnosed in 5 (33.3%) patients with primary upper urinary tract tumors.

Conclusions. Nephroureterectomy remains the standard treatment for UUT-TCC. Organ-sparing surgery is possible in selected patients with low clinical stage and low grade tumors. Patients treated for urinary bladder carcinomas require regular monitoring of the upper urinary tract.

INTRODUCTION

Upper urinary tract transitional cell carcinomas (UUT-TCC) are relatively rare tumors. They are estimated to account for 5% of all tumors originating from the urothelium. Urothelial tumors lo-

cated in the kidneys account for 5 to 10% of renal tumors; at the same time however, urothelial tumors of the renal pelvis are detected three-fold more frequently than tumors of the ureters [1].

Tumors arising from the upper urinary tract urothelium are more often diagnosed in men; for renal pelvis tumors the M:F ratio equals 3:2, and for tumors located in the ureters – 2:1 [2, 3].

Surgical nephroureterectomy, including the ureteral orifice, first described by Albarran in 1909, then by Kimball and Ferris in 1934, still remains the „gold standard” of treatment in UUT-TCC [1]. However, in selected patients with low clinical stage and low histological malignancy grade tumors, the extent of the surgery can be limited. Vest was the first to point it out in 1945 [4]. Currently, the following indications for organ-sparing treatment of UUT-TCC exist: failure or lack of the contralateral kidney, bilateral TCC or high risk of tumor development in the region of the other kidney, coincident conditions increasing the risk of nephroureterectomy-related complications, palliative management, low-grade histological malignancy, and low clinical stage of the tumor [2].

Organ-sparing treatment by open surgery can involve partial nephrectomy, pyelectomy or ureterectomy, including the tumor, or resection of the lower segment of the ureter and its ureteral orifice together with the tumor.

In 1985, attempts to treat UUT-TCC with endoscopic methods were started, when Huffman was the first to describe the application of ureterorenoscopy in resection of a ureteral tumor [5]. Endoscopic methods include currently percutaneous electroresection, ureterorenoscopic electroresection, and laser ablation of the tumor [1, 6].

Laparoscopy has extended the range of the methods used in urology for the treatment of upper urinary tract tumors. Nowadays, many laparoscopic centers, including Polish ones, perform resections of the kidney together with the ureter and the ureteral orifice and in selected cases ureterectomies with tumor resection [2, 7, 8].

The aim of the study was to analyze the results of treatment in patients with UUT-TCC.

MATERIAL AND METHOD

Fifteen patients treated for UUT-TCC in the 1st Department of Urology, Medical University of Lodz in 2005–2010 were included in this retrospective study. The patients' age ranged from 41 to 72 years (64 on average); men (10/15 patients) accounted for 66.7% of the studied patient population. Macroscopic hematuria, observed in 9/15 cases (60.0%), was the predominant clinical symptom; microscopic hematuria was present in all the patients. In seven patients, the tumor was located in the ureter and in eight – in the renal pelvis. In 10/15 patients (67.7%) a single tumor was found, whereas in 5/15 (33.3%) the lesions were multifocal.

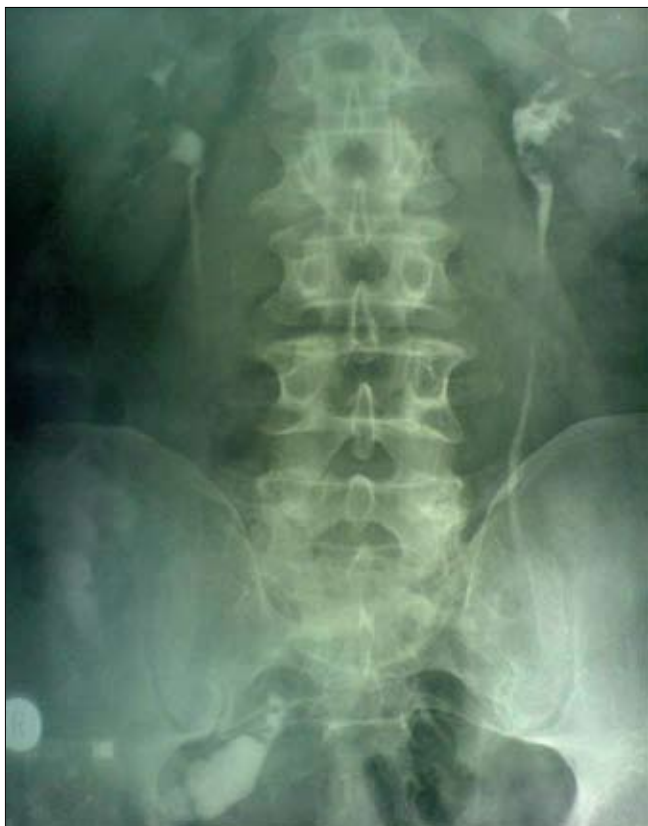

Fig. 1. Patient W.H.62 y – IVP: left renal pelvis tumor suspicion.

Classification for the surgery included assessment of the patients for:

- number of tumors and their location,
- clinical stage of the tumor,
- histological classification of the tumor,
- renal function,
- general clinical condition of the patient.

The decision concerning radical or organ-sparing management was based on the overall presentation of the disease (Figs. 1 & 2). Open nephroureterectomy (O-NFU) was performed in 10/15 patients (66.7%), whereas 5/15 patients (33.3%) underwent organ-sparing

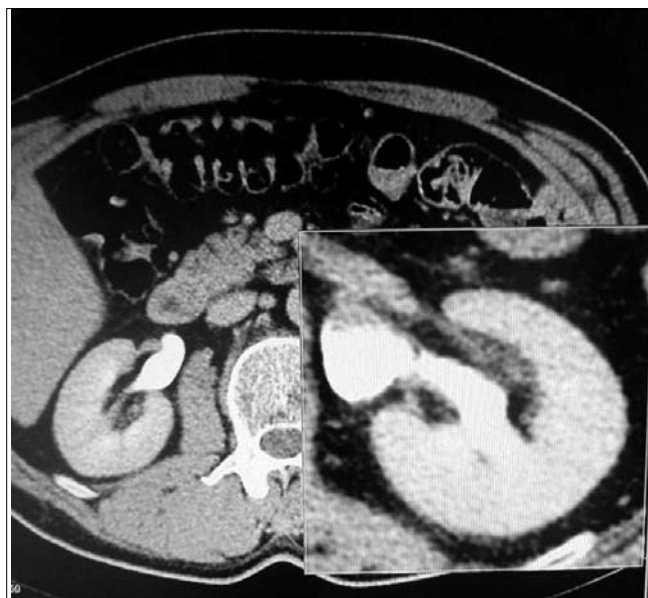

Fig. 2. Same patient-CT: left renal pelvis tumor.

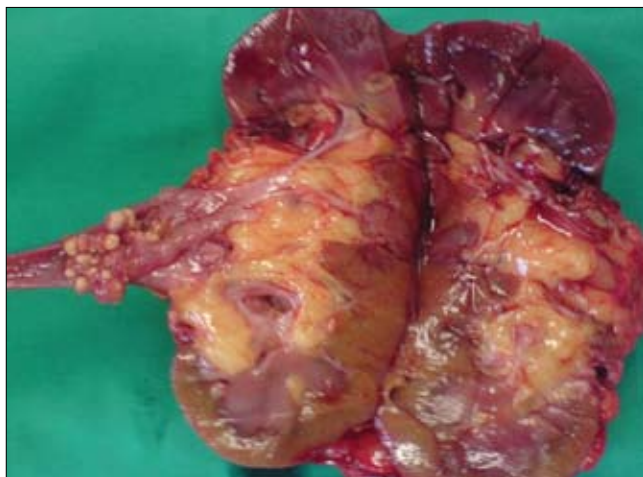


Fig. 3. Same patient – after nephroureterectomy – left renal pelvis tumor pT2, G2.

treatment (Figs. 3, 4). Organ-sparing surgery involved partial resection of the ureter with the tumor – in three patients (20.0%), partial resection of the solitary kidney together with the tumor of the renal pelvis in one female patient (6.7%) and partial bilateral ureterectomy including the tumor in another female (6.7%) (Fig. 5).

The instituted methods of treatment are presented in Table 1.

After surgical treatment, the patients remained under regular follow-up.

Control examinations performed in asymptomatic patients included:

- cytology of urine sediment at 3-month intervals;
- cystoscopy, ureterorenoscopy (in patients after ureter-sparing surgeries) – at 3-month intervals.
- urography at 6-month intervals.

During ureterorenoscopy, urine for cytological investigation was additionally collected.

The duration of follow-up ranged from 6- to 65-months (mean 51-months).

RESULTS

Patients with UUT-TCC accounted for 6.7% of all patients who underwent surgical treatment for renal tumors in our department. Primary UUT-TCC was diagnosed in 11 patients (73.3%), whereas tumors after bladder cancer treatment were observed in three cases (20.0%).

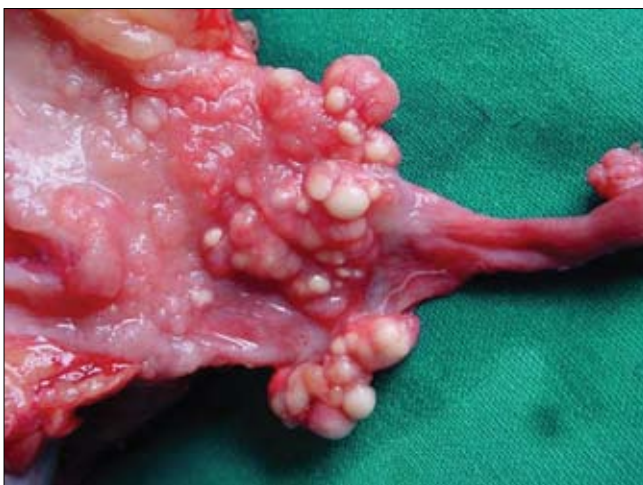

Fig. 4. Fig. 4. Same patient – after nephroureterectomy – left renal pelvis tumor pT2, G2.

Table 1. Analysis of the clinical material

		Percentage	Number of patients
Tumor location	Renal pelvis	53.3%	8
	Ureter	46.7%	7
Type of procedure	Open nephroureterectomy	66.7%	10
	Partial ureterectomy	26.7%	4
	Partial nephrectomy & resection of renal pelvis tumor	6.7%	1
UUT-TCC, in patients treated for vesical tumors		26.7%	4
Vesical tumors, in patients treated for UUT-TCC		33.3%	5
High-grade UUT-TCC		66.7%	10
Low-grade UUT-TCC		33.3%	5

UUT-TCC coincided with urinary bladder carcinoma at the time of diagnosis in one patient (6.7%).

During the follow-up period, urinary bladder carcinomas were diagnosed in five (33.3%) patients with primary upper urinary tract tumors.

In nine cases (60.0%), cT2-T3 clinical stage and in 10 (66.7%) – high-grade tumors were observed; all the patients in this group underwent radical nephroureterectomy.

In three patients (20.0%) with primary UUT-TCC, metastases outside the urinary tract were diagnosed (in the lymph nodes). The analyzed clinical material is presented in Table 1.

DISCUSSION

Malignant tumors originating from transitional epithelium of the renal pelvis and ureter are infrequent. Their course is asymptomatic at early stages of the disease, which often leads to delayed diagnosis and institution of appropriate treatment [1-3].

Such tumors are more frequent in men and in representatives of Caucasian race, with the peak incidence observed between 60 and 70 years of age [6]. Higher incidence of UUT-TCC in Balkan countries is interesting [9]. The tumors are observed to occur bilaterally in approx. 2% of patients.

Ureter nephrectomy is still considered to be the gold standard of management in patients with UUT-TCC. Ureter-sparing resection is associated with high risk of tumor relapse in the stump (19-65%), whereas sparing of the ureteral ostium is believed to carry the risk

of relapse in that region in approx. 40% of patients. The results of treatment depend on the clinical stage of the tumor at the time of diagnosis, as well as on its histological grade. Tumor relapses in the urinary bladder after 5-year follow-up can be expected in approx. 10% of patients with Tis-T1, 60% patients with T2-T3, and even in 77% of patients with tumors diagnosed at T4 stage. Five-years survival rates are estimated at 100% for Ta, 91.7% for T1, 72.6% for T2, and 40.5% for T3 tumors [2, 3].

The introduction of advanced endoscopic techniques to diagnosis and treatment of urinary tract diseases has contributed to improvement in early diagnostics as well as changes to the methods of treatment used in patients with upper urinary tract tumors [10-12]. Urography and ascending pyelography are still useful in diagnostics, but most detailed information can be obtained by ureterorenoscopy associated with collection of specimens from suspicious sites. This method allows more accurate staging and grading of the tumor. Most authors regard these two parameters as most reliable with respect to pronging patients' survival time and most important in planning the extent of surgical treatment [13, 14]. Only some of the authors emphasize the importance of other factors, such as multifocal character [15, 16] or localization of the tumor [17]. Objections concerning the high invasiveness of endoscopic diagnostics associated with the possibility of transferring tumor cells to other parts of the urinary tract have not been confirmed by the reports of American authors [18]. There were also no cases of harmful consequences of ureteroscopic biopsies in our patients.

Ureterorenoscopy is most frequently performed using semi-rigid and flexible instruments, which allow more precise maneuvers in the ureter and more reliable collection of material for histopathological investigations [10, 12, 13]. Our own therapeutic decisions were also based on the results of histopathological investigations of specimens obtained by ureterorenoscopy performed with a semi-rigid device.

Although most authors agree that open radical nephroureterectomy (O-RNU) still remains the standard method of treatment for UUT-TCC, there are more and more arguments in favor of endoscopic methods and laparoscopic techniques [1, 6, 7, 12]. The supporters of endoscopy even claim that it should be used as first-line therapy in almost all patients, provided that both the doctor and the patient accept the necessity of regular monitoring and the potential need for subsequent procedures [12, 13]. However, most supporters of less invasive methods of treatment for UUT-TCC agree that endoscopic resection is associated with the best prognosis in the case of tumors assessed as low-grade ones (former G1, G2 at the highest). In patients with higher histological malignancy grade detected by biopsy, endoscopic treatment of each patient

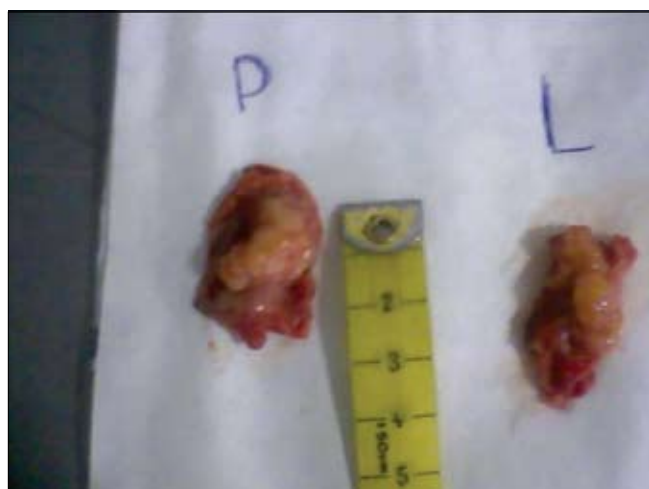

Fig. 5. Patient G.A. 68 y – specimens after bilateral partial ureterectomy – TCC, pT1, G1.

depends on the individual decision [11, 13]. In a study assessing the safety of endoscopic procedures on the basis of 155 patients, Boorjian et al. demonstrated that no negative effects on survival of postponed O-RNU performed after endoscopic diagnostics and endoscopic laser ablation of the tumor were observed [18]. In our material we also did not observe any unfavorable consequences of endoscopic diagnostic procedures.

Partial resection of the ureter together with the tumor site is performed after exclusion of multifocal character of the tumor in patients with low-grade and low-stage lesions [1, 6, 7]. Organ-sparing operations were performed in 33.3% of patients, including one woman who underwent bilateral resection of single tumors located in the lower segments of both ureters during the same procedure. In patients after sparing procedures, regular, periodic cytological investigations of urine and endoscopic assessment of the urinary tract together with imaging studies (USG and CT) are mandatory [12].

The application of laparoscopy to the radical treatment of patients with UUT-TCC is still a new problem. The latest reports demonstrate identical oncological results of laparoscopic-radical nephroureterectomy (L-RNU) in comparison with those of O-RNU, with all the known advantages of laparoscopy (shorter hospitalization time, less pain, excellent cosmetic effect) [7]. The method of dissection of the vesicular tissue margin around the ureteral ostium seems to be of no importance. Endoscopic transurethral resection of the bladder „cuff” contributes to reducing the time of this part of the procedure [19, 20].

The incidence of malignant tumors of the urinary bladder in patients operated on for UUT-TCC and the incidence of transitional cell carcinomas in the upper urinary tract in patients with primary epithelial vesical tumors is worth considering. The incidence of secondary carcinomas of the urinary bladder is believed to be high (ranging from 20% to 50%) in patients previously diagnosed with UUT-TCC. A reversed situation is less frequent: only 0.7-4% of patients treated for vesical tumors is expected to develop UUT-TCC [6]. In our material, this incidence rate amounted to 4.1%.

Adjuvant treatment, e.g. BCG therapy after sparing procedures (endoscopic resection of the tumor, or resection of the tumor with partial ureterectomy) seems to be safe, but further evaluation of its efficacy is necessary [6].

CONCLUSIONS

- Nephroureterectomy remains the standard treatment for UUT-TCC.
- Organ-sparing surgery is possible in selected patients with low clinical stage and low-grade tumors.
- Patients treated for urinary bladder carcinomas require regular monitoring of the upper urinary tract.

REFERENCES

1. Zigeuner R, Pummer K: *Urothelial Carcinoma of the Upper Urinary Tract: Surgical Approach and Prognostic Factors*. Eur Urol 2008; 53: 671-868.
2. Oosterlinck W, Solsona E, van der Meijden APM, et al: *EAU guidelines on diagnosis and treatment of upper urinary tract transitional cell carcinoma*. Eur Urol 2004; 46: 147-154.
3. Sanderson KM, Cai J, Miranda G et al: *Upper tract urothelial recurrence following radical cystectomy for transitional cell carcinoma of the bladder: an analysis of 1,069 patients with 10-year follow-up*. J Urol 2007; 177: 2088-2094.
4. Vest SA: *Conservative surgery in certain benign tumors of the ureter*. J Urol 1945; 53: 97-99.

5. Huffman JL, Morse MJ, Herr HW et al: *Ureteropyeloscopy: the diagnostic and therapeutic approach to upper tract urothelial tumors*. World J Urol 1985; 1: 58-63.
6. Kirkali Z, Tuzel E: *Transitional cell carcinoma of the ureter and renal pelvis*. Crit Rev Oncol Hematol 2003; 47: 155-169.
7. Waldert M, Remzi M, Klingler HC et al: *The oncological results of laparoscopic nephroureterectomy for upper urinary tract transitional cell cancer are equal to those of open nephroureterectomy*. BJU Int 2009; 103: 66-70.
8. Zhang DX, Shen HL, Lü WC et al: *Carcinoma recurrence rates after laparoscopic nephroureterectomy in patients undergoing transurethral incision of the ureteral orifice and open excision of bladder cuff*. Zhonghua Yi Xue Za Zhi 2008; 88: 2854-2856.
9. Dragicevic D, Djokic M, Pekmezovic T et al: *Survival of patients with transitional cell carcinoma of the ureter and renal pelvis in Balkan endemic nephropathy and non-endemic areas of Serbia*. BJU Int 2007; 99: 1357-1362.
10. Keeley FX, Kulp DA, Bibbo M et al: *Diagnostic Accuracy of Ureteroscopic Biopsy in Upper Tract Transitional Cell Carcinoma*. J Urol 1997; 157: 33-37.
11. Keeley Jr. FX, Bibbo M, Bagley DH: *Ureteroscopic Treatment and Surveillance of Upper Urinary Tract Transitional Cell Carcinoma*. J Urol 1997; 157: 1560-1565.
12. Wolf Jr. JS: *Are we underutilizing minimally invasive approaches for upper tract urothelial carcinoma?* Urol Oncol 2009; 27: 75-80.
13. Bader MJ, Sroka R, Gratzke Ch et al: *Laser Therapy for Upper Urinary Tract Transitional Cell Carcinoma: Indications and Management*. Eur Urol 2009; 56: 65-71.
14. Soderdahl DW, Fabrizio MD, Rahman NU et al: *Endoscopic treatment of upper tract transitional cell carcinoma*. Urol Oncol 2005; 23: 114-122.
15. Terakawa T, Miyake H, Muramaki M et al: *Risk factors for intravesical recurrence after surgical management of transitional cell carcinoma of the upper urinary tract*. Urology 2008; 71: 123-127.
16. Koda S, Mita K, Shigeta M, Usui T: *Risk factors for intravesical recurrence following urothelial carcinoma of the upper urinary tract: no relationship to the mode of surgery*. Jpn J Clin Oncol 2007; 37: 296-301.
17. Ataus S, Onal B, Tunc B et al: *Factors affecting the survival of patients treated by standard nephroureterectomy for transitional cell carcinoma of the upper urinary tract*. Int Urol Nephrol 2006; 38: 9-13.
18. Boorjian S, Ng C, Munver R et al: *Impact of delay to nephroureterectomy for patients undergoing ureteroscopic biopsy and laser tumor ablation of upper tract transitional cell carcinoma*. Urology 2005; 66: 283-287.
19. Matsui Y, Utsunomiya N, Ichioka K et al: *Risk factors for subsequent development of bladder cancer after primary transitional cell carcinoma of the upper urinary tract*. Urology 2005; 65: 279-283.
20. Walton TJ, Sherwood BT, Parkinson RJ et al: *Comparative outcomes following endoscopic ureteral detachment and formal bladder cuff excision in open nephroureterectomy for upper urinary tract transitional cell carcinoma*. J Urol 2009; 181: 532-539.

Correspondence

Zbigniew Jabłonowski
1st Department of Urology
Medical University of Łódź
113, Żeromskiego Street
90-549 Łódź, Poland
phone: +48 42 63 93 531
zby_szek@tlen.pl