

Ustekinumab-associated disseminated verrucae



Mary E. Anderson, MD,^a Dawn Queen, BA,^b Stephen L. Vance, MD,^c and Larisa J. Geskin, MD^c
Dallas, Texas and New York, New York

Key Words: biologics; immunosuppression; psoriasis; ustekinumab; verrucae.

INTRODUCTION

Ustekinumab is a human interleukin (IL)12/23 antagonist with US Food and Drug Administration indications to treat moderate to severe plaque psoriasis, psoriatic arthritis, and Crohn's disease. Because of the blockade of the IL-12/IL-13 pathway, which mediates antitumor and antiviral responses, ustekinumab has significant immunosuppressive characteristics and can lead to an increased risk of infection, reactivation of latent infection, and malignancy in patients. We present a case of a patient with psoriasis and psoriatic arthritis on ustekinumab who had disseminated verrucae shortly after initiating treatment.

CASE REPORT

A 54-year-old Colombian man presented to our dermatology clinic with a chief complaint of a progressive red rash on his genitals and lower extremities for greater than 1 year. He had a 35-year history of plaque psoriasis and psoriatic arthritis, treated previously with etanercept and adalimumab with initial clearance of his lesions. Etanercept was discontinued because of relapse of psoriasis, and adalimumab was discontinued because of loss of insurance coverage. He was then started on ustekinumab. Although his psoriasis went into complete remission, disseminated bumps developed approximately 6 months later.

On presentation, his physical examination was notable for innumerable 2- to 8-mm pink and skin-colored verrucous papules on the trunk, genitalia, and lower extremities (Fig 1, A). Skin biopsies confirmed clinical suspicion of verruca vulgaris. However, destructive therapy, such as cryosurgery or other similar modalities, was not recommended

Abbreviations used:

APC:	antigen presenting cell
HPV:	human papilloma virus
IFN:	interferon
IL:	interleukin
PDT:	photodynamic therapy
Th:	helper T cell
TNF:	tumor necrosis factor

because of the generalized distribution of the warts and concern for Koebner phenomenon. There also was concern about using imiquimod therapy because of its stimulation of interferon- α production, which may exacerbate psoriasis.

Considering the wide distribution of verrucae, photodynamic therapy (PDT) was recommended and successfully implemented. He received 2 cycles of PDT over the course of a month, with significant reduction of verrucae. However, during that time, he felt that his psoriatic lesions were increasing in number. Because he previously tolerated adalimumab well without development of verrucae, ustekinumab was discontinued, and 1 month later he was restarted on adalimumab with the goal of regaining control of his psoriasis and psoriatic arthritis. After 4 months on adalimumab, he reported flattening of his psoriatic and verrucous plaques and decreasing scale, with mild joint pain of hands, shoulders, and back. Four months later, he received 1 additional PDT treatment with further improvement in the number and size of his verrucous lesions (Fig 1, B). His verrucae have continued to gradually clear, his psoriasis is now well controlled, and his psoriatic arthritis persists but has not worsened.

From University of Texas Southwestern Medical Center^a; Columbia University Vagelos College of Physicians and Surgeons^b; and the Department of Dermatology, Columbia University Medical Center.^c

Funding sources: None.

Conflicts of interest: None disclosed.

Correspondence to: Larisa J. Geskin, MD, 161 Fort Washington Ave, 12th Floor, New York, NY 10032. E-mail: ljj2145@cumc.columbia.edu.

JAAD Case Reports 2018;4:1030-3.
 2352-5126

© 2018 by the American Academy of Dermatology, Inc. Published by Elsevier, Inc. This is an open access article under the CC BY-NC-ND license (<http://creativecommons.org/licenses/by-nc-nd/4.0/>).

<https://doi.org/10.1016/j.jidcr.2018.08.014>

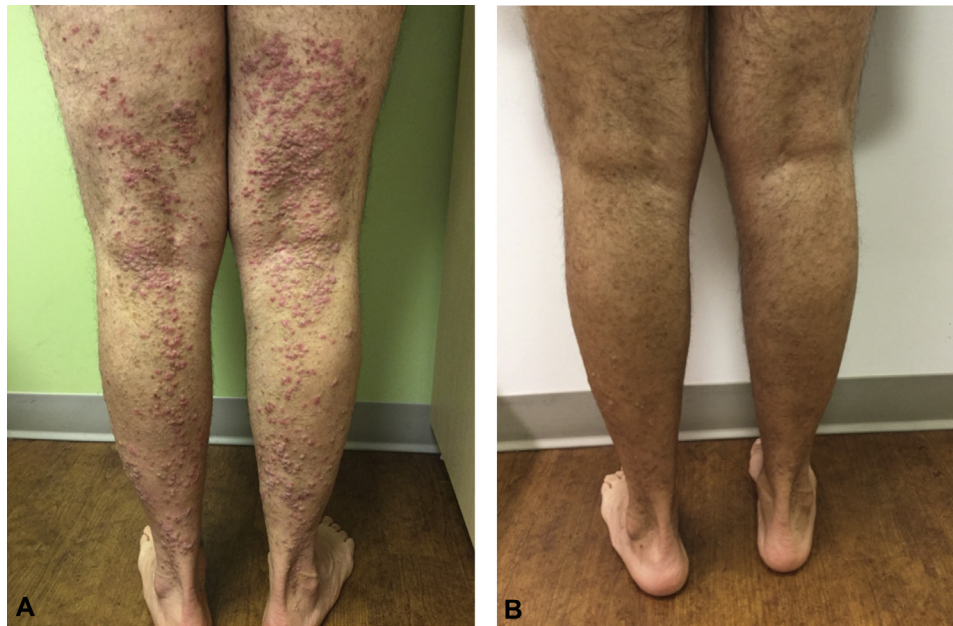


Fig 1. A, Disseminated verrucae: multiple pink to skin-colored papules in a scattered distribution over the bilateral lower extremities. **B**, Patient after 3 PDT cycles: significant improvement in the number and size of verrucous lesions.

DISCUSSION

Psoriasis is a T-cell–mediated autoimmune disease characterized by chronic inflammation and defective epidermal barrier function. Biologic agents including tumor necrosis factor (TNF) inhibitors, ustekinumab, and others have become mainstream therapy. The ACCEPT trial in 2010, which directly compared the 2 biologic therapies, ustekinumab and etanercept, found that over a 12-week period, ustekinumab had superior efficacy to etanercept and a comparable rate of serious infection.¹ Although TNF inhibitor use has long been associated with increased risk for infections,² including verrucae,³ ustekinumab is still a relatively new therapy, and data are limited on its safety.

Ustekinumab is a human monoclonal antibody approved by the US Food and Drug Administration for the management of psoriasis and psoriatic arthritis. The drug acts by binding to and inhibiting the shared p40 subunit of IL-12 and IL-23, pro-inflammatory cytokines that are overrepresented in psoriatic skin lesions.⁴ Greater than 90% of moderate to severe plaque psoriasis patients see a clinically significant improvement of their symptoms after ustekinumab. The adverse effects from ustekinumab in patients treated for up to 5 years were evaluated in a pooled data analysis from 2 clinical trials, PHOENIX 1 and PHOENIX 2. The investigators did not find an increased risk of malignancies or

lymphoproliferative disorders other than an increase in keratinocyte carcinomas, similar to TNF- α inhibitors.⁴ A follow-up study evaluating long-term safety confirmed overall low and favorable rates of adverse events.⁵ Serious infections occurred infrequently, at a rate comparable to those of anti-TNF agents. Malignancies other than nonmelanoma skin cancer had a reported incidence equal to that of the general US population. However, there was an increased incidence of nonmelanoma skin cancer, especially in patients with preexisting risk factors.

The immunosuppressive characteristics of ustekinumab arise from the blockade of the IL-12/IL-23 pathway, which is necessary for host defense against various viral, bacterial, and fungal pathogens.⁶ Under normal conditions, activated antigen-presenting cells (APCs) produce IL-12, which is a T-cell–stimulating factor involved in the differentiation of naive T cells into helper T (Th)1 cells. These Th1 cells produce cytokines including interferon (IFN)- γ , IL-2, and TNF- α and reduce IL-4–mediated suppression of IFN- γ . Through the release IFN- γ and other cytokines, Th1 cells promote macrophage activation, B cell production of opsonizing antibodies, and cytotoxic T cell proliferation. Together, these effector cells attack virally infected or cancerous cells.

A strong Th1 response is key to clearing human papilloma virus (HPV) infection, and lack of a normal

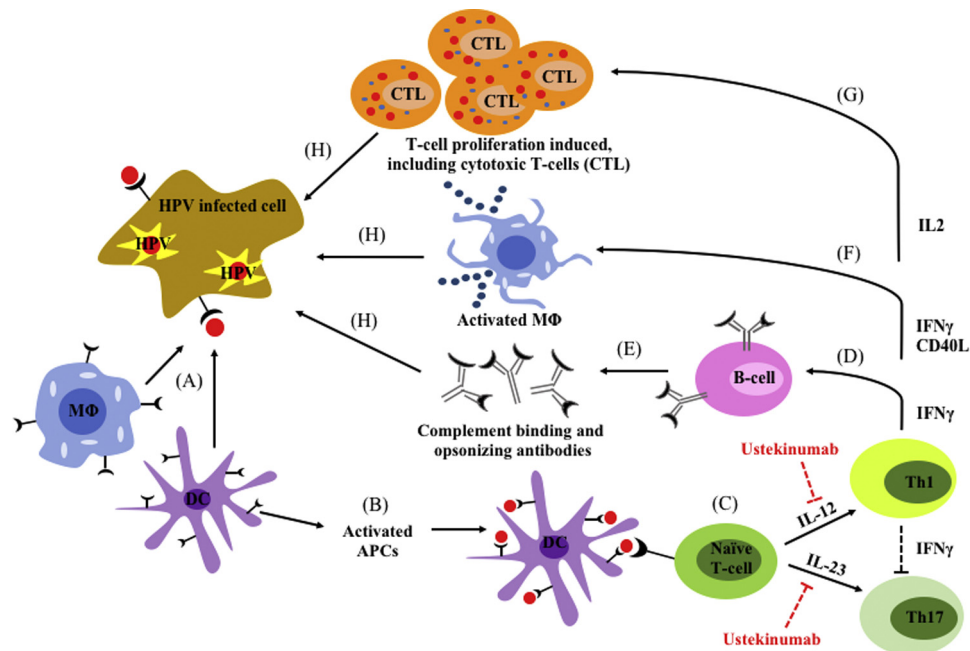


Fig 2. Schematic representation of the intersection between HPV infection and IL-12/IL-23 pathway. (A) Cell-mediated clearance of virally infected cells begins with APCs encountering viral antigen. (B) APCs engulf antigen and present to immature naïve T cells via MHC class I molecules. (C) T cells are activated by IL-12 and IL-23 cytokines and differentiate into Th1 and Th17 cells. Th1 cells (D) stimulate proliferation of B cells capable of (E) producing opsonizing antibodies, (F) activating macrophages, and (G) stimulating proliferation of cytotoxic T cells. (H) Cytotoxic T cells, activated macrophages, and opsonizing antibodies work together to recognize and eliminate virally infected epithelial cells.

response may lead to persistent infection and HPV-related neoplasias.⁷ Studies in mouse models suggest that immune responses to HPV vaccination are mediated by the secretion of the Th1 cytokines IFN- γ and IL-2.⁸ Further supporting this theory, one group found that clearance of HPV⁺ status in 7 patients was accompanied by a Th1 cellular pattern at the time of clearance.⁹ Another group found decreased IFN- γ mRNA expression correlated to development of cervical cancer in HPV⁺ patients.¹⁰ We hypothesize that blockade of the IL-12/IL-23 pathway by ustekinumab could decrease Th1 response, lower levels of IFN- γ and IL-2, and weaken the patient's ability to fight off HPV infection (Fig 2).

Disseminated verrucae have been described with several biological therapies,³ but it has not been a documented adverse reaction to ustekinumab therapy. Mounting clinical evidence in the context of in vitro studies and animal data and case reports like this one call attention to the immunosuppressive properties of biological agents. Careful evaluation for infection and malignancy before initiating biologic therapies and surveys following treatment with the IL-12/23 pathway inhibitors should be considered. Although relatively few immunosuppressive issues

have been noted with anti-IL-12/23 agents in the short term, their long-term safety remains to be determined through continued surveillance.

REFERENCES

- Griffiths CE, Strober BE, van de Kerkhof P, et al, ACCEPT Study Group. Comparison of ustekinumab and etanercept for moderate-to-severe psoriasis. *N Engl J Med*. 2010;362(2):118-128.
- Galloway JB, Hyrich KL, Mercer LK, et al, BSRBR Control Centre Consortium; British Society for Rheumatology Biologics Register. Anti-TNF therapy is associated with an increased risk of serious infections in patients with rheumatoid arthritis especially in the first 6 months of treatment: updated results from the British Society for Rheumatology Biologics Register with special emphasis on risks in the elderly. *Rheumatology (Oxford)*. 2011;50(1):124-131.
- Koc E, Tunca M, Arda E, et al. Multiple widespread warts due to etanercept treatment in a psoriatic patient: a case report. *J Turk Acad Dermatol*. 2008;2(1):82103c.
- Leonardi CL, Kimball AB, Papp KA, et al. Efficacy and safety of Ustekinumab, a human interleukin-12/23 monoclonal antibody, in patients with psoriasis: 76-week results from a randomised, double-blind, placebo-controlled trial (PHOENIX 1). *Lancet*. 2008;371:1665-1674.
- Papp KA, Griffiths CE, Gordon K, et al, PHOENIX 1 Investigators; PHOENIX 2 Investigators; ACCEPT Investigators. Long-term safety of ustekinumab in patients with moderate-to-severe psoriasis: final results from 5 years of follow-up. *Br J Dermatol*. 2013;168(4):844-854.

6. Torti DC, Feldman SR. Interleukin-12, interleukin-23, and psoriasis: current prospects. *J Am Acad Dermatol.* 2007;57:1059-1068.
7. Scott M, Nakagawa M, Moscicki A-B. Cell-mediated immune response to human papillomavirus infection. *Clin Diagn Lab Immunol.* 2001;8(2):209-220.
8. Dupuy C, Buzoni-Gatel D, Touze A, Le Cann P, Bout D, Coursaget P. Cell mediated immunity induced in mice by HPV 16 L1 virus-like particles. *Microb Pathog.* 1997;22:219-225.
9. Scott M, Stites DP, Moscicki AB. Th1 cytokine patterns in cervical human papillomavirus infection. *Clin Diagn Lab Immunol.* 1999;6:751-755.
10. Pao CC, Lin CY, Yao DS, Tseng CJ. Differential expression of cytokine genes in cervical cancer tissues. *Biochem Biophys Res Commun.* 1995;214:1146-1151.