

CASE REPORT

Complex Odontoma at an Unusual Site in a Child: A Case Report

Haseeb Ahammed¹, Thakur Seema², Jayam Cheranjevi³

ABSTRACT

Odontomas are known as the most common odontogenic tumor and usually present without clinical symptoms. It can be divided into compound odontoma and complex odontoma. Compound odontomas are calcified tissue and they bear similarity to the teeth, whereas complex odontomas do not show similarity to the tooth. Diagnosis of the odontomas is usually accidental on radiographic examination. Complex odontomas are commonly seen in the posterior mandible. Apart from the few case reports regarding the complex odontoma of the anterior mandibular region, reported occurrence in this site is rare. Here, authors described a case of a child who presented with a chief complaint of swelling in the anterior mandibular canine region. After clinical examination and required investigations, provisionally, it was diagnosed as complex odontoma. It was surgically removed and histopathological examination confirmed the provisional diagnosis.

Keywords: Complex odontoma, Radiograph, Surgical removal.

International Journal of Clinical Pediatric Dentistry (2021): 10.5005/jp-journals-10005-1950

BACKGROUND

Odontoma is considered as hamartomatous malformation formed by the overgrowth of dental tissue or transitory of complete dental tissue.¹ It is usually asymptomatic and generally associated with unerupted or impacted teeth. However, it can be seen in association with retained deciduous teeth also.² Based on the microscopic and radiographic features, it is broadly divided into compound odontoma and complex odontoma. Morphologically and anatomically, compound odontoma is a tooth-like structure whereas complex odontoma does not show any similarity to the tooth.^{3,4} Odontoma is the most common odontogenic tumor of benign origin and usually present in the posterior mandible.⁵ Due to the absence of symptoms, these are diagnosed usually on the routine radiograph.⁶ Rarely, it shows symptoms like an expansion of the cortical plate, displacement of the adjacent tooth.⁷ In this article, a case of odontoma in the anterior mandibular canine region is discussed, which was symptomatic. Surgical removal opted as the treatment of choice.

CASE DESCRIPTION

A 5-year-old male child reported in the department of pedodontics and preventive dentistry with a chief complaint of swelling in the anterior mandibular region. The parent gave the history that the swelling was initially small in size and increased in size gradually over some time. He had no history of pain and discomfort. On clinical examination, a well-defined circumscribed swelling in the right buccal region with missing 83 (Fig. 1). However, no discharge was inspected. On palpation, the swelling was non-tender and hard in consistency, and expansion of the cortical plate also present. The patient was advised to take an intraoral periapical radiograph, occlusal, and panoramic radiograph. On the radiographs, it appeared as multiple dense radio-opaque structures contained in a radiolucent cavity surrounded by a corticated border (Figs 2 to 4). Inferior to that, a radio-opaque structure 83 was noted and 43 was also present apically to the 83. On the occlusal

¹⁻³Department of Pedodontics and Preventive Dentistry, HP Government Dental College and Hospital, Shimla, Himachal Pradesh, India

Corresponding Author: Thakur Seema, Department of Pedodontics and Preventive Dentistry, HP Government Dental College and Hospital, Shimla, Himachal Pradesh, India, Phone: +91 9418470915, e-mail: cima2009@hotmail.com

How to cite this article: Ahammed H, Seema T, Cheranjevi J. Complex Odontoma at an Unusual Site in a Child: A Case Report. *Int J Clin Pediatr Dent* 2021;14(3):438–440.

Source of support: Nil

Conflict of interest: None

radiograph expansion of the cortical plate was evident (Fig. 4). Based on the clinical and radiographic findings, it was provisionally diagnosed as complex odontoma. Differential diagnoses of this condition included odontoma, dentinoma, osteoblastic stage cementoblastoma and odonto-ameloblastoma, ameloblastic fibro-odontoma, ameloblastic fibroma.

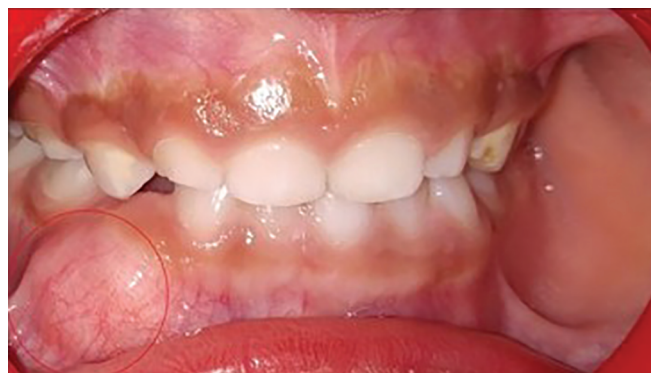

Fig. 1: Swelling on the labial gingiva of 83 region

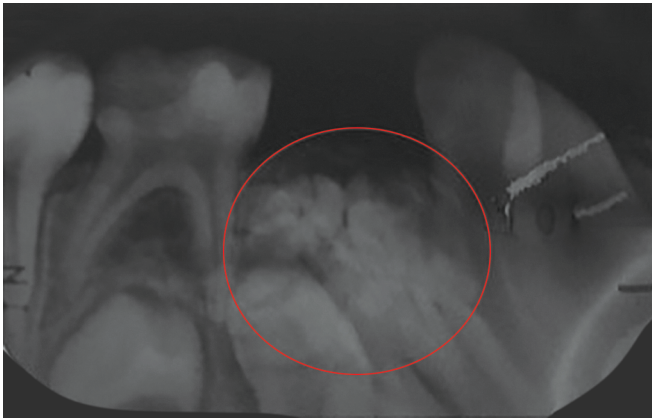

Fig. 2: IOPA showing radiopaque masses in the 83 region

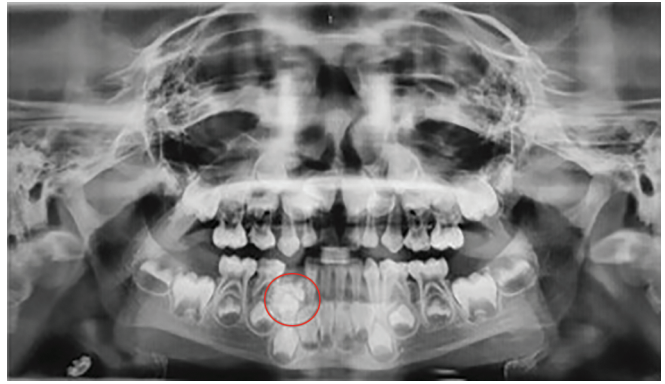


Fig. 3: OPG

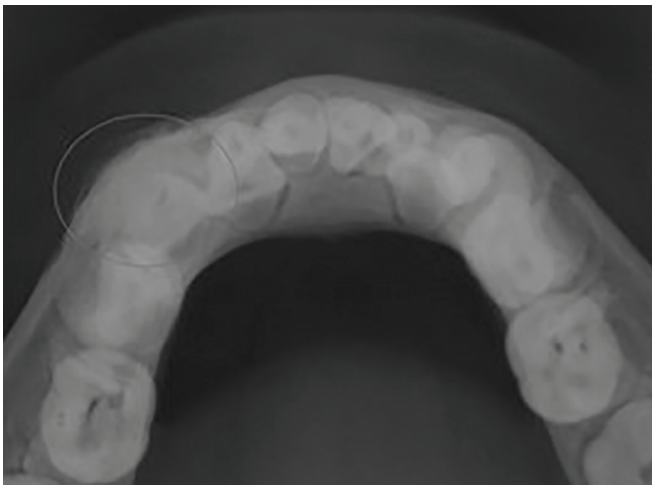


Fig. 4: Mandibular occlusal radiograph showing radiopaque mass in the 83 region

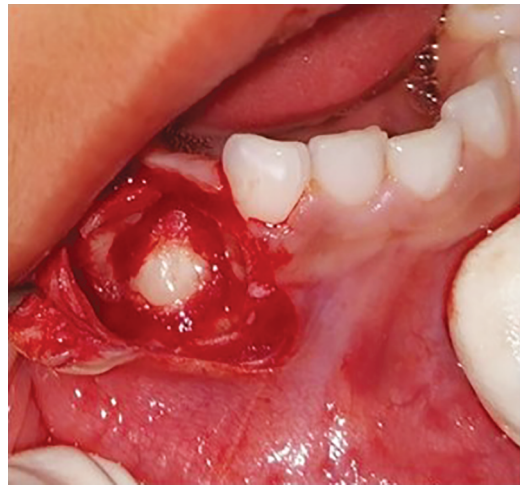

Fig. 5: Surgical site after removal of odontomes

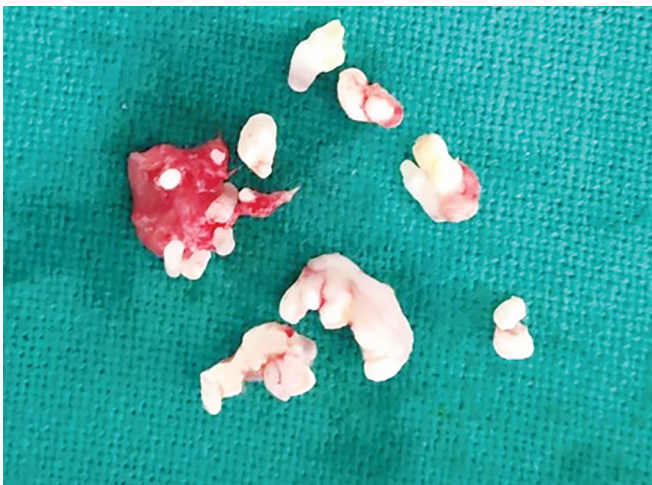

Fig. 6: Removed odontomes

MANAGEMENT

Treatment of choice was complete enucleation of the odontoma and associated soft tissue. Required investigations were obtained and the procedure was started. After administration of adequate local anesthesia crevicular and vertical releasing incision, a full-thickness mucoperiosteal flap is reflected to visualize the area.

After selective removal of the bone, multiple white denticles like structures were visible. All these structures were removed and the mucoperiosteal flap was repositioned (Figs 5 and 6). A suture was placed and prescribed suitable antibiotics and analgesics for 5 days and recalled after 1 week for suture removal. Available sample sends for the histopathological examination and later confirmed as odontoma.

The healing of the surgical site was uneventful. A periodic follow-up was planned.

DISCUSSION

Odontomes are raised due to the growth of both epithelial and mesenchymal components of dental lamina remnants.⁸ These are inherited through postnatal mutant gene interference that controls tooth development.⁹ Satish observed that 22% of all the odontogenic tumors are odontomas.¹⁰ The incidence of compound odontoma ranges between 9% and 37% and that of complex odontoma between 5% and 30%, respectively.¹¹

Odontoma is usually observed in the second and third decades of life rarely in the first decades of life too.⁸ In the presented case, the patient was in the first decades of life.

A common occurrence of the complex odontoma is the posterior mandible and usually asymptomatic. Only in few cases, swelling and delayed eruption were reported.⁵ In this case, it formed in the anterior mandibular canine region with swelling and

it hindered the eruption of the primary canine as it is inferior to the odontome. Giant complex odontoma in the anterior mandible was presented by Spini et al. and Gill and Yadav also discussed complex odontoma associated with mandibular incisor tooth.^{12,13} Gauging the literature, the presentation of complex odontoma in the canine region was rarely noted.

Complex odontomes are appeared as irregular radiopaque masses with no resemble the dental structure. Initially, the lesion appears as a radiolucent lesion due to lack of calcification, in the intermediate stage partial calcification will occur and it appreciates on the radiograph as a mixed lesion and in the final stage, it appears as a radio-opaque surrounded by a radiolucent halo.¹⁴

Histopathological examination is usually used for the confirmation of the odontome. Histopathologically, complex odontomas are composed of a mixture of dental tissues, mainly forming a single homogeneous mass of immature dentin, enamel, enamel matrix, cement, and pulp tissue in a random fashion.¹⁵ A connective tissue capsule similar to the dental follicle is usually associated with it.¹⁶

In earlier days, odontoma was considered as odontogenic tumor and treated with radicular resection of the affected area. Now the concepts about odontoma have changed, and it is considered as hamartomatous malformation. Selective removal of the denticles and associated connective tissue capsule is the preferred treatment option for the odontome.¹⁷

It is important to do the proper diagnosis and timely management of the odontomes to reduce the complication like delayed or failure of eruption and bone abnormalities.

REFERENCES

1. Yadav M, Godge P, Meghana SM, et al. Compound odontoma. *Contemp Clin Dent* 2012;3(Suppl 1):S13–S15. DOI: 10.4103/0976-237X.95095.
2. Neville BW, Damm DD, Allen CM, et al. *Oral and maxillofacial pathology. Odontogenic Cysts and Tumours*. 2nd ed., Saunders; 2004. pp. 631–632. ISBN 978-81-312-1570-8.
3. Lehman H, Lustmann J, Regev E. Removal of an extensive mandibular odontoma using an intraoral approach. *Quintess Int* 2013;44(6): 425–428. DOI: 10.3290/j.qi.a29181.
4. Kaneko M, Fukuda M, Sano T, et al. Microradiographic and microscopic investigation of a rare case of complex odontoma. *Oral Surg, Oral Med, Oral Pathology, Oral Radiol, Endodont* 1998;86(1):131–134. DOI: 10.1016/s1079-2104(98)90163-9.
5. Hidalgo-Sanchez O, Leco-Berrocal MI, Martinez-Gonzalez JM. Meta-analysis of the epidemiology and clinical manifestations of odontomas. *Med Oral Patol Oral Cir Bucal* 2008;13(11): E730–E734.
6. Perumal CJ, Mohamed A, Singh A, et al. Sequestering giant complex odontoma: a case report and review of the literature. *J Maxillofac Oral Surg* 2013;12(4):480–484. DOI: 10.1007/s12663-010-0148-y.
7. Isler SC, Demircan S, Soluk M, et al. Radiologic evaluation of an unusually sized complex odontoma involving the maxillary sinus by cone beam computed tomography. *Quintess Int* 2009;40(7): 533–535.
8. Singh S. Management of unerupted central incisor due to compound odontoma: a case report. *Int J Oral Maxillofac Pathol* 2012;3: 45–48.
9. Papagerakis P, Peuchmaur M, Hotton D, et al. Aberrant gene expression in epithelial cells of mixed odontogenic tumors. *J Dent Res* 1999;78(1):20–30. DOI: 10.1177/00220345990780010201.
10. Satish V. Odontome: a brief overview. *Int J Clin Pediatr Dent* 2011;4(3):177–185. DOI: 10.5005/jp-journals-10005-1106.
11. Kramer IR. WHO International histological classification of tumours. Histological typing of odontogenic tumour. 2nd ed., Berlin: Springer; 1992. pp. 16–21.
12. Spini PHR, Spini TH, Servato JPS, et al. Giant complex odontoma of the anterior mandible: report of case with long follow up. *Brazil Dent J* 2012;2(5):5. DOI: 10.1590/S0103-64402012000500022.
13. Gill NC, Yadav R. A rare case of complex odontoma associated with root of an erupted mandibular primary incisor. *Indian J Oral Sci* 2014;5(2):95–100. DOI: 10.4103/0976-6944.136854.
14. Shekar SE, Roopa SR, Gunasheela B, et al. Erupted compound odontoma. *J Oral Maxillofac Pathol* 2009;13(1):47–50. DOI: 10.4103/0973-029X.48758.
15. Schwass DR, Swain MV, Purton DG, et al. A system of calibrating microtomography for use in caries research. *Caries Res* 2009;43(4): 314–321. DOI: 10.1159/000226230.
16. Cohen DM, Bhattacharyya I. Ameloblastic fibroma, ameloblastic fibro-odontoma, and odontoma. *Oral Maxillofacial Surg Clin N Am* 2004;6(3):375–384. DOI: 10.1016/j.coms.2004.03.005.
17. Syed MR. Bilateral complex odontomas in mandible. *J Oral Maxillofac Pathol* 2006;10:89–91.