

## [ Orthopaedics ]

# Partial Tendon Release for Treatment of a Symptomatic Snapping Biceps Femoris Tendon: A Case Report

Scott A. Crow, MD,\* Tony Quach, MD, and David R. McAllister, MD

Snapping of the biceps femoris tendon over the fibular head is an uncommon condition. Reported causes include an anomalous insertion of the tendon, trauma at the insertion site of the tendon, and an abnormality of the fibular head. This article reports a case of a painful snapping biceps femoris tendon in a patient without an anomalous tendon insertion or an abnormality of the fibular head. Partial release of the superior aspect of the tendon resulted in resolution of symptoms.

**Keywords:** biceps femoris tendon; snapping knee

Snapping of the biceps femoris tendon over the fibular head is an uncommon condition. Reported causes include an anomalous insertion of the tendon,<sup>12,16,18</sup> trauma at the insertion site of the tendon,<sup>4</sup> and an abnormality of the fibular head.<sup>11</sup> Here we report a case of a painful snapping biceps femoris tendon in a patient without an anomalous tendon insertion or an abnormality of the fibular head. Partial release of the superior aspect of the tendon resulted in resolution of symptoms.

## CASE REPORT

A 49-year-old man who was an avid hiker was referred to our office, complaining of snapping and pain at the lateral aspect of his left knee for 1 year. He denied any history of trauma or injury but did report a gradual onset of symptoms, which interfered with his daily activities. He could reproduce the painful snapping with a squatting maneuver, with his left knee and hip both flexed. Conservative treatments, including ice, anti-inflammatory medications, and physical therapy, had been tried but were ineffective in providing relief, and his pain progressed over the year, before presentation. His contralateral knee was asymptomatic.

Physical examination revealed symmetric range of motion from 0° to 135°. Findings based on the ligamentous exam were normal. There was no posterolateral knee or proximal tibiofemoral joint instability. An audible and palpable click was noted over the biceps femoris insertion onto the fibula head during McMurray's test as the knee was extended from a flexed

and internally rotated position. The remainder of the knee examination, as well as that of the contralateral knee, revealed no abnormal results. Anteroposterior and lateral radiographs (Figures 1A and 1B) and MRI yielded normal findings. Since nonoperative treatment failed to resolve his symptoms, operative exploration was performed.

A 3-cm longitudinal incision was made over the lateral aspect of the knee. The dissection was carried to the biceps femoris fascia. The peroneal nerve and popliteus tendon were not exposed. There was no fraying, thickening, or inflammation at the insertion of the biceps tendon. There were no abnormal bony prominences noted at the fibular head. At this time, McMurray's maneuver was performed, and the visualized biceps tendon was found to sublux over the proximal posterior fibular styloid at approximately 110° of knee flexion. Only the superior portion of the tendon was subluxating. Thus, this portion of the tendon was released at the fibular head, which was less than 50% of the entire insertion. No tissue was excised. The knee was examined again with McMurray's maneuver after the partial release, and no snapping of the biceps tendon was noted. The remainder of the biceps tendon was left intact. The patient was placed in a soft dressing, was allowed to bear weight as tolerated, and was started on physical therapy for range of motion, 2 weeks postoperatively. He did not report any other instances of snapping or pain. At 7 months postoperatively, the patient had no further pain, snapping, or other complaints. In addition, he had no detectable hamstring weakness or palpable defect at the biceps femoris tendon.

From the Department of Orthopaedic Surgery, University of California, Los Angeles, California

\*Address correspondence to Scott A. Crow, UCLA Department of Orthopaedic Surgery, CHS, Box 956902, Los Angeles, CA 90095-6902 (e-mail: scrow@mednet.ucla.edu).

No potential conflict of interest declared.

DOI: 10.1177/1941738109338360

© 2009 The Author(s)

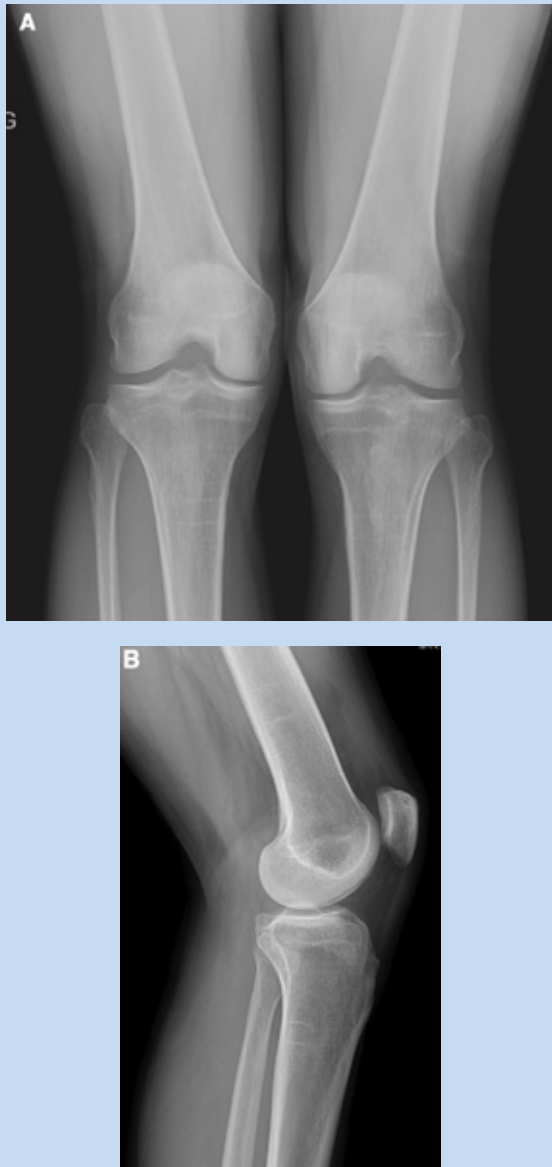


Figure 1. A, preoperative bilateral knee flexion weightbearing radiograph, revealing no osseous abnormalities; B, preoperative lateral knee radiograph, revealing no osseous abnormalities.

## DISCUSSION

Joint snapping is well described in the orthopaedic literature, often occurring at the hip, shoulder, and elbow. Snapping about the knee is also common. It can arise from meniscal tears, a discoid lateral meniscus,<sup>8,24</sup> synovial plicae,<sup>9</sup> iliotibial band friction syndrome,<sup>14</sup> an intra-articular mass,<sup>17,21,23</sup> proximal tibiofibular instability,<sup>22</sup> and congenital snapping knee.<sup>10</sup> Tendons implicated as causes of a snapping knee include the popliteus tendon,<sup>6,7,15,20</sup> the semitendinosus<sup>19</sup> and gracilis,<sup>2,5,13</sup> and the biceps femoris.<sup>1,3,4,12,16,18</sup>

Few reports describe the cause and surgical treatment for a snapping biceps femoris tendon. All reported cases of snapping identify either an anomalous tendon insertion or a prominent fibular head. Hernandez et al<sup>12</sup> described an atypical tendon insertion on the proximal tibia that was released; they reattached it to its anatomic insertion on the fibular head through a drill hole and then sutured the tendon to bone and periosteum. Bansal et al<sup>4</sup> described a case of posttraumatic snapping of the biceps femoris tendon following a soccer injury, which was treated in a similar manner. Lokiec et al described an abnormal tendon insertion and a technique of releasing and repositioning only the irregular part of the tendon to its correct insertion.<sup>18</sup> Bagchi and Grelsamer<sup>3</sup> and Kristensen et al<sup>16</sup> reported cases of an anomalous biceps femoris insertion treated with partial fibula head resection. Bach and Minihane<sup>1</sup> reported a case of snapping biceps femoris tendon with a normal insertion caused by a prominent fibular head that was treated with a partial fibula head resection. In contrast to other reports of a snapping biceps femoris tendon, this case did not involve altered anatomy of the proximal fibula or the insertion of the distal tendon. The patient's diagnosis was based primarily on the physical examination. Imaging studies did not reveal any abnormality; however, they did exclude other possible sources of the patient's symptoms. The diagnosis was confirmed in the operating room, where visualization and palpation of the tendon was performed, as was reproduction of the snapping with a McMurray's-type maneuver. Under direct visualization, only the superior portion of the tendon was noted to subluxate across the fibular styloid region with deep knee flexion. Release that was limited to this portion of the biceps femoris insertion eliminated the snapping.

Surgical treatment involving reattachment of the biceps femoris tendon requires cast immobilization for 4 to 6 weeks and often delayed weightbearing.<sup>4,12,18</sup> Releasing only part of the tendon expedited the patient's recovery by enabling immediate weightbearing and early range of motion.

In previous reports of nontraumatic snapping biceps femoris tendons, the snapping was usually noted bilaterally. In our case, only one side was symptomatic, which suggests that some intrinsic anatomic abnormality caused the snapping in these other patients. In our patient, there was no anatomic abnormality, but the snapping and the pain could be caused with certain activities involving high amounts of knee flexion. Muscle weakness was an unlikely cause because the condition could be reproduced passively. In addition, the patient had normal strength, he was fairly active, and a year of physical therapy did not provide any relief. We are not sure of the cause of the painful snapping. Because this condition is rare, we do not know the success of nonoperative treatment. There are, however, reports of patients with other tendinous causes of snapping at the knee whose symptoms resolved with conservative care.<sup>6</sup>

In conclusion, a symptomatic snapping biceps femoris tendon is a rare problem, with limited reports in the literature. In cases where the patient fails conservative treatment, surgery may be required. Partial release of the superior aspect of the tendon

appears to be an effective treatment that can result in the resolution of symptoms, provided there are no alterations to the normal anatomy of the proximal fibula or distal biceps femoris tendon attachment.

## REFERENCES

- Bach BR Jr, Minihane K. Subluxating biceps femoris tendon: an unusual case of lateral knee pain in a soccer athlete: a case report. *Am J Sports Med.* 2001;29(1):93-95.
- Bae DK, Kwon OS. Snapping knee caused by the gracilis and semitendinosus tendon: a case report. *Bull Hosp Jt Dis.* 1997;56(3):177-179.
- Bagchi K, Grelsamer RP. Partial fibular head resection for bilateral snapping biceps femoris tendon. *Orthopedics.* 2003;26(11):1147-1149.
- Bansal R, Taylor C, Pimpalnerkar AL. Snapping knee: an unusual biceps femoris tendon injury. *Knee.* 2005;12(6):458-460.
- Bollen SR, Arvinte D. Snapping pes syndrome: a report of four cases. *J Bone Joint Surg Br.* 2008;90(3):334-335.
- Cooper DE. Snapping popliteus tendon syndrome: a cause of mechanical knee popping in athletes. *Am J Sports Med.* 1999;27(5):671-674.
- Crites BM, Lohnes J, Garrett WE Jr. Snapping popliteal tendon as a source of lateral knee pain. *Scand J Med Sci Sports.* 1998;8(4):243-244.
- Dickhaut SC, DeLee JC. The discoid lateral-meniscus syndrome. *J Bone Joint Surg Am.* 1982;64(7):1068-1073.
- Dupont JY. Synovial plicae of the knee: controversies and review. *Clin Sports Med.* 1997;16(1):87-122.
- Ferris BD, Jackson AM. Congenital snapping knee: habitual anterior subluxation of the tibia in extension. *J Bone Joint Surg Br.* 1990;72(3):453-456.
- Fung DA, Frey S, Markbreiter L. Bilateral symptomatic snapping biceps femoris tendon due to fibular exostosis. *J Knee Surg.* 2008;21(1):55-57.
- Hernandez JA, Rius M, Noonan KJ. Snapping knee from anomalous biceps femoris tendon insertion: a case report. *Iowa Orthop J.* 1996;16:161-163.
- Karataglis D, Papadopoulos P, Fotiadou A, et al. Snapping knee syndrome in an athlete caused by the semitendinosus and gracilis tendons: a case report. *Knee.* 2008;15(2):151-154.
- Kirk KL, Kuklo T, Klemme W. Iliotibial band friction syndrome. *Orthopedics.* 2000;23(11):1209-1214.
- Krause DA, Stuart MJ. Snapping popliteus tendon in a 21-year-old female. *J Orthop Sports Phys Ther.* 2008;38(4):191-195.
- Kristensen G, Nielsen K, Blyme PJ. Snapping knee from biceps femoris tendon: a case report. *Acta Orthop Scand.* 1989;60(5):621.
- Liu PC, Chen CH, Huang HT, et al. Snapping knee symptoms caused by an intra-articular ganglion cyst. *Knee.* 2007;14(2):167-168.
- Lokiec F, Velkes S, Schindler A, et al. The snapping biceps femoris syndrome. *Clin Orthop Relat Res.* 1992;283:205-206.
- Lyu SR, Wu JJ. Snapping syndrome caused by the semitendinosus tendon: a case report. *J Bone Joint Surg Am.* 1989;71(2):303-305.
- McAllister DR, Parker RD. Bilateral subluxating popliteus tendons: a case report. *Am J Sports Med.* 1999;27(3):376-379.
- Mine T, Ihara K, Taguchi T, et al. Snapping knee caused by intra-articular tumors. *Arthroscopy.* 2003;19(3):E21.
- Pressel T, Wirth CJ. Chronic symptomatic proximal tibiofibular instability in a 3-year-old girl. *Knee.* 2006;13(3):244-246.
- Toritsu T, Yosida S, Takasita M. Painful snapping in rheumatoid knees. *Int Orthop.* 1997;21(6):361-363.
- Youm T, Chen AL. Discoid lateral meniscus: evaluation and treatment. *Am J Orthop.* 2004;33(5):234-238.

For reprints and permissions queries, please visit SAGE's Web site at <http://www.sagepub.com/journalsPermissions.nav>.