

Posterior scleritis after biweekly aflibercept intravitreal injections

Mélanie Hébert, Eunice You, Jean-François Gravel, Ali Dirani, Serge Bourgault*

Department of Ophthalmology, Centre Hospitalier Universitaire de Québec – Université Laval, 1050 Chemin Ste-Foy, Québec, QC, G1S 4L8, Canada

ARTICLE INFO

Keywords:

Posterior scleritis
Intravitreal injections
Anti-vascular endothelial growth factors
Complications

ABSTRACT

Purpose: To describe a case of posterior scleritis following anti-vascular endothelial growth factor (VEGF) injection.

Observations: A 51-year-old male receiving biweekly anti-VEGF injections for a central retinal vein occlusion complicated with cystoid macular edema presented with new-onset severe pain, photophobia, and tearing. Ophthalmological examination revealed choroidal folds and B-scan ultrasound confirmed significant thickening of the sclera, leading to a diagnosis of posterior scleritis. This resolved under topical and systemic corticosteroids.

Conclusions and importance: Intravitreal anti-VEGF injections could be associated with non-infectious posterior scleritis. Clinicians should be particularly aware of this possibility in patients receiving frequent injections.

1. Introduction

Posterior scleritis is a sight-threatening complication which can rarely occur following intraocular interventions.^{1,2} It is characterized by severe ocular pain and should be treated using corticosteroids or immunosuppressive agents. However, this has not yet been described as a complication following intravitreal injections. We describe a case of a patient receiving biweekly intravitreal injections of aflibercept who subsequently developed posterior scleritis.

2. Case report

A 51-year-old male with no past medical or surgical history was followed regularly for the past 9 years following central retinal vein occlusion (CRVO) in the left eye (OS). This was complicated by cystoid macular edema (CME) and required regular intravitreal anti-vascular endothelial growth factor (VEGF) injections. All injections were performed under topical anesthesia in a standard fashion with a 30G needle 4 mm behind the limbus in the inferotemporal quadrant. The patient was also prescribed a brimonidine tartrate/timolol maleate ophthalmic solution twice daily OS for intraocular pressure (IOP) control. Past ocular history was otherwise insignificant. Family history was significant for glaucoma. Workup for CRVO done at the time of diagnosis only revealed that the patient was heterozygous for factor V Leiden.

Baseline visual acuity (VA) was 6/6 OS and maximum IOP was 21

mmHg OS during his follow-up. For the first 4 years of treatments, bevacizumab was injected every 4–6 weeks. The patient often experienced self-resolving pain and ocular redness starting a few days after his injections. Six weeks after his 39th bevacizumab injection, the patient had an increase in CME with a 142 μm increase in central retinal thickness compared to the previous optical coherence tomography (OCT) and VA dropping from 6/6 to 6/15-2. A switch to aflibercept was therefore attempted to decrease injection frequency. The patient no longer experienced pain and ocular redness after the switch. Despite a good initial control of the CME, the interval between injections progressively shortened over the next 5 years until the patient required injections every 2 weeks to maintain CME control. The worst VA recorded under this regimen was 6/18-2 OS.

On the third day following his 47th aflibercept injection, the patient experienced sudden photophobia and tearing with a severe, profound pain, for which he immediately sought medical attention. Corrected VA was 6/120 OS, not improvable with pinhole, and IOP was 14 mmHg OS. Slit lamp examination revealed ciliary flush, a clear fluorescein-negative cornea, 2+ cells and 1+ flare in the anterior chamber without hypopyon or fibrin. Dilated fundus examination revealed 1+ vitreous cells without haze. Tortuous veins and CME were also observed. The patient was immediately referred to the retina service. Significant posterior choroidal folds were then noted (Fig. 1A) and confirmed by OCT (Fig. 1B). Choroidal folds were never observed on previous OCTs. These findings prompted a B-scan ultrasound that showed significant

* Corresponding author. Département d'ophtalmologie et d'oto-rhino-Laryngologie–Chirurgie Cervico-Faciale, Université Laval, Centre Universitaire d'ophtalmologie, Hôpital du Saint-Sacrement, CHU de Québec, 1050 Ch Ste-Foy, Québec, G1S 4L8, Canada.

E-mail addresses: melanie.hebert.3@ulaval.ca (M. Hébert), eunice.you.1@ulaval.ca (E. You), jean-francois.gravel.1@ulaval.ca (J.-F. Gravel), ali.dirani@fmed.ulaval.ca (A. Dirani), serge.bourgault.1@ulaval.ca (S. Bourgault).

<https://doi.org/10.1016/j.ajoc.2022.101696>

Received 2 December 2021; Received in revised form 31 July 2022; Accepted 1 September 2022

Available online 6 September 2022

2451-9936/© 2022 The Authors. Published by Elsevier Inc. This is an open access article under the CC BY-NC-ND license (<http://creativecommons.org/licenses/by-nc-nd/4.0/>).

thickening of the sclera (Fig. 1C). The patient was diagnosed with posterior scleritis and treated initially with prednisone 50 mg daily and hourly topical difluprednate. The treatment was slowly tapered over 12 days for prednisone and 2 months for difluprednate with gradual reduction of the scleral thickness and improvement of the choroidal folds (Fig. 2). Three weeks after his last aflibercept injection, CME recurred with a central retinal thickness of 658 μm . VA was 6/30. Triamcinolone acetonide (Triesence™) 2 mg was injected intravitreally. He received two supplemental triamcinolone acetonide injections for CME recurrence at 12 then 10 weeks intervals.

At final follow-up nearly five months after diagnosis of posterior scleritis, the patient had a corrected VA of 6/18-2 OS, an IOP of 13 mmHg OS, and resolution of CME and choroidal folds on macular OCT without oral or topical corticosteroids.

Workup for scleritis was done and revealed nonspecific speckled (1:160) and homogeneous (1:80) antinuclear antibodies. It was otherwise negative for rheumatoid factor, anti-citrullinated protein antibody, C-reactive protein, erythrocyte sedimentation rate, C3 and C4 complement, antineutrophil cytoplasmic antibodies, treponemal syphilis testing, angiotensin converting enzyme, extractable nuclear antigen (ENA) panel, and anti-double stranded deoxyribonucleic acid (dsDNA) antibodies.

3. Discussion

We describe a case of posterior scleritis occurring three days following a patient's fifth biweekly intravitreal aflibercept injection. Many factors could have contributed to this complication, including repetitive trauma of intravitreal injections and an immunogenic response in a patient with positive antinuclear antibodies. An infectious cause is unlikely considering the favorable response to steroid therapy.

Trauma from repeated intravitreal injections could have been contributive in our case. Recurrent anterior scleritis has been described in a patient with rheumatoid arthritis following each intravitreal injection regardless of injection site.³ While the trauma from subsequent intravitreal injections of triamcinolone acetonide could have caused a recurrence of posterior scleritis, the anti-inflammatory properties of the drug itself may have blunted the process.

Drug-induced scleritis has also been described with topiramate and,

particularly, with bisphosphonates.⁴ Though the mechanism behind drug-induced ocular inflammation is unknown, it is speculated that the resemblance between drug and T-cell ligands may cause an immunologic or toxic reaction manifesting as uveitis or scleritis.⁴ Furthermore, anti-drug antibodies against all commercially available anti-VEGF agents have been described.⁵⁻⁸ The development of neutralising antibodies or a systemic immune response in a process known as pharmacokinetic tolerance has previously been postulated after repeated treatments of bevacizumab and ranibizumab.⁹ A similar phenomenon in this patient requiring increasingly frequent aflibercept injections up to biweekly treatments prior to the scleritis may have occurred.

Finally, posterior scleritis as an entity is often idiopathic in cohort studies, ranging from 62% to 81%.^{10,11} In non-infectious causes of scleritis, autoimmunity might play a role in generating the scleral inflammation,¹² which is possible in our patient with positive antinuclear antibodies titers.

4. Conclusions

We describe herein a case of non-infectious posterior scleritis associated with intravitreal injections which was well treated with standard combined use of systemic and topical steroids. Clinicians should be aware of this complication especially in patients receiving biweekly anti-VEGF injections. Ancillary B-scan testing for posterior scleritis should be prompted by the presence of choroidal folds in patients showing intraocular inflammations after anti-VEGF injections. Treatment of this entity differs from infectious endophthalmitis and relies on immunosuppressive medication.

Funding

No funding or grant support.

Authorship

All authors attest that they meet the current ICMJE criteria for Authorship.

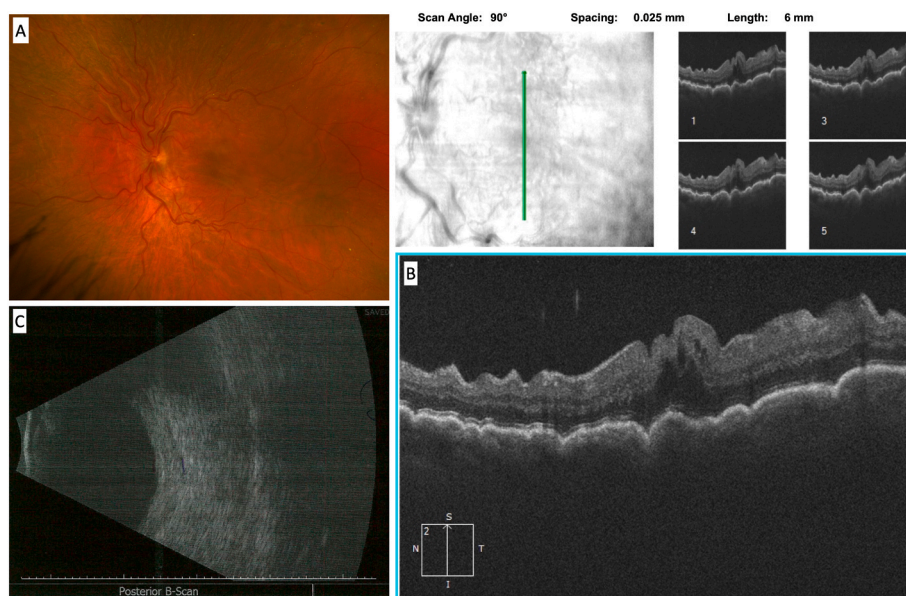


Fig. 1. Left eye imaging at presentation: (A) color fundus photography showing choroidal folds and dilated, tortuous veins; (B) macular optical coherence tomography showing choroidal folds; (C) B-scan ultrasound showing thickening of the posterior sclera. (For interpretation of the references to color in this figure legend, the reader is referred to the Web version of this article.)

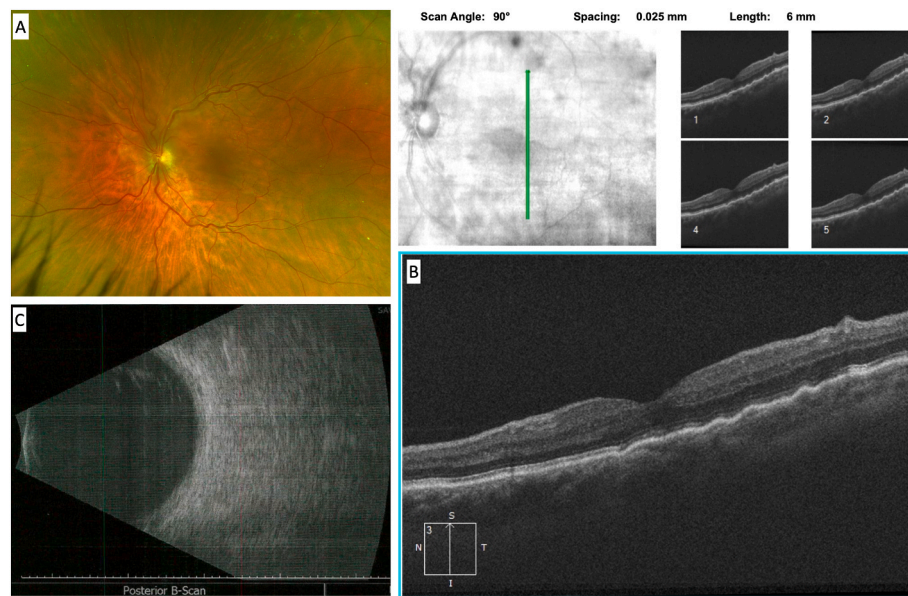


Fig. 2. Left eye imaging at 4 weeks after diagnostic: (A) color fundus photography showing a reduction of choroidal folds (horizontal folds still visible at the macula); (B) macular optical coherence tomography showing an improvement of choroidal folds; (C) B-scan ultrasound showing a reduction in scleral thickness. (For interpretation of the references to color in this figure legend, the reader is referred to the Web version of this article.)

Author contributions

Mélanie Hébert: conceived the work, analyzed the patient data, performed the literature review, and drafted and reviewed the manuscript. Eunice You: conceived the work, analyzed the patient data, performed the literature review, and drafted and reviewed the manuscript. Jean-François Gravel: conceived the work, analyzed the patient data, performed the literature review, and drafted and reviewed the manuscript. Ali Dirani: analyzed the patient data and substantively revised the submitted version. Serge Bourgault conceived the work, performed the literature review, and substantively revised the submitted version. All authors read and approved the final manuscript.

Patient consent

The patient provided written consent to the publication of this case.

Declaration of competing interest

The following authors have no financial disclosures: M.H., E.Y., and J.-F.G. A.D. reports being a member of the advisory board for Novartis and Bayer. S.B. reports being a consultant and member of the advisory board for Novartis and Bayer.

Acknowledgments

None.

References

- O'Donoghue E, Lightman S, Tuft S, Watson P. Surgically induced necrotising sclerokeratitis (SINS)–precipitating factors and response to treatment. *Br J Ophthalmol.* 1992;76(1):17–21.
- Aktas Z, Bektas C, Hasanreisoglu M. Panscleritis as an unusual complication of gonioscopy-assisted transluminal trabeculotomy. *J Glaucoma.* 2019;28(2):e21. <https://doi.org/10.1097/JG.0000000000001100>.
- Ryu SJ, Kang MH, Seong M, Cho H, Shin YU. Anterior scleritis following intravitreal injections in a patient with rheumatoid arthritis: a case report. *Medicine (Baltim).* 2017;96(47), e8925. <https://doi.org/10.1097/MD.0000000000008925>.
- Fraunfelder FW, Fraunfelder FT. Adverse ocular drug reactions recently identified by the national registry of drug-induced ocular side effects. *Ophthalmology.* 2004;111(7):1275–1279. <https://doi.org/10.1016/j.ophtha.2003.12.052>.
- Forooghian F, Chew EY, Meyerle CB, Cukras C, Wong WT. Investigation of the role of neutralizing antibodies against bevacizumab as mediators of tachyphylaxis. *Acta Ophthalmol.* 2011;89(2):e206–e207. <https://doi.org/10.1111/j.1755-3768.2009.01773.x>.
- Novartis Pharmaceuticals Canada Inc. LUCENTIS full prescribing information. Published online November 3, 2017 http://www.ask.novartispharma.ca/download.htm?res=lucentis_scrip_e.pdf&resTitleId=795.
- Regeneron Pharmaceuticals, Inc. EYLEA full prescribing information. Published online June 2021 https://www.regeneron.com/downloads/EYLEA_FPI.pdf.
- Novartis Pharmaceuticals Canada Inc. BEOVU full prescription information. http://www.ask.novartispharma.ca/download.htm?res=beovu_scrip_e.pdf&resTitleId=1648.
- Binder S. Loss of reactivity in intravitreal anti-VEGF therapy: tachyphylaxis or tolerance? *Br J Ophthalmol.* 2012;96(1):1–2. <https://doi.org/10.1136/bjophthalmol-2011-301236>.
- Lavric A, Gonzalez-Lopez JJ, Majumder PD, et al. Posterior scleritis: analysis of epidemiology, clinical factors, and risk of recurrence in a cohort of 114 patients. *Ocul Immunol Inflamm.* 2016;24(1):6–15. <https://doi.org/10.3109/09273948.2015.1005240>.
- Gonzalez-Gonzalez LA, Molina-Prat N, Doctor P, Tauber J, de la Maza MS, Foster CS. Clinical features and presentation of posterior scleritis: a report of 31 cases. *Ocul Immunol Inflamm.* 2014;22(3):203–207. <https://doi.org/10.3109/09273948.2013.840385>.
- Vergouwen DPC, Rothova A, Berge JCT, et al. Current insights in the pathogenesis of scleritis. *Exp Eye Res.* 2020;197, 108078. <https://doi.org/10.1016/j.exer.2020.108078>.