



## Use of esophageal balloon manometry in the management of pediatric acute respiratory distress syndrome

Elena Insley<sup>b,\*</sup>, Chad Pezzano<sup>c,d</sup>, Shashikanth Ambati<sup>a</sup>, Darren Lydon<sup>c</sup>, Don Walker<sup>d</sup>, Suzanne Barry<sup>a</sup>

<sup>a</sup> Department of Pediatric Critical Care, Albany Medical Center, United States

<sup>b</sup> Albany Medical College and Albany Medical Center, United States

<sup>c</sup> Department of Cardio-Respiratory Services, Albany Medical Center, United States

<sup>d</sup> Department of Pediatrics, Albany Medical Center, United States

### ARTICLE INFO

#### Keywords:

Esophageal manometry  
Pediatric acute respiratory distress syndrome  
Acute respiratory distress syndrome  
Esophageal balloon  
Pediatric

### ABSTRACT

There is paucity of literature regarding the use of esophageal balloon manometry in the management of Pediatric Acute Respiratory Distress Syndrome. We describe our first ever experience of successful usage of esophageal balloon pressure manometry in a child with acute respiratory distress syndrome. This is a six-year-old girl who presented with shortness of breath and fever and was found to be in severe acute respiratory distress syndrome due to septic shock secondary to group A streptococcus. The patient was managed using an esophageal balloon manometry for positive end-expiratory pressure titration. She was liberated from invasive mechanical ventilation on day 7 of hospital course. Esophageal balloon manometry guided positive end-expiratory pressure for 103 out of 155 hours of ventilation with no obvious sequelae. Our case shows the feasibility of transpulmonary pressure measurements in pediatric patients. This practice may be useful to optimize management in pediatric acute respiratory distress syndrome to improve outcomes.

### 1. Introduction

Previous pediatric research suggests increasing levels of positive end expiratory pressure (PEEP) are required in Pediatric Acute Respiratory Distress Syndrome (PARDS) and insufficient PEEP/FiO<sub>2</sub> is associated with higher mortality [1]. Optimal PEEP is required to improve oxygenation and minimize repeated alveolar collapse or over distention. However, there is limited evidence on how to optimize PEEP in a patient-specific way leading to substantial variability in titration among pediatric intensivists [2]. Esophageal balloon manometry measures esophageal pressure, this is a surrogate for pleural pressure and allows for calculation of the transpulmonary pressure needed to distend the lung and the chest wall. A randomized controlled trial by Talmor and colleagues [3] in adults compared mechanical ventilation titrated by the esophageal measurements using balloon manometry vs titration by Acute Respiratory Distress Syndrome Network standard-of-care recommendations (low tidal volume strategy and PEEP/FiO<sub>2</sub> charts) and showed that the esophageal pressure guided patients had significantly improved oxygenation with enhanced respiratory-system compliance

resulting in the trend toward improved 28-day survival in the group of very sick patients. Use of an esophageal balloon in PARDS is not well described. We present a case report in which an esophageal balloon was used to optimize mechanical ventilation in a patient with severe PARDS.

### 2. Case

A six-year-old (22.4kg) otherwise healthy girl was admitted to our pediatric intensive care unit (PICU) for acute hypoxic respiratory failure after nine days of febrile illness and two-day history of shortness of breath. She presented to an outside hospital and was transferred to our PICU with acute hypoxic respiratory failure and septic shock secondary to suspected pneumonia. Initial chest radiograph on admission showed diffuse bilateral interstitial opacities consistent with acute respiratory distress syndrome (Fig. 1). The patient was quickly escalated to non-invasive positive pressure ventilation (NIPPV) and required tracheal intubation approximately 6 h after admission. She was continued on empiric broad spectrum antibiotics and sedation was initiated and titrated for patient comfort.

\* Corresponding author.

E-mail address: [insleye@amc.edu](mailto:insleye@amc.edu) (E. Insley).

<https://doi.org/10.1016/j.rmcr.2020.101058>

Received 25 February 2020; Received in revised form 3 April 2020; Accepted 11 April 2020

Available online 12 April 2020

2213-0071/© 2020 The Authors.

Published by Elsevier Ltd.

This is an open access article under the CC BY-NC-ND license

(<http://creativecommons.org/licenses/by-nc-nd/4.0/>).

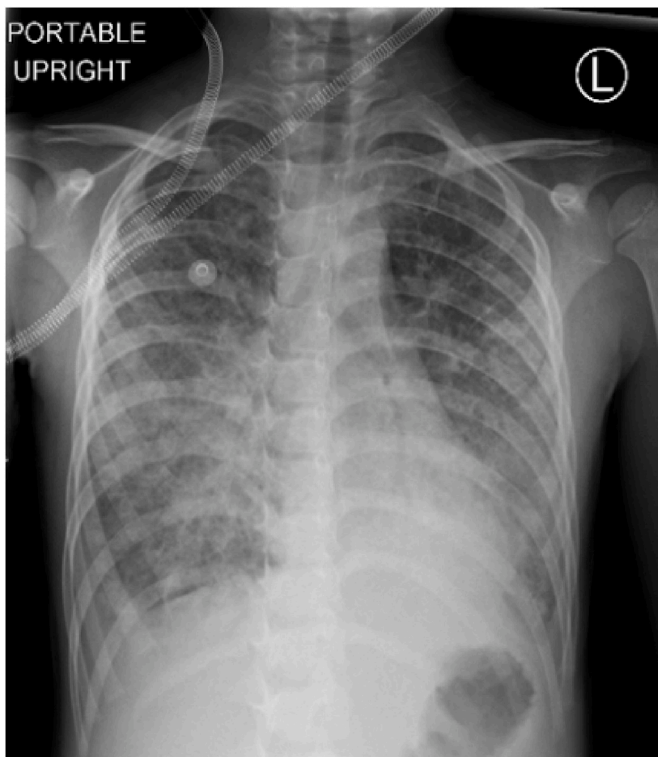


Fig. 1. Chest radiograph on admission.

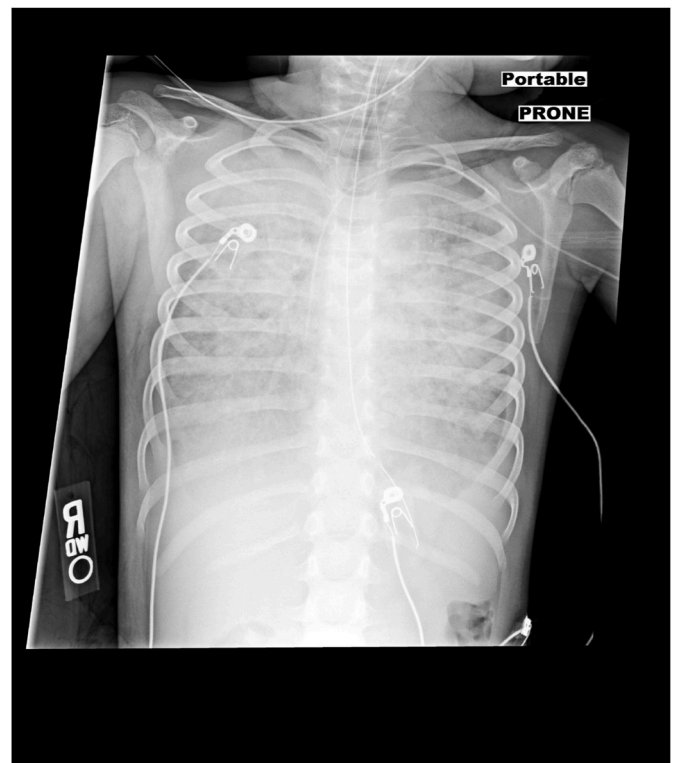


Fig. 2. Bilateral diffuse opacities with decreased lung volumes.

Initial ventilator support was with Pressure Regulated Volume Control (PRVC) on Servo *i* ventilator (Getinge, Solna, Sweden) with initial settings of tidal volume 200ml (8.9ml/kg), respiratory rate of 30, PEEP of 6 cmH<sub>2</sub>O, and FiO<sub>2</sub> 1.0 (mean airway pressure 21 cmH<sub>2</sub>O, peak inspiratory pressure (PIP) 32 cmH<sub>2</sub>O). Initial oxygenation index (OI) was 19.3 and PaO<sub>2</sub>:FiO<sub>2</sub> ratio of 102.3 confirming severe PARDS. Arterial blood gas analysis on FiO<sub>2</sub> 0.85 showed pH 7.27, PaCO<sub>2</sub> 49, PaO<sub>2</sub> 87, and base deficit of 4.8. The patient continued to deteriorate despite prone positioning and paralysis with worsening chest x-ray (Fig. 2). A transthoracic echocardiogram revealed normal function (LV shortening fraction 54.9%) with no signs of pulmonary hypertension, which refrained us from the use of inhaled nitric oxide. Decision was made to place an esophageal balloon catheter using a Hamilton G5 ventilator (Hamilton Medical, Reno, NV) to measure transpulmonary pressure and for optimal titration of PEEP.

A 5 French esophageal balloon (Cooper Surgical, Trumbull, CT) was placed. We estimated the length necessary to place the balloon in the lower third esophagus by measuring the distance between the nostril and the xyphoid. After placement, gentle pressure was applied to the abdomen with corresponding pressure increase supporting esophageal placement. The catheter was then slowly withdrawn until cardiac oscillations were detected on esophageal pressure waveform. Position was confirmed by applying pressure to the thoracic ribcage and observing a corresponding pressure increase. Optimal positioning of the esophageal balloon is also shown in Fig. 3.

Parameters for transpulmonary pressure ( $P_L$ ), defined as pressure gradient between plateau pressure and the esophageal pressure at the end of the inspiration, and expiratory transpulmonary pressure ( $P_{Lexp}$ ), defined as the gradient between the PEEP set on the ventilator and esophageal pressure at the end of expiration, were derived based on previous adult research with a goal of  $P_L \leq 10$  cm H<sub>2</sub>O and  $P_{Lexp}$  of  $0 \pm 2$  [9,10]. Optimization of transpulmonary pressure ( $P_L$ ) and expiratory transpulmonary pressure ( $P_{Lexp}$ ) was accomplished by titration of tidal volume and PEEP respectively. For example. If the  $P_{Lexp}$  was negative, PEEP was increased to reach the goal of 0 to  $\pm 2$  cmH<sub>2</sub>O and if  $P_{Lexp}$

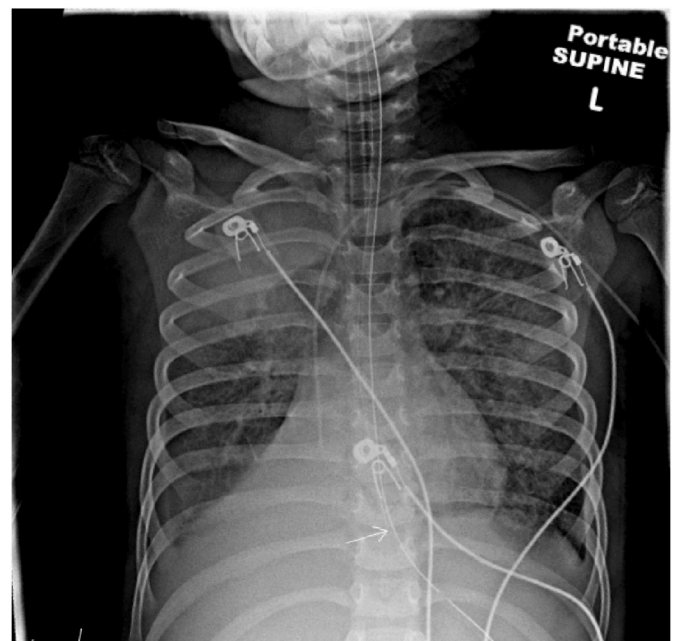


Fig. 3. Distal esophageal balloon large white arrow.

was positive, PEEP was decreased to reach  $0 \pm 2$  cm H<sub>2</sub>O. If  $P_L$  was more than 10 cm H<sub>2</sub>O then the tidal volume is titrated down by 10 ml at a time to achieve the goal of  $P_L < 10$  cm H<sub>2</sub>O. Fig. 4 Depicts the relationship between the  $P_L$  and  $P_{Lexp}$  with time and in respect to patient positioning and notably  $P_L$  is lower in prone position when compared to supine. Titrating the PEEP and tidal volumes using the  $P_L$  and  $P_{Lexp}$  assisted in lung recruitment. As shown in Fig. 5,  $P_{Lexp}$  guided us in achieving the optimal PEEP e.g. Between hours 25–35 as the  $P_{Lexp}$  trended more negative (i.e.  $-6$ ) titrating up the PEEP to achieve the goal

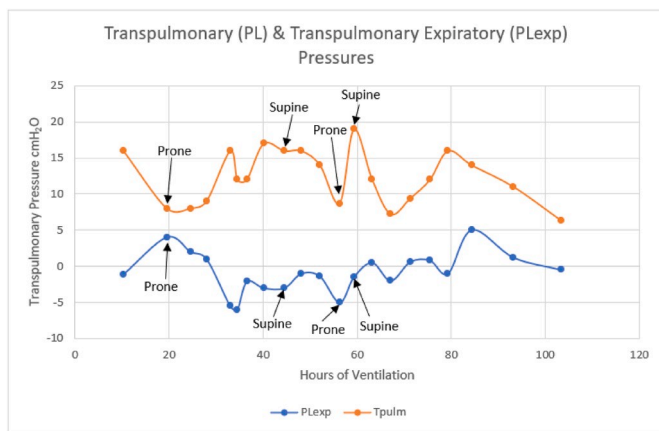


Fig. 4. Trends of PL and PLExp over time in relation to the position of the patient.

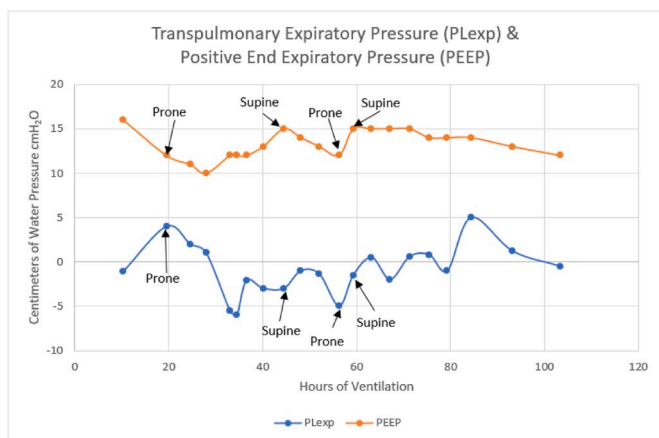


Fig. 5. Trend of PEEP titration in relation to PLExp.

$P_{LExp}$  of  $0 \pm 2$  helped maintain the lung volumes.

On hospital day 3 neuromuscular blockade was discontinued and we began slowly weaning PEEP while continuing to monitor  $P_L$  and  $P_{LExp}$ . The esophageal balloon was removed on hospital day 5 (total 103 hours of monitoring) once she was steadily tolerating weans with stable  $P_{LExp}$ . The patient was extubated successfully on hospital day 7 after 155 hours of invasive mechanical ventilation and ultimately weaned off respiratory support.

### 3. Discussion

Transpulmonary pressure measurement via esophageal balloon is not well described in the pediatric literature. Gleich et al. [4] mentioned in their study that overall, very few pediatric patients are managed with esophageal pressure measurements and so the benefit of transpulmonary pressure monitoring in children with pediatric respiratory distress syndrome is less clear leading to insufficient evidence to recommend or against routine esophageal pressure monitoring. The 2015 PARDS consensus recommendations from the Pediatric Acute Lung Injury Consensus Conference notes that inspiratory plateau pressure ( $P_{plat}$ ) limits for protective lung ventilation are flawed as they do not account for patient specific variation in chest wall elastance based on patient habitus and changes as the disease itself evolves [5]. PARDS particularly poses significant challenges in management due to decreased lung compliance and immature lungs, which are particularly prone to injury [6]. The recommended  $P_{plat}$  limitations may result in overly low transpulmonary pressures and insufficient inflation of the lungs [5]. Given

these issues, real time measurement of transpulmonary pressure is important to guide management of PARDS by ensuring optimal inflation and thus optimizing oxygenation.

Transpulmonary pressure is the true distending pressure of the lungs defined as the difference in pressure between the alveoli and the pleural space [7]. It can be used to titrate settings in a patient specific way to optimize oxygenation and ventilation while minimizing volutrauma, atelectotrauma, and oxygen toxicity. Esophageal manometry measures esophageal pressure, which is used as a surrogate for pleural pressure [8]. Parameters for  $P_L$  and  $P_{LExp}$  were derived based on previous adult research with a goal of  $P_L \leq 10$  cmH<sub>2</sub>O being lung protective and avoidance of levels  $>15$  cmH<sub>2</sub>O to prevent over distention.  $P_{LExp}$  goals of 0 to  $\pm 2$  cmH<sub>2</sub>O correlate to optimal PEEP with more negative values a risk for alveolar collapse and more positive values a risk for over distention [3,9,10].

Our patient's hospital course reflects a challenge in optimizing ventilator settings based on traditional parameters, particularly PEEP, early in the disease process. Following esophageal balloon placement, the patient's clinical course was less variable. With the guidance of transpulmonary pressure measurements we were able to more accurately account for the degree of lung disease and variation in chest wall and lung compliance. Without this data, there may have been less aggressive and less successful optimization of PEEP leading to a more protracted and complicated disease course. The transpulmonary pressure measurement helped us optimize the PEEP in our patient above the comfort of our conventional limits while improving the patient's oxygenation.

This case adds to the growing body of literature describing the efficacy and feasibility of transpulmonary pressure monitoring for the titration of ventilator settings in PARDS [4,11]. There are inherent limitations in our case, given that it is a single patient case report and the challenges with the use of the esophageal balloon for example, maintaining the optimal balloon volume and placement, particularly with position changes, affected accuracy and reliability of measurements as discussed by Hotz [12,13]. In our case, chest X-ray was a useful adjunct when there was uncertainty about placement of the balloon by pressures alone. Nonetheless, with continued experience, careful monitoring and documentation of esophageal balloon positioning, and reliable transpulmonary pressure trends, esophageal manometry can allow for individualization and optimization of ventilator settings in PARDS. Development of guidelines and research on the use of transpulmonary pressure in PARDS is needed to assess for potential complications and evaluate the impact of this practice on patient outcomes.

### References

- [1] R.G. Khemani, Positive end-expiratory pressure lower than the ARDS Network protocol is associated with higher pediatric acute respiratory distress syndrome mortality, *Am. J. Respir. Crit. Care Med.* 198 (1) (2018 Jul 1) 77–89.
- [2] Pediatric Acute Lung Injury Consensus Conference Group, Pediatric acute respiratory distress syndrome: consensus recommendations from the pediatric acute lung injury consensus conference, *Pediatr. Crit. Care Med.* 16 (2015) 428–439.
- [3] D. Talmor, T. Sarge, C. O'Donnell, Esophageal and transpulmonary pressures in acute respiratory failure, *Crit. Care Med.* 34 (5) (2006 May) 1389–1394.
- [4] S.J. Gleich, B.M. Schiltz, Y. Ouellette, Improvement in oxygenation utilizing transpulmonary pressure monitoring for optimal positive end-expiratory pressure in pediatric acute respiratory distress syndrome: a case report, *In Pract.* 13 (3) (2019 Aug 1) 114–117.
- [5] P.C. Rimensberger, I.M. Cheifetz, Ventilatory support in children with pediatric acute respiratory distress syndrome: proceedings from the pediatric acute lung injury consensus conference, *Pediatr. Crit. Care Med.* 16 (5 Suppl 1) (2015 June) S51–S60.
- [6] K. Orloff, D. Turner, K. Rehder, The current state of pediatric acute respiratory distress syndrome, *Pediatric Allergy Immunol Pulmonol* 32 (2) (2019 Jun 1) 35–44.
- [7] L. Gattinoni, J. Marini, F. Collino, The future of mechanical ventilation: lessons from the present and the past, *Crit. Care* 21 (1) (2017 Jul 12) 183.
- [8] N. Nicardi, G. Mortamet, L. Ducharme-Crevier, Recent advances in pediatric ventilatory assistance, *F1000Res* 6 (2017 Mar 17) 290.

- [9] Hamilton Medical, Transpulmonary Pressure Measurement: Benefit of Measuring Transpulmonary Pressure in Mechanically Ventilated Patients, Arnal JM, Bonaduz, Switzerland, 2018.
- [10] E.B. Kassis, S.H. Loring, D. Talmor, Mortality and pulmonary mechanics in relation to respiratory system and transpulmonary driving pressures in ARDS, *Intensive Care Med.* 42 (2016 Aug) 1206–1213.
- [11] M. Pandey, D. Gupta, N. Gupta, Use of transpulmonary pressure monitoring in the management of extrapulmonary pediatric acute respiratory distress syndrome with multi-organ dysfunction syndrome (MODS): are we peepophobic? *Clin. Med. Insights Case Rep.* 12 (2019 Apr 12) 1–3.
- [12] J.C. Hotz, C.T. Sodekani, J. Van Steenberg, Measurements obtained from esophageal balloon catheters are affected by the esophageal balloon filling volume in children with ARDS, *Respir. Care* 63 (2) (2018 Feb) 177–186.
- [13] F. Mojoli, F. Torriglia, A. Orlando, Technical aspects of bedside respiratory monitoring of transpulmonary pressure, *Ann. Transl. Med.* 6 (19) (2018 Oct) 377.