

## [ Orthopaedics ]

# The Function of the Human Anterior Cruciate Ligament and Analysis of Single- and Double-Bundle Graft Reconstructions

Frank R. Noyes, MD

**Context:** There exists controversy on the ability of a single or double anterior cruciate ligament graft technique to restore anterior cruciate ligament function. This article examines the published experimental and clinical data supporting these surgical procedures in the ability to restore knee stability.

**Evidence Acquisition:** An analysis of anterior cruciate ligament function and single- and double-graft reconstructions defined by selected biomechanical, robotic, kinematic, anatomical, and clinical studies.

**Results:** The anterior cruciate ligament resists the combined motions of anterior tibial translation and internal tibial rotation, which defines the concept of rotational stability. This function prevents anterior tibial subluxation of the lateral and medial tibiofemoral compartments that accounts for the pivot-shift phenomena. The placement of single anterior cruciate ligament grafts high and proximal at the femoral attachment and posterior at the tibial attachment results in a vertical graft orientation. This graft placement results in a limited ability to provide rotational stability and is inferior when compared to a double-bundle graft procedure. Studies show that a more oblique single-graft orientation, in the sagittal and coronal plane, achieved from a central anatomic femoral and tibial location provides rotational stability similar to a double-bundle anterior cruciate ligament graft.

**Conclusion:** There exists insufficient experimental and clinical data to recommend the more complex double-bundle anterior cruciate ligament graft technique over a well-placed central anatomic single graft in terms of restoring knee rotational stability. Meticulous surgical technique for anterior cruciate ligament graft placement is necessary to avoid failure.

**Keywords:** single bundle; double bundle; anatomic reconstruction

As a result of recently published in vitro biomechanical and robotic anterior cruciate ligament (ACL) studies,<sup>3,28,56,67,68</sup> clinicians have made recommendations to perform double-bundle ACL reconstructions instead of single-graft procedures. These authors cite an increased failure rate of single-graft reconstructions with return of the pivot-shift phenomena.<sup>3,28,56,67,68</sup> Other clinical studies do not support this recommendation and report that single-graft ACL reconstructions have a high success rate in restoring knee stability without the added complexity of double-bundle surgery that requires 2 grafts and 2 femoral and tibial tunnels.<sup>1,6,23,35,57</sup> The term “stability” refers to the ability of an ACL reconstruction to restore normal knee motion limits that resist abnormal tibiofemoral compartment translations (anterior subluxations) and does not refer to patient complaints of giving way.<sup>47</sup>

The most important factor addressed in this article is the surgical technique related to tibial and femoral placement of ACL grafts. This determines the ability of the graft to resist abnormal anterior tibial translation and internal tibial rotation. These events occur in the pivot-shift phenomena and explain patient giving-way symptoms. Recent publications<sup>10,20,29</sup> have drawn attention to a vertical ACL graft orientation that occurs when a graft is placed in a high proximal femoral attachment and posterior tibial attachment location. The femoral tunnel is drilled through a tibial tunnel placed in the posterior one-third of the ACL tibial attachment. A graft in this vertical orientation (Figure 1) may potentially resist anterior tibial translation but does not resist combined anterior translation and internal rotation, resulting in a persistent pivot-shift phenomenon after surgery.<sup>10,20,29</sup>

From the Cincinnati SportsMedicine Research and Education Foundation, Cincinnati, Ohio

Address correspondence to Frank Noyes, MD, Cincinnati SportsMedicine Research and Education Foundation, 10663 Montgomery Rd, Cincinnati, OH 45242 (e-mail: sbwestin@csoref.org).

No potential conflict of interest declared.

DOI: 10.1177/1941738108326980

© 2009 American Orthopaedic Society for Sports Medicine

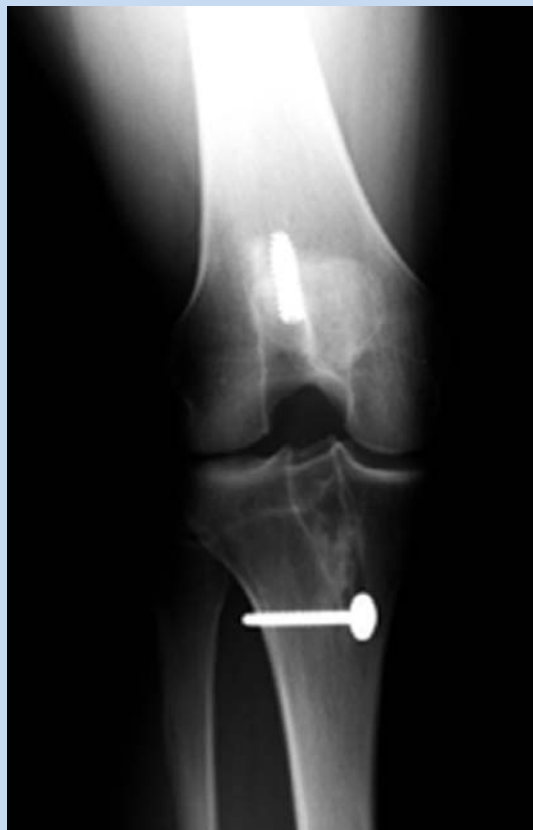

Figure 1. A vertical ACL graft orientation placed on the femoral notch roof and posterior on the tibial resulting in a residual pivot-shift and need for revision surgery.

The problems related to a vertical ACL graft placement appear to have developed in the 1990s with the change in surgery techniques from a 2-incision (femoral tunnel drilled through separate thigh incision) to a single-incision technique using the tibial incision and transtibial drilling of the femoral tunnel. A tibial tunnel placed in the posterior ACL attachment site was used to drill the femoral tunnel. This technique decreased graft notch impingement and need for a notchplasty and, theoretically, replaced posterior ACL tibial fibers that were more advantageous in controlling the pivot shift.<sup>36</sup> However, this technique frequently resulted in the femoral tunnel and ACL graft extending to the femoral notch roof out of the native ACL attachment and a posteriorly placed tibial graft not able to resist tibial rotation. It should be noted in the classic 2-incision technique, the rear entry type of drill guide through the distal lateral thigh incision places the ACL graft femoral tunnel on the lateral femoral wall within the ACL attachment.<sup>38,40,41</sup> The femoral tunnel is not drilled through the tibial tunnel. The tibial and femoral tunnels are not fashioned to be linked or parallel and drilled together. Therefore, the location of the tibial

tunnel does not control the location of the femoral tunnel. Publications of the 2-incision ACL technique reported a low failure rate (return of a positive pivot-shift test) and need for ACL revision.<sup>7,8,26,38,49</sup> The use of a small cosmetic second incision for the outside-in femoral tunnel has the advantage of being an accurate technique for ACL femoral graft placement.<sup>15,20, 38,40,41</sup> A second technique drills the femoral tunnel through the anteromedial portal with knee hyperflexion.

The first purpose of this article is to review biomechanical and kinematic published data and concepts that define ACL function; the second is to analyze studies on ACL anatomy relating to ACL femoral and tibial graft attachment sites. The third purpose is to review in vitro cadaveric and in vivo clinical studies on recommendations for single- and double-bundle ACL graft surgery.

## EVIDENCE ACQUISITION

### Biomechanical and Kinematic Data and Concepts That Define ACL Function

The ACL is the primary restraint to anterior tibial translation, providing 87% of the total restraining force at 30° of knee flexion and 85% at 90° of flexion.<sup>11</sup> The iliotibial band (ITB), midmedial capsule, midlateral capsule, medial collateral ligament (MCL), and fibular collateral ligament (FCL) provide a combined secondary restraint to anterior tibial translation. The posteromedial and posterolateral (PL) capsule provide added resistance with knee extension. The secondary restraints (including the menisci) may be injured or become deficient with repeat injuries, resulting in increases in anterior tibial translation and the pivot-shift test.<sup>21,43</sup>

The effect of the ACL and lateral structures on resisting anterior tibial translation in cadaveric knees is shown in Figure 2.<sup>59</sup> Progressive increases in anterior tibial translation occur when the lateral soft tissue restraints are sectioned.<sup>43,59</sup>

Sectioning of the ACL produces only a small increase in internal rotation.<sup>59</sup> Subsequent sectioning of the lateral structures produces sequentially larger increases in the limit of internal tibial rotation (Figure 3). Internal tibial rotation is primarily resisted by the lateral extra-articular structures. Clinical and biomechanical studies frequently attempt to measure the increase in internal tibial rotation limits to quantify ACL graft function.<sup>35</sup> Since the lateral structures resist the internal tibial rotation limit more than the ACL, this approach to measuring ACL function is not appropriate. Lachman and pivot-shift tests should be performed within the midportion of the tibial rotation envelope to avoid the constraining effect of medial or lateral restraints.<sup>45</sup>

The function of the ACL is ideally described by its effect in limiting the combined motions of anterior translation and internal tibial rotation and the resulting anterior subluxation of the lateral and medial tibiofemoral compartments which clinically represents the pivot-shift phenomena (Figures 4 and 5).<sup>22,43,45</sup>

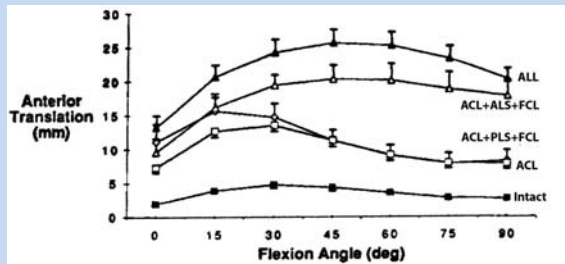


Figure 2. Limits of anterior translation for intact specimens and other lateral structures sectioned (100-N force). ALL; all structures; ACL, anterior cruciate ligament; ALS, anterolateral structures; FCL, fibular collateral ligament; PLS, posterolateral structures. (Reprinted with permission from the American Orthopaedic Society of Sports Medicine.<sup>59</sup>)

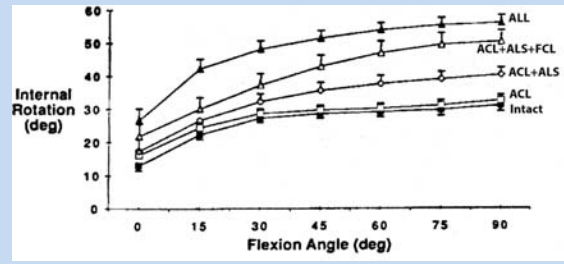


Figure 3. Limits of internal rotation for intact specimens and with the ACL and other lateral structures sectioned (5 Nm). Increases with the ACL cut were so small as to be clinically unimportant (approximately 2°-3°). ALL; all structures; ACL, anterior cruciate ligament; ALS, anterolateral structures; FCL, fibular collateral ligament. (Reprinted with permission from the American Orthopaedic Society of Sports Medicine.<sup>59</sup>)

### Analysis of Studies on ACL Anatomy and Relation to ACL Femoral and Tibial Graft Attachment Sites

There remains controversy on the division of the ACL into 2 anatomically distinct fiber bundles. Some authors report that an anatomic and functional division exists.<sup>50,61,65-67</sup> One study reported a bony ridge between the 2 femoral attachment bundles.<sup>18</sup> Other authors doubt there is a true anatomic division but believe instead that the division is functional.<sup>16,17</sup> The anteromedial (AM) bundle reportedly tightens in knee flexion.<sup>4,61</sup> The PL bundle is reportedly under tension with knee extension and relaxes with flexion as the ACL femoral attachment changes from a vertical to a horizontal orientation. An alternative hypothesis is that ACL fibers participate in load sharing, with different percentages of load in fiber regions as opposed to a reciprocal loading between separate distinct fiber bundles.<sup>19,24,55</sup>

Colombet et al<sup>13</sup> measured the ACL femoral and tibial attachments of 7 unpaired cadaveric knees, while Edwards et al<sup>16</sup> defined the ACL femoral and tibial attachments in 55 cadaveric specimens. Both provide excellent guides that detail ACL insertion anatomy. There exists a considerable variation in the studies on the anatomic division of the ACL into 2 distinct fiber bundles as well as attachment locations between knees.<sup>17</sup>

Heming et al<sup>25</sup> reported the ACL tibial and femoral footprints in 12 cadaveric knees (Figure 6). The authors reported that a single guide pin placed between the center of the femoral attachment and tibial attachment was only possible if the tibial tunnel entrance was close to the joint line. The tibial tunnel would be too short to be functional for most ACL grafts, and they commented that transtibial drilling techniques may result in a too proximal femoral ACL graft orientation.

Authors have advocated a guide pin and tibial tunnel placement for a single ACL graft 7 mm to 10 mm anterior to the PCL,<sup>27</sup> which results in a posterior tibial tunnel, often posterior

to the native ACL attachment and just a few millimeters from the posterior interspinous ridge. A posterior tibial tunnel places the ACL graft near the center of tibial rotation (decreased internal tibial rotation resistance) and vertical in the sagittal plane (decreased anterior tibial translation resistance).

A central anatomic ACL tibial attachment location directly adjacent to the lateral meniscus anterior horn attachment (and not posterior to the attachment) is shown in Figure 7. The ACL attachment is mapped at surgery based on anatomic reference maps (Figure 8). The most posterior extent of the ACL tibial attachment is 6 mm to 10 mm anterior to the retroeminence ridge (RER) or posterior interspinous ridge.<sup>4,13,16</sup> The center of the ACL is usually 16 mm to 20 mm anterior to the posterior interspinous ridge. The guide pin is ideally placed eccentric and 2 mm to 3 mm anterior and medial to the true ACL center, as the ACL graft displaces to the posterior and lateral aspect of the tibial tunnel.<sup>12</sup> It is important that ACL graft impingement against the anterior femoral notch not occur, and this must be verified at surgery.<sup>38,40,41</sup> Howell et al<sup>27</sup> showed that roof impingement was avoided and hyperextension regained when the center of the ACL tibial tunnel was placed 2 mm to 3 mm posterior to the normal center of the ACL tibial insertion. This would place the tibial tunnel more posterior than the central tibial tunnel described above, which is not recommended.

There are no ACL fibers that extend to the intercondylar notch roof (Figure 8A). For single grafts, an anatomic central ACL placement locates the femoral guide pin just above the midpoint of the proximal-to-distal length of the ACL attachment and 7 mm to 8 mm from the posterior articular cartilage edge, leaving approximately 3 mm of a posterior tunnel wall (Figure 8D). An 8-mm- to 9-mm-diameter tunnel occupies the central ACL attachment, leaving the most proximal and distal few millimeters of the ACL attachment unoccupied by a graft. To reliably achieve this femoral graft location, a hyperflexed knee position ( $\geq 110^\circ$ ) using the anteromedial portal or a

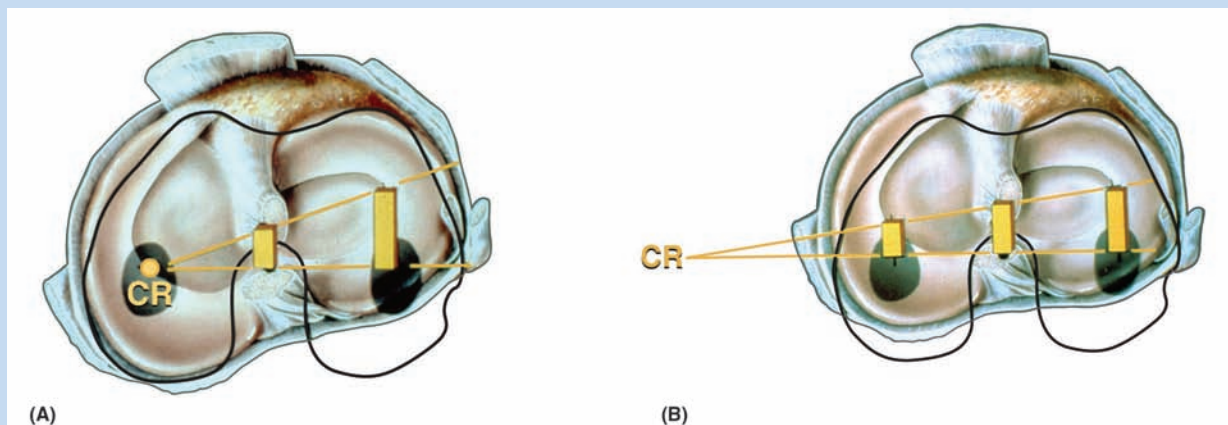


Figure 4. Intact knee (A) and after ACL sectioning (B): response to combined anterior translation and internal rotation about a center of rotation (CR) resulting in anterior subluxation of the lateral and medial tibiofemoral compartments.

2-incision technique is recommended. The different ACL graft placement positions are shown in Figure 9.

### Review of In Vitro Cadaveric and In Vivo Clinical Studies on Single- and Double-Bundle ACL Grafts

Sakane et al,<sup>52</sup> in one of the first cadaveric robotic studies, reported the PL bundle provided the primary restraint to anterior tibial translation at low flexion angles. Increasing forces were reported in the AM bundle with knee flexion; these remained lower than the calculated in situ forces of the PL bundle up to approximately 50° of flexion.

Zantop et al<sup>64</sup> in a robotic study in cadaveric knees analyzed the effect of a 134-N anterior load and a combined rotary load of 10 Nm valgus/4 Nm internal rotation to simulate the pivot-shift phenomena. Sectioning the PL bundle at 30° of flexion resulted in an approximate 7 mm increase in anterior tibial translation, while sectioning the AM bundle at 60° produced an approximate 9-mm increase. Similar data were reported at low flexion angles for the combined rotational loads. The data implies a near absence of function of the remaining “intact” bundle which is contrary to clinical findings in knees with partial ACL tears. Markolf et al,<sup>32</sup> in a cadaveric knee study, reported that cutting the PL bundle resulted in an increase mean translation of only 1.1 mm (at 10°) and 0.5 mm (at 30°, 100-N load) and questioned the need to reconstruct the PL bundle for restoration of normal AP laxity.

Gabriel et al<sup>19</sup> in a cadaveric robotic study removed all of the soft tissues to produce a femur-ACL-tibia specimen. For anterior tibial loading (Figure 10), the AM bundle was nearly equal to the PL bundle at 15° of flexion, with increasing AM forces with knee flexion. Under the rotational loads of valgus and internal tibial rotation, the forces in the AM bundle exceeded those of the PL bundle (Figure 11). Other studies<sup>30,31</sup> also support a load sharing between ACL fibers rather than a reciprocal loading between ACL bundles. For example, Mae et al<sup>31</sup> in a

cadaveric robotic study reported the load sharing between the ACL bundles. The PL bundle functioned more at low flexion angles, equal to the AM at 10° of flexion, and an increase in AM bundle function with increasing knee flexion. Li et al<sup>30</sup> in an in vivo study of ACL kinematics during weightbearing reported no distinct separation of ACL function by a bundle arrangement. Thus the classical description of a reciprocal loading between the PL bundle (tight in extension) and AM bundle (tight in flexion) inadequately describes the load-sharing of ACL fibers and the theoretical basis for a double-bundle reconstruction. Given the complex ACL fiber microgeometry and fiber tension behavior, a single graft or 2 grafts would not be expected to replicate normal ACL function but, instead, provide an imperfect check-rein to limit abnormal motions and joint subluxations.<sup>21,44</sup>

Cadaveric and robotic studies have typically analyzed single ACL grafts placed in the proximal femoral 1-o'clock position with a posterior tibial ACL attachment, which produced a less than ideal vertical ACL graft construct.<sup>50,61</sup> Only a few studies<sup>32,62</sup> compared a 2-bundle graft construct to a single graft placed centrally in the femoral ACL footprint. Consequently, there are major differences in the functional properties between ACL single-graft reconstructions in cadaveric studies based on the femoral and tibial graft placement.

Yagi et al<sup>61</sup> compared single- and double-bundle ACL hamstring reconstructions in cadaveric knees. A double-looped single-bundle hamstring graft was placed at the approximate 1 o'clock position and tensioned to 44 N, while each bundle of the double-bundle graft was tensioned to 44 N. The double-bundle graft had a total of 88 N of tension compared to the 44 N for the single-graft reconstruction. In response to a 134-N anterior load at 30° of flexion, the data showed an unexplained residual anterior tibial translation in the single-bundle constructs (intact,  $6.4 \pm 2.4$  mm; single bundle,  $10.2 \pm 2.5$  m). The lax single graft suggests an experimental artifact in graft fixation.

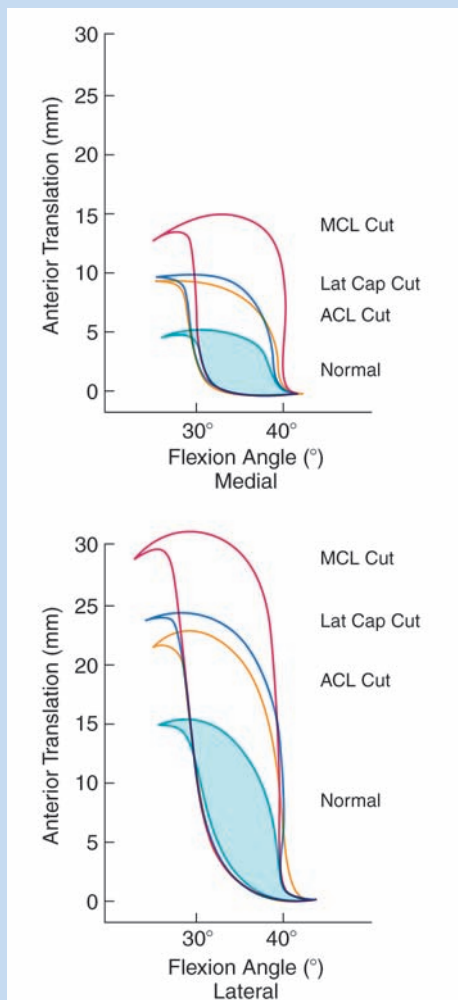


Figure 5. Anterior tibial translation for the lateral and medial tibiofemoral compartments during the pivot-shift test in a normal knee and after ACL sectioning shows lateral compartment translation is greater than medial compartment with effect of additional ligament sectioning increasing the compartment subluxations. MCL, medial collateral ligament; Lat Cap, lateral capsule; ACL, anterior cruciate ligament. (Reprinted with permission from *Acta Orthopaedica*.<sup>46</sup>)

Mae et al<sup>31</sup> studied the effect of a single versus 2-femoral tunnel ACL graft reconstruction in cadaveric knees using a robotic simulator. A single tunnel was placed in the center of the ACL tibial attachment. The locations of the single- and double femoral tunnels were described as the 1:00 and 2:30 positions. The data showed only small differences between the single- and double-bundle grafts in limiting anterior tibial translation (30° of flexion,  $9.4 \pm 1.7$  mm and  $8.8 \pm 1.5$  mm, respectively;  $P < .05$ ). Importantly, both reconstructions overconstrained the knee by limiting normal anterior tibial translation.

One of the few studies in which a central femoral anatomic placement of the ACL graft was used was published by Yamamoto et al.<sup>62</sup> The cadaveric robotic study compared a single ACL graft placed in the 10 o'clock position on the lateral notch wall with an anatomic double-bundle reconstruction. There was no statistical difference in the anterior tibial translation or combined rotatory loading conditions between the intact ACL, single graft, or double-bundle reconstructions.

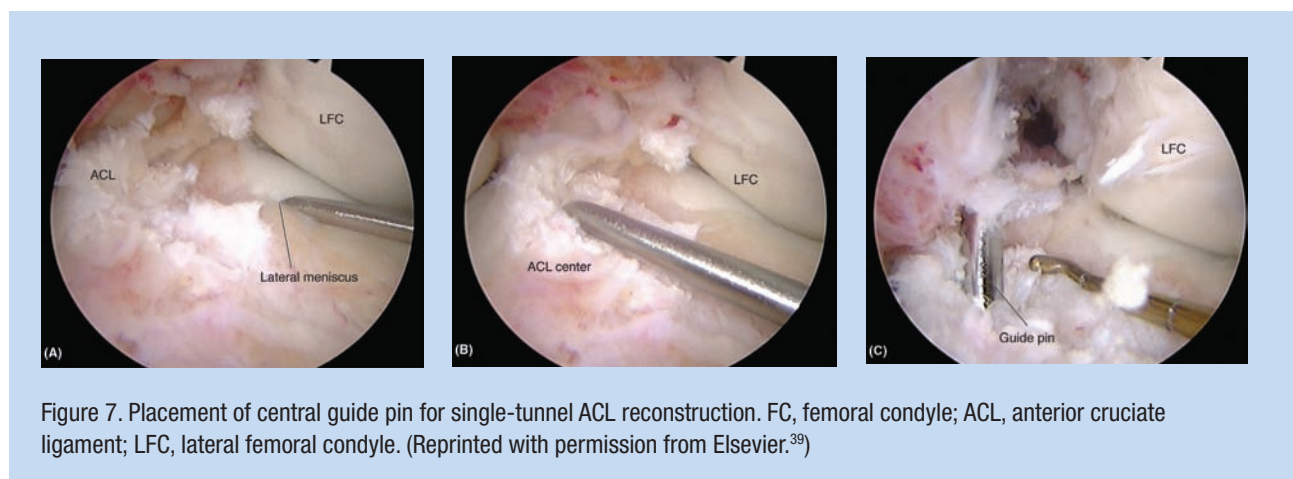
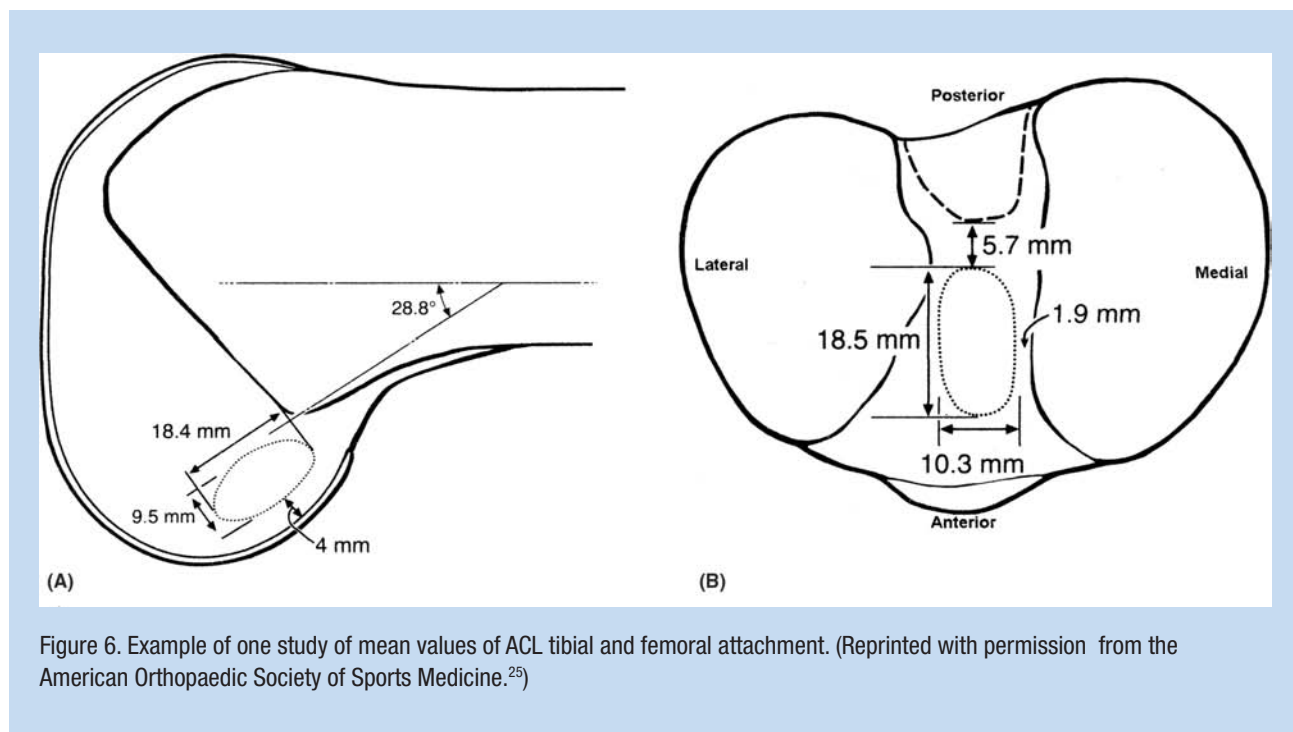
Markolf et al<sup>33</sup> measured a simulated pivot-shift in intact cadaveric knees and again following single- and double-bundle ACL reconstructions. The single bundle was placed in a central anterior tibial ACL attachment location (simulating the AM bundle) and not in a posterior tibial attachment position. The single-bundle reconstruction restored mean tibial rotations and lateral plateau displacements to levels similar to those of the intact knee. The double-bundle reconstruction reduced combined rotations and displacements to levels less than those of the intact knee. The authors concluded that the overconstraint induced by the double-bundle reconstruction has unknown clinical consequences, and that the need for the added complexity of this procedure is questionable.

Cuomo et al<sup>14</sup> reported on the effects of tensioning single- and double-bundle ACL reconstructions in cadaveric knees. Tensioning both the AM and PL grafts simultaneously at 20° provided the best match for AP translation in the intact knee throughout knee flexion. The data show the difficulty in tensioning 2 ACL grafts at surgery.

In theory, a double-graft construct tensioned appropriately results in less overall graft tension in each of the graft arms due to load sharing. Thus, there is a theoretical advantage of a double-graft construct resisting abnormal joint motions under lower graft tensile loads. However, it is not known if these theoretical advantages of a double-graft construct will improve the clinical results of ACL reconstruction.

During clinical knee arthrometer testing, only anterior tibial translation is assessed. If the knee joint has  $\leq 3$  mm increase in anterior tibial translation over the opposite knee, a positive pivot-shift phenomena will not occur, as this amount of constraint to anterior tibial translation also limits internal rotation.<sup>38</sup> Conversely, if  $>5$  mm of increased anterior tibial translation exists, there is usually an abnormal increase in internal tibial rotation that contributes to a positive pivot-shift test and explains patient complaints of instability.<sup>45</sup> A problem occurs in knees that demonstrate 3 mm to 5 mm of increased anterior tibial translation, which may represent 20% to 30% of patients in clinical investigations,<sup>2,5,48,53,54</sup> especially when allografts are used.<sup>42</sup> If the increased anterior translation and internal rotation leads to a positive pivot-shift, symptoms of giving way may occur.<sup>45</sup>

Bull et al<sup>9</sup> were among the first authors to report intraoperative measurement of tibial translations and rotations using a 3-dimensional motion analysis system. Robinson and associates<sup>51</sup> performed an ACL double-bundle reconstruction using computerized navigation techniques in 22 patients. The studies do not provide data on ideal ACL graft placements, as



knee loading and reproducible joint position conditions are not possible in the operating room setting.

Tashman et al<sup>58</sup> devised a unique methodology of dynamic *in vivo* knee radiographic measurements of patients running downhill after ACL reconstruction. The reconstructed knees showed a mean increase in external tibial rotation ( $3.8^\circ \pm 2.3^\circ$ ) and adduction ( $2.8^\circ \pm 1.6^\circ$ ), which is of unknown clinical significance. Future *in vivo* studies that involve more dynamic rotational knee movements and loading conditions are necessary.

Monaco et al<sup>55</sup> compared the effect of a single-bundle ACL reconstruction with an extra-articular procedure to a double-bundle reconstruction. The addition of the PL bundle after the AM bundle did not reduce AP translation or internal tibial rotation.

Several clinical studies\* have been published that compared the outcome of primary single- and double-bundle ACL reconstructions. A critical review of these studies is beyond the scope of this article. Unfortunately, the majority of authors used a vertically oriented ACL graft for the single-bundle construct (via a transtibial technique), which produced a greater number of patients with a positive pivot-shift test postoperatively compared to the double-bundle procedures.<sup>29</sup> However, not all of the investigations reported a significant difference in postoperative stability, which led some authors to not recommend the double-bundle procedure.<sup>1,6,23,57</sup> In addition, none of the studies found clinical differences

\*References 1, 3, 6, 23, 28, 29, 37, 56, 57, 60, 63.

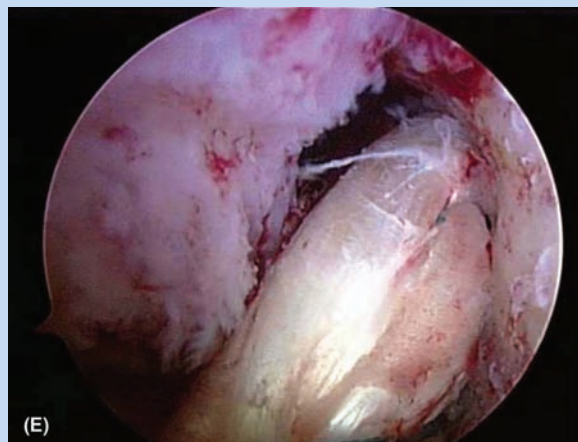
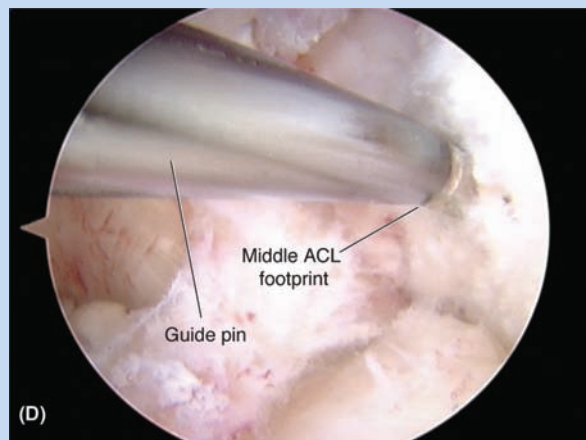
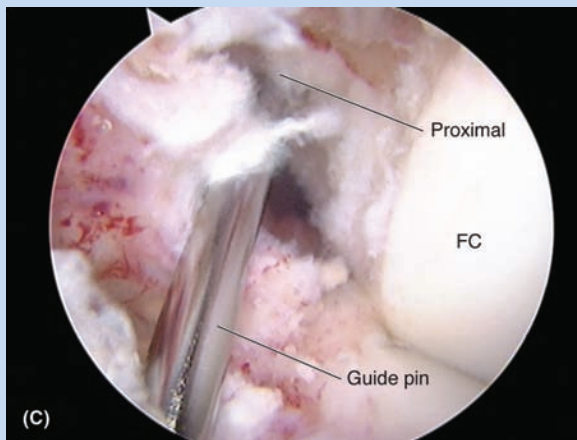
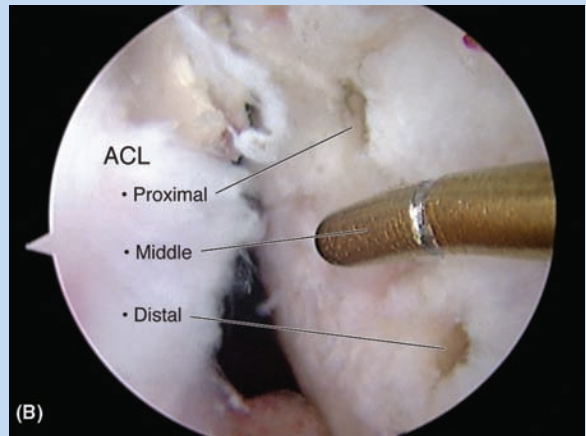
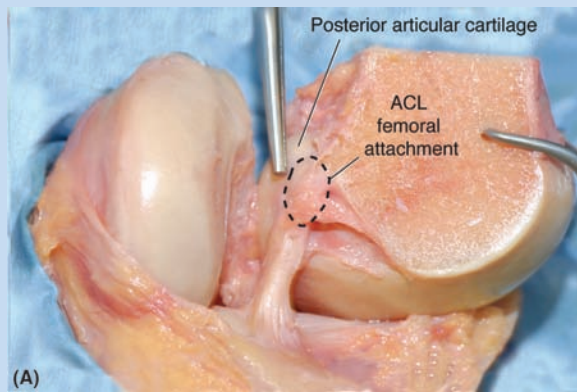


Figure 8. (A) ACL femoral attachment shows the entire attachment on lateral wall of notch. (B) 3 points identified in proximal, middle, and distal portions of ACL attachment. (C) Transtibial guide pin placement reaches only proximal one-third of ACL attachment with a portion of the femoral tunnel extending onto the notch roof when a central ACL tibial tunnel is used. (D) ACL central point reached with knee hyperflexion and anteromedial portal or with 2-incision rear-entry technique. (E) Final appearance and placement of ACL graft. ACL, anterior cruciate ligament; LC, femoral condyle. (Reprinted with permission from Elsevier.<sup>39</sup>)

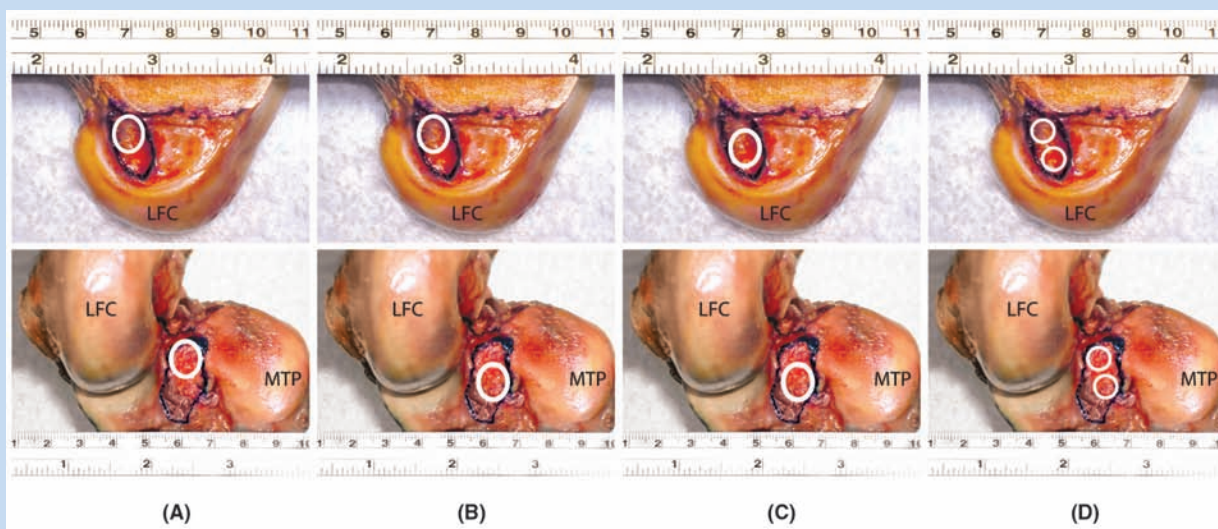


Figure 9. Summary of different femoral and tibial graft positions using anteromedial and posterolateral bundle terminology. (A) Classic AM femur to PL tibia results in a vertical graft with a tibial tunnel placed too far posteriorly. (B) A more central tibial tunnel is advantageous for control of rotational stability. (C) The ideal central femoral-tibial tunnel locations for a single-graft reconstruction. (D) The placement of a 2-bundle ACL reconstruction. LFC, lateral femoral condyle; MTP, medial tibial plateau. (Reprinted with permission from Elsevier.<sup>39</sup>)

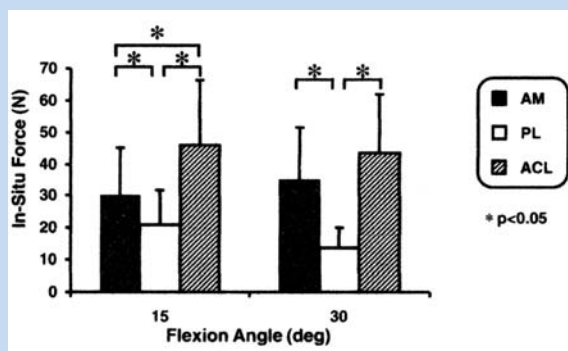


Figure 10. In situ force in the intact ACL and its AM and PL bundles in response to combined rotatory load (10 Nm valgus and 5 Nm internal tibial torque). AM, anteromedial; PL, posterolateral; ACL, anterior cruciate ligament. (Reprinted with permission of Wiley-Liss Inc, a subsidiary of John Wiley & Sons Inc.<sup>19</sup>)

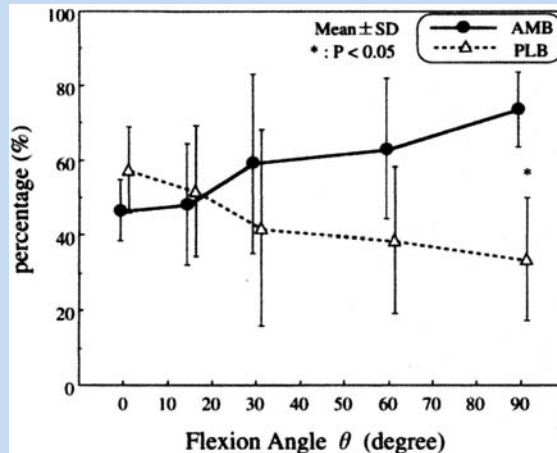


Figure 11. Graph showing force sharing between ACL bundles under 100 N of anterior load. AMB, anteromedial bundle; PLB, posterolateral bundle. (Reprinted with permission from Elsevier.<sup>31</sup>)

between the procedures, as all subjective and functional scores were comparable.

Lastly, Meredick et al<sup>34</sup> conducted a meta-analysis of level I to III clinical studies that compared single- and double-bundle reconstructions and reported no clinically relevant difference existed in arthrometer (KT-2000; Medmetric Corporation, San Diego, California) and pivot-shift test data. The mean difference between the reconstructed and contralateral knee on knee arthrometer testing was 0.5 mm, and there was no difference in

the odds of having a normal or nearly normal pivot-shift result between reconstruction methods.

## CONCLUSION

The concepts of ACL double-bundle grafts have prompted a worthwhile reevaluation of ACL anatomy and study of the ideal locations for both single and double grafts. The



published in vitro robotic and biomechanical studies and in vivo clinical studies have reached different conclusions on the advantage of a double-bundle ACL graft over a single ACL graft, preventing definitive conclusions. The cadaveric studies supporting double-bundle ACL grafts appear to have made the comparison to a less than ideal single graft placed in a proximal femoral and posterior tibial attachment. Other cadaveric studies show a single ACL graft placed at anatomic tibial and femoral attachment sites (avoiding a posterior tibial placement) provides rotational stability similar to a double-bundle graft. Accordingly, the added operative complexity of a double-bundle graft may not be required. In vitro and clinical outcome studies between double-bundle grafts and a “well placed” anatomic single graft are required for the future.

## REFERENCES

- Adachi N, Ochi M, Uchio Y, et al. Reconstruction of the anterior cruciate ligament. Single- versus double-bundle multistranded hamstring tendons. *J Bone Joint Surg Br.* 2004;86(4):515-520.
- Aglietti P, Giron F, Buzzi R, et al. Anterior cruciate ligament reconstruction: bone-patellar tendon-bone compared with double semitendinosus and gracilis tendon grafts. A prospective, randomized clinical trial. *J Bone Joint Surg Am.* 2004;86-A(10):2143-2155.
- Aglietti P, Giron F, Cuomo P, et al. Single-and double-incision double-bundle ACL reconstruction. *Clin Orthop Relat Res.* 2007; 454:108-113.
- Amis A, Dawkins G. Functional anatomy of the anterior cruciate ligament. Fibre bundle actions related to ligament replacements and injuries. *J Bone Joint Surg Br.* 1991;73(2):260-267.
- Arciero RA, Scoville CR, Snyder RJ, et al. Single versus 2-incision arthroscopic anterior cruciate ligament reconstruction. *Arthroscopy.* 1996;12:462-469.
- Asagumo H, Kimura M, Kobayashi Y, et al. Anatomic reconstruction of the anterior cruciate ligament using double-bundle hamstring tendons: surgical techniques, clinical outcomes, and complications. *Arthroscopy.* 2007;23(6):602-609.
- Beynonn BD, Johnson RJ, Abate JA, et al. Treatment of anterior cruciate ligament injuries, part 2. *Am J Sports Med.* 2005;33(11):1751-1767.
- Brandsson S, Faxen E, Eriksson BI, et al. Reconstruction of the anterior cruciate ligament: comparison of outside-in and all-inside techniques. *Br J Sports Med.* 1999;33(1):42-45.
- Bull AM, Earnshaw PH, Smith A, et al. Intraoperative measurement of knee kinematics in reconstruction of the anterior cruciate ligament. *J Bone Joint Surg Br.* 2002;84(7):1075-1081.
- Busam ML, Provencher MT, Bach BR Jr. Complications of anterior cruciate ligament reconstruction with bone-patellar tendon-bone constructs: care and prevention. *Am J Sports Med.* 2008;36(2):379-394.
- Butler DL, Noyes FR, Grood ES. Ligamentous restraints to anterior-posterior drawer in the human knee. A biomechanical study. *J Bone Joint Surg Am.* 1980;62(2):259-270.
- Clancy WGJ, Nelson DA, Reider B, et al. Anterior cruciate ligament reconstruction using one-third of the patellar ligament, augmented by extra-articular tendon transfers. *J Bone Joint Surg Am.* 1982;64(3):352-359.
- Colombet P, Robinson J, Christel P, et al. Morphology of anterior cruciate ligament attachments for anatomic reconstruction: a cadaveric dissection and radiographic study. *Arthroscopy.* 2006; 22(9):984-992.
- Cuomo P, Rama KR, Bull AM, et al. The effects of different tensioning strategies on knee laxity and graft tension after double-bundle anterior cruciate ligament reconstruction. *Am J Sports Med.* 2007;35(12):2083-2090.
- Diamantopoulos AP, Lorbach O, Paessler HH. Anterior cruciate ligament revision reconstruction: results in 107 patients. *Am J Sports Med.* 2008;36(5):851-860.
- Edwards A, Bull AM, Amis AA. The attachments of the anteromedial and posterolateral fibre bundles of the anterior cruciate ligament. Part 1: tibial attachment. *Knee Surg Sports Traumatol Arthrosc.* 2007;15(12):1414-1421.
- Edwards A, Bull AM, Amis AA. The attachments of the anteromedial and posterolateral fibre bundles of the anterior cruciate ligament. Part 2: femoral attachment. *Knee Surg Sports Traumatol Arthrosc.* 2007;16(1):29-36.
- Ferretti M, Levicoff EA, Macpherson TA, et al. The fetal anterior cruciate ligament: an anatomic and histologic study. *Arthroscopy.* 2007;23(3):278-283.
- Gabriel MT, Wong EK, Woo SL, et al. Distribution of in situ forces in the anterior cruciate ligament in response to rotatory loads. *J Orthop Res.* 2004;22(1):85-89.
- George MS, Dunn WR, Spindler KP. Current concepts review: revision anterior cruciate ligament reconstruction. *Am J Sports Med.* 2006;34(12):2026-2037.
- Grood ES, Noyes FR. Diagnosis of knee ligament injuries: biomechanical precepts. In: Feagin J, ed. *The Crucial Ligaments.* New York, NY: Churchill Livingstone; 1987.
- Haimes JL, Wroble RR, Grood ES, et al. Role of the medial structures in the intact and anterior cruciate ligament-deficient knee. Limits of motion in the human knee. *Am J Sports Med.* 1994;22(3):402-409.
- Hamada M, Shino K, Horibe S, et al. Single- versus bisocket anterior cruciate ligament reconstruction using autogenous multiple-stranded hamstring tendons with Endobutton femoral fixation: a prospective study. *Arthroscopy.* 2001;17(8):801-807.
- Hefzy MS, Grood ES, Noyes FR. Factors affecting the region of most isometric femoral attachments. Part II: the anterior cruciate ligament. *Am J Sports Med.* 1989;17(2):208-216.
- Heming JF, Rand J, Steiner ME. Anatomical limitations of transtibial drilling in anterior cruciate ligament reconstruction. *Am J Sports Med.* 2007;35(10):1708-1715.
- Hess T, Duchow J, Roland S, et al. Single- versus 2-incision technique in anterior cruciate ligament replacement: influence on postoperative muscle function. *Am J Sports Med.* 2002;30(1):27-31.
- Howell SM, Clark JA. Tibial tunnel placement in anterior cruciate ligament reconstructions and graft impingement. *Clin Orthop Relat Res.* 1992;283:187-195.
- Jarvela T, Moisa AS, Sihvonen R, et al. Double-bundle anterior cruciate ligament reconstruction using hamstring autografts and bioabsorbable interference screw fixation: prospective, randomized, clinical study with 2-year results. *Am J Sports Med.* 2008;36(2):290-297.
- Kondo E, Yasuda K, Azuma H, Tanabe Y, Yagi T. Prospective clinical comparisons of anatomic double-bundle versus single-bundle anterior cruciate ligament reconstruction procedures in 328 consecutive patients. *Am J Sports Med.* 2008;36(9):1675-1687.
- Li G, Defrate LE, Rubash HE, et al. In vivo kinematics of the ACL during weightbearing knee flexion. *J Orthop Res.* 2005;23(2):340-344.
- Mae T, Shino K, Miyama T, et al. Single- versus 2-femoral socket anterior cruciate ligament reconstruction technique: biomechanical analysis using a robotic simulator. *Arthroscopy.* 2001;17(7):708-716.
- Markolf KL, Park S, Jackson SR, et al. Contributions of the posterolateral bundle of the anterior cruciate ligament to anterior-posterior knee laxity and ligament forces. *Arthroscopy.* 2008;24(7):805-809.
- Markolf KL, Park S, Jackson SR, et al. Simulated pivot-shift testing with single- and double-bundle anterior cruciate ligament reconstructions. *J Bone Joint Surg Am.* 2008;90(8):1681-1689.
- Meredick RB, Vance KJ, Appleby D, et al. Outcome of single-bundle versus double-bundle reconstruction of the anterior cruciate ligament: a meta-analysis. *Am J Sports Med.* 2008;36(7):1414-1421.
- Monaco E, Labianca L, Contedua F, et al. Double-bundle or single-bundle plus extra-articular tenodesis in ACL reconstruction? A CAOS study. *Knee Surg Sports Traumatol Arthrosc.* 2007;15(10):1168-1174.
- Morgan CD, Kalman VR, Grawl DM. Definitive landmarks for reproducible tibial tunnel placement in anterior cruciate ligament reconstruction. *Arthroscopy.* 1995;11(3):275-288.
- Muneta T, Koga H, Mochizuki T, et al. A prospective randomized study of 4-strand semitendinosus tendon anterior cruciate ligament reconstruction comparing single-bundle and double-bundle techniques. *Arthroscopy.* 2007;23(6):618-628.
- Noyes FR, Barber-Westin SD. A comparison of results in acute and chronic anterior cruciate ligament ruptures of arthroscopically assisted autogenous patellar tendon reconstruction. *Am J Sports Med.* 1997;25(4):460-471.
- Noyes FR, Barber-Westin SD. ACL primary and revision reconstruction: diagnosis, operative techniques, clinical outcomes. In: *Knee Disorders: Surgery, Rehabilitation, Clinical Outcomes.* Philadelphia, PA: Elsevier. In press.
- Noyes FR, Barber-Westin SD. Anterior cruciate ligament revision reconstruction: results using a quadriceps tendon-patellar bone autograft. *Am J Sports Med.* 2006;34(4):553-564.
- Noyes FR, Barber-Westin SD. Revision anterior cruciate surgery with use of bone-patellar tendon-bone autogenous grafts. *J Bone Joint Surg Am.* 2001;83-A(8):1131-1143.
- Noyes FR, Barber-Westin SD, Roberts CS. Use of allografts after failed treatment of rupture of the anterior cruciate ligament. *J Bone Joint Surg Am.* 1994;76(7):1019-1031.

43. Noyes FR, Grood ES. Classification of ligament injuries: why an anterolateral laxity or anteromedial laxity is not a diagnostic entity. *Instr Course Lect*. 1987;36:185-200.
44. Noyes FR, Grood ES. Diagnosis of knee ligament injuries: 5 concepts. In: Feagin J, ed. *The Crucial Ligaments*. New York, NY: Churchill Livingstone; 1988.
45. Noyes FR, Grood ES, Cummings JF, et al. An analysis of the pivot-shift phenomenon. The knee motions and subluxations induced by different examiners. *Am J Sports Med*. 1991;19(2):148-155.
46. Noyes FR, Grood ES, Suntay WJ. Three-dimensional motion analysis of clinical stress tests for anterior knee subluxations. *Acta Orthop Scand*. 1989;60;3:308-319.
47. Noyes FR, Grood ES, Torzilli PA. Current concepts review. The definitions of terms for motion and position of the knee and injuries of the ligaments. *J Bone Joint Surg Am*. 1989;71(3):465-472.
48. O'Neill DB. Arthroscopically assisted reconstruction of the anterior cruciate ligament. A prospective randomized analysis of 3 techniques. *J Bone Joint Surg Am*. 1996;78(6):803-813.
49. Panni AS, Milano G, Tartarone M, et al. Clinical and radiographic results of ACL reconstruction: a 5- to 7-year follow-up study of outside-in versus inside-out reconstruction techniques. *Knee Surg Sports Traumatol Arthrosc*. 2001;9(2):77-85.
50. Petersen W, Tretow H, Weimann A, et al. Biomechanical evaluation of 2 techniques for double-bundle anterior cruciate ligament reconstruction: 1 tibial tunnel versus 2 tibial tunnels. *Am J Sports Med*. 2007;35(2):228-234.
51. Robinson J, Carrat L, Granchi C, et al. Influence of anterior cruciate ligament bundles on knee kinematics: clinical assessment using computer-assisted navigation. *Am J Sports Med*. 2007;35(12):2006-2013.
52. Sakane M, Fox RJ, Woo SL, et al. In situ forces in the anterior cruciate ligament and its bundles in response to anterior tibial loads. *J Orthop Res*. 1997;15(2):285-293.
53. Sgaglione NA, Schwartz RE. Arthroscopically assisted reconstruction of the anterior cruciate ligament: initial clinical experience and minimal 2-year follow-up comparing endoscopic transtibial and 2-incision techniques. *Arthroscopy*. 1997;13(2):156-165.
54. Shaieb MD, Kan DM, Chang SK, et al. A prospective randomized comparison of patellar tendon versus semitendinosus and gracilis tendon autografts for anterior cruciate ligament reconstruction. *Am J Sports Med*. 2002;30(2):214-220.
55. Sidles JA, Larson RV, Garbini JL, et al. Ligament length relationship in the moving knee. *J Orthop Res*. 1988;6(4):593-610.
56. Siebold R, Dehler C, Ellert T. Prospective randomized comparison of double-bundle versus single-bundle anterior cruciate ligament reconstruction. *Arthroscopy*. 2008;24(2):137-145.
57. Streich NA, Friedrich K, Gotterbarm T, et al. Reconstruction of the ACL with a semitendinosus tendon graft: a prospective randomized single blinded comparison of double-bundle versus single-bundle technique in male athletes. *Knee Surg Sports Traumatol Arthrosc*. 2008;16(3):232-238.
58. Tashman S, Collon D, Anderson K, et al. Abnormal rotational knee motion during running after anterior cruciate ligament reconstruction. *Am J Sports Med*. 2004;32(4):975-983.
59. Wroble RR, Grood ES, Cummings JS, et al. The role of the lateral extra-articular restraints in the anterior cruciate ligament-deficient knee. *Am J Sports Med*. 1993;21(2):257-262; discussion 263.
60. Yagi M, Kuroda R, Nagamune K, et al. Double-bundle ACL reconstruction can improve rotational stability. *Clin Orthop Relat Res*. 2007;454:100-107.
61. Yagi M, Wong EK, Kanamori A, et al. Biomechanical analysis of an anatomic anterior cruciate ligament reconstruction. *Am J Sports Med*. 2002;30(5):660-666.
62. Yamamoto Y, Hsu WH, Woo SL, et al. Knee stability and graft function after anterior cruciate ligament reconstruction: a comparison of a lateral and an anatomical femoral tunnel placement. *Am J Sports Med*. 2004;32(8):1825-1832.
63. Yasuda K, Kondo E, Ichiyama H, et al. Clinical evaluation of anatomic double-bundle anterior cruciate ligament reconstruction procedure using hamstring tendon grafts: comparisons among 3 different procedures. *Arthroscopy*. 2006;22(3):240-251.
64. Zantop T, Herbert M, Raschke MJ, et al. The role of the anteromedial and posterolateral bundles of the anterior cruciate ligament in anterior tibial translation and internal rotation. *Am J Sports Med*. 2007;35(2):223-227.
65. Zantop T, Wellmann M, Fu FH, et al. Tunnel positioning of anteromedial and posterolateral bundles in anatomic anterior cruciate ligament reconstruction: anatomic and radiographic findings. *Am J Sports Med*. 2008;36(1):65-72.
66. Zelle BA, Brucker PU, Feng MT, et al. Anatomical double-bundle anterior cruciate ligament reconstruction. *Sports Med*. 2006;36(2):99-108.
67. Zelle BA, Vidal AF, Brucker PU, et al. Double-bundle reconstruction of the anterior cruciate ligament: anatomic and biomechanical rationale. *J Am Acad Orthop Surg*. 2007;15(2):87-96.
68. Zhao J, Peng X, He Y, et al. Two-bundle anterior cruciate ligament reconstruction with 8-stranded hamstring tendons: 4-tunnel technique. *Knee*. 2006;13(1):36-41.