



# An interesting case of pulmonary infiltrates with eosinophilia: out of sight out of mind

Amit Panjwani<sup>1,2</sup>, Mohamed Redha Salman<sup>1</sup> and Umesh Nabar<sup>3</sup>

<sup>1</sup>Department of Internal Medicine (Respiratory Unit), Government Hospitals-Salmaniya Medical Complex, Manama, Kingdom of Bahrain. <sup>2</sup>Department of Medicine, Royal College of Surgeons in Ireland, Medical University of Bahrain, Busaiteen, Kingdom of Bahrain. <sup>3</sup>Department of Radiology, Government Hospitals-Salmaniya Medical Complex, Manama, Kingdom of Bahrain.

Corresponding author: Amit Panjwani (drameetp@gmail.com)



Shareable abstract (@ERSpublications)

**Tropical pulmonary eosinophilia should be considered in patients presenting with respiratory symptoms and hypereosinophilia, even in areas not endemic for filariasis. This awareness may prevent morbidity associated with its late or wrong diagnosis.** <https://bit.ly/3t8hHVc>

**Cite this article as:** Panjwani A, Salman MR, Nabar U. An interesting case of pulmonary infiltrates with eosinophilia: out of sight out of mind. *Breathe* 2023; 19: 230097 [DOI: 10.1183/20734735.0097-2023].

Copyright ©ERS 2023

*Breathe* articles are open access and distributed under the terms of the Creative Commons Attribution Non-Commercial Licence 4.0.

Received: 25 April 2023  
Accepted: 18 Sept 2023

A 33-year-old Indian male, working as a labourer, who was employed for the three previous months in the Kingdom of Bahrain, presented with progressive exertional dyspnoea, productive cough with mucoid expectoration and wheeze for the previous 4 weeks. He had no comorbidities and was not on any medication. There was no history of atopy. He had no illicit drug use and was a nonsmoker. Physical examination revealed a pulse rate of 120 beats per min, blood pressure 118/78 mmHg and respiratory rate of 24 breaths per min. He was afebrile and pulse oximetry was 94% on ambient air. Systemic examination was unremarkable except for rhonchi and crepitations that were heard bilaterally on respiratory examination. Complete blood counts showed haemoglobin 13.9 g%, leukocytosis (total 24 280 cells per mm<sup>3</sup>, differential: neutrophils 40%, lymphocytes 16%, monocytes 4%, eosinophils 40%), absolute eosinophil count 9660 cells per mm<sup>3</sup>, platelets 386 000 per mm<sup>3</sup>. A peripheral blood film revealed marked eosinophilia. The biochemical profile was normal, C-reactive protein 2.26 mg·L<sup>-1</sup> (range: 0–3 mg·L<sup>-1</sup>). Stool for ova and parasites (3 samples) were negative. Serum immunoglobulin E (IgE) was 5000 IU·mL<sup>-1</sup> (range: <100 IU·mL<sup>-1</sup>), antineutrophil antibodies were negative, anti-myeloperoxidase 0.2 IU·mL<sup>-1</sup> (negative) and anti-proteinase 3 0.3 IU·L<sup>-1</sup> (negative). A chest radiograph was performed (figure 1).

## Task 1

Describe the findings on the chest radiograph (figure 1).

[Go to Answers >>](#)

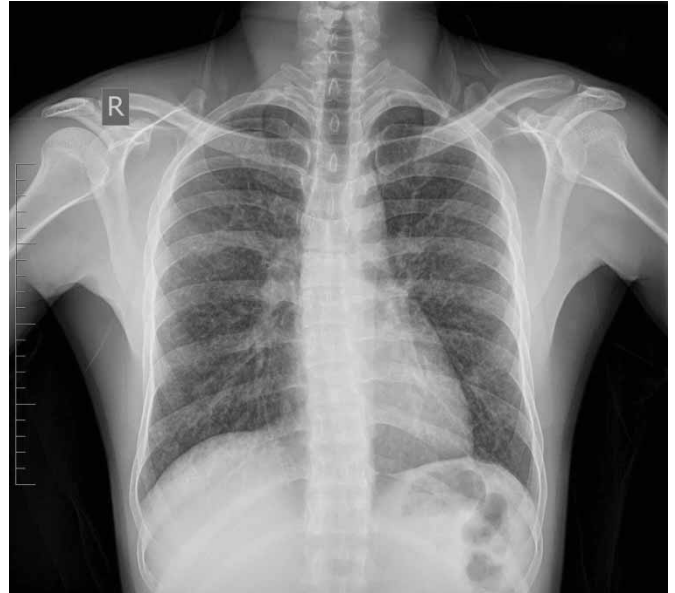A sputum smear for acid-fast bacilli was negative (3 samples), sputum culture for acid-fast bacilli was negative (after 6 weeks), and analysis of sputum using real-time PCR for *Mycobacterium tuberculosis* was negative. Peripheral blood for microfilariae was negative. Spirometry revealed forced expiratory volume in 1 s (FEV<sub>1</sub>)/forced vital capacity (FVC) of 85%, FVC of 2.34 L (55% predicted), FEV<sub>1</sub> of 2.00 L (55.6% predicted) and was suggestive of a restrictive ventilatory defect. High-resolution computed tomography (HRCT) of the chest was performed (figure 2).

## Task 2

Describe the findings on HRCT of the chest.

[Go to Answers >>](#)





**FIGURE 1** Chest radiograph.

### Task 3

What is the most likely diagnosis for this clinical profile?

- a) Löffler syndrome
- b) Tropical pulmonary eosinophilia (TPE)
- c) Eosinophilic granulomatosis with polyangiitis (EGPA)
- d) Hypereosinophilic syndrome (HES)
- e) Chronic eosinophilic pneumonia (CEP)

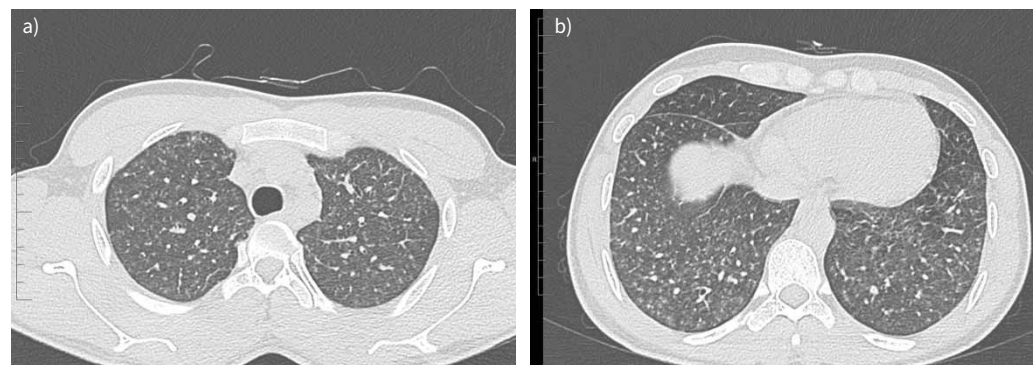
[Go to Answers >>](#)

### Task 4

How can the diagnosis be confirmed?

[Go to Answers >>](#)

The patient was considered for treatment with diethylcarbamazine (DEC). Unfortunately, DEC was not available in the Kingdom of Bahrain and he was therefore treated with a 6-week course of doxycycline (200 mg daily) and prednisolone 20 mg daily for 2 weeks. He showed a good response to treatment with



**FIGURE 2** a, b) High-resolution computed tomography (HRCT) of the chest, axial images.

complete resolution of his cough, dyspnoea and wheeze along with disappearance of adventitious sounds on chest examination and absolute eosinophil count reducing to 530 cells per mm<sup>3</sup>.

### Discussion

It was in the late 19th century that Paul Ehrlich first described eosinophils and about half a century later Reeder and Goodrich introduced the term “PIE syndromes” (pulmonary infiltrates with eosinophilia). Around the same time, Crofton and co-workers classified PIE into five sub-groups: simple pulmonary eosinophilia; prolonged pulmonary eosinophilia; pulmonary eosinophilia with asthma; TPE; and polyarteritis nodosa [1]. In the 21st century, the differential diagnosis of PIE includes asthma, allergic bronchopulmonary aspergillosis, EGPA, HES, parasitic infections, acute eosinophilic pneumonia, CEP, reactions to drugs or toxins and hypereosinophilic obliterative bronchiolitis [2]. The approach to PIE is similar to other respiratory disorders where the importance of a proper history, adequate clinical examination and appropriate analysis of imaging findings cannot be overestimated. It helps in early diagnosis and initiation of correct treatment that goes a long way in curtailing the morbidity and mortality associated with these conditions. This patient presenting with PIE in Bahrain was diagnosed as TPE, an entity that is uncommon in this part of the world. TPE, chronic lymphatic obstructive pathology (e.g. elephantiasis), filarial fevers, asymptomatic microfilaraemia and possible cryptic infection in endemic “normals” are five types of clinical manifestations in the spectrum of human lymphatic filarial infection. Lymphatic filariasis is endemic in two countries in the the Middle East and North Africa region (Egypt and Yemen) with small regions of infection persisting in Djibouti and Saudi Arabia [3]. TPE is common and easily diagnosed in filarial endemic areas like the Indian subcontinent, tropical and sub-tropical regions of Africa, Asia, South America and Oceania. In non-endemic areas, lack of awareness of its presence may result in misdiagnosis or delayed diagnosis resulting in increasing morbidity [4, 5]. We believe that this is the first reported case of TPE from the Kingdom of Bahrain.

TPE is understood to be a hypersensitivity reaction to microfilariae released from *Wuchereria bancrofti* and *Brugia malayi*. The adult worm inhabits the lymphatics and causes lymphatic obstruction. Microfilariae are opsonised by antifilarial antibodies and are then cleared in pulmonary vasculature. The earlier stage of disease is characterised by alveolitis with significant eosinophilic exudate. Severe disease may show microabscesses and granulomas. As time goes by, in the first couple of years, a mixed inflammatory exudate replaces eosinophilic infiltration and fibrosis starts to set in. More than 2 years later, fibrosis becomes the predominant feature with cellularity becoming sparse. It is thought that chronic filarial exposure in endemic areas results in immunity and less to no inflammatory reaction, while susceptible individuals in non-endemic areas may develop a heightened immunological reaction on exposure to these parasites causing significant inflammation [6]. The natural history of the disease coincides with the above-mentioned pathological features. Acute eosinophilic alveolar exudates cause cough, dyspnoea and wheezing. Wheezing occurs due to bronchospasm, bronchial mucosal infiltration with eosinophils and oedema, and bronchiolar obstruction secondary to mucosal shedding and eosinophil clumps. The mixed inflammatory phase seen between 6 months and 2 years is associated with persistent exertional dyspnoea rather than the episodic dyspnoea experienced by the patient in first 3 months of illness. Spirometry shows a restrictive defect and peripheral eosinophilia is present. Beyond 2 years, pulmonary fibrosis resulting in significant dyspnoea is a predominant feature. The eosinophilia wanes away and may resolve completely. Fortunately, due to patchy lung fibrosis, disability associated with this disease is not as bad as that seen in interstitial lung diseases [7]. Chest radiography is abnormal in more than 80% of cases. Reticulonodular opacities and miliary nodules predominantly in the mid and lower zones are the usual findings and these may make differentiation from miliary tuberculosis a daunting task [8]. HRCT usually confirms the radiographic findings of interstitial abnormalities, miliary nodules and may show bronchiectasis, lymphadenopathy and pleural effusions [9]. Spirometry reveals a restrictive defect in more than two-thirds of cases, while the remaining cases may show a mixed pattern [7]. There are no international guidelines or consortia agreements on diagnostic criteria for TPE. However, the generally agreed criteria include: history of spending time in an area endemic for filariasis; peripheral blood eosinophilia >3000 cells per mm<sup>3</sup>; serum IgE >1000 IU·mL<sup>-1</sup>; presence of antifilarial antibodies; and a good response to antifilarial treatment, usually DEC [10]. Our patient fulfilled all these criteria except the last one, due to non-availability of DEC. Interestingly, a sizable proportion of cases may not respond to DEC; therefore, this criterion is not mandatory for diagnosis [6]. Marked elevation of antifilarial antibodies is a common feature while microfilariae are absent more often than not. This may be due to a hyperimmune response, rapid opsonisation and clearance from pulmonary circulation [11]. Treatment with DEC at a dose of 6 mg·kg<sup>-1</sup>·day<sup>-1</sup> in three doses for 2–3 weeks is found to be useful, although longer durations of 4 weeks may be better [7]. Steroids in addition to DEC may be useful in TPE for achieving a better control of inflammation and oxidative stress, in addition to having a potent anti-eosinophilic action by promoting increased apoptosis and inhibiting their degranulation. Some studies have used prednisolone for a duration

of a few weeks to a couple of months, however the exact dose and duration is yet to be confirmed by clinical trials [12]. *Wolbachia*, an endosymbiotic bacterium of the order Rickettsiales, is present in arthropods. There is a symbiotic relationship between *Wolbachia* and filarial worms that is responsible for the filarial worms' development, embryogenesis, fertility and viability [13]. Tetracyclines (doxycycline and minocycline) are known to have an action against rickettsiae and therefore have been used against these novel targets. Field studies have shown that doxycycline at 200 mg daily for 4–6 weeks eliminates adult worms and also their microfilariae [14, 15]. In non-endemic areas, DEC may not be commercially available and therefore, doxycycline may serve as an alternative in these situations. Our patient was treated with doxycycline due to non-availability of DEC in an island nation. Combination of doxycycline and systemic steroids resulted in a favourable outcome in our patient.

Relapses may occur in a fifth of cases that warrant higher doses of DEC ( $6\text{--}12\text{ mg}\cdot\text{kg}^{-1}\cdot\text{day}^{-1}$ ) to be given for a longer period of time (up to a month). One-quarter of cases of TPE develop chronic respiratory insufficiency that may manifest as persistent inflammation of the respiratory tract and interstitial lung disease. ~30% of TPE cases are truly DEC-resistant and may respond to ivermectin and other antihelminthic treatments.

TPE is a rare variant of human lymphatic filarial infection affecting <1% of cases. Several cases of TPE have been reported from non-endemic areas due to travellers and expatriates spending time in and returning from endemic regions. It should be considered in these patients presenting with respiratory symptoms and hypereosinophilia. It may be misdiagnosed as asthma due to the overlapping symptoms of cough, dyspnoea and wheeze. Early diagnosis and prompt appropriate treatment may prevent increased morbidity.

### Answer 1

The chest radiograph was carried out on the day of admission. It is a posterior to anterior view. The visualised lung fields show widespread faint nodules in all zones bilaterally that are more prominent in mid and lower zones.

<< Go to Task 1

### Answer 2

HRCT of the chest revealed bilateral ill-defined nodules in a broncho-centric distribution, more prominent in the lower lobes. Ground-glass opacities were also seen in both lungs.

<< Go to Task 2

### Answer 3

b. The most likely diagnosis is TPE. Löffler syndrome, also known as simple pulmonary eosinophilia, is a common condition causing eosinophilia worldwide. In these cases, pulmonary infiltrates and eosinophilia are thought to be a consequence of pulmonary migration of larvae of *Ascaris lumbricoides*, hookworm and *Strongyloides stercoralis*. Patients may be asymptomatic or have mild dry cough, wheeze and fever that is usually self-limiting and resolves within 2–4 weeks, even without treatment. Chest radiography reveals peripheral and pleural based opacities that may be migratory. Multiple stool examinations increase the yield of diagnosis (almost 100% sensitivity) and in this case Löffler syndrome is unlikely as stool examinations for ova and parasites were negative. EGPA is a rare small vessel vasculitis occurring in the fifth decade of life and is usually associated with a longstanding diagnosis of asthma in an overwhelming majority of cases. Patients usually have other manifestations like upper respiratory involvement (allergic rhinitis, chronic sinusitis and polyposis), peripheral neuropathy and purpuric rashes. Antineutrophil cytoplasmic antibodies, especially the ones with a perinuclear staining pattern directed against myeloperoxidase, are seen in up to 60% cases. Our patient does not have asthma or extrapulmonary features. Antineutrophil cytoplasmic antibodies were also negative. Absence of these features make EGPA less likely. HES is associated with a persistently elevated eosinophil count of  $>1500\text{ cells per mm}^{-3}$  for at least 6 months along with organ dysfunction and exclusion of other common causes of eosinophilia (e.g. allergy or infection). Clinical manifestations are respiratory (in around 40% cases), gastrointestinal, dermatological and in small numbers, cardiac (up to 20% cases) involvement. HRCT of the chest reveals parenchymal infiltrates along with pleural effusion and lymphadenopathy. Our patient did not fulfil the criteria of HES and therefore, it can be safely ruled out. CEP is a rare disease characterised by accumulation of large amounts of eosinophils in the lungs and in peripheral blood, it predominantly affects women and non-smokers. Around 50% of CEP cases have asthma or atopy. It presents with sub-acute respiratory symptoms and a chest radiograph that shows opacities described as the “photographic negative of pulmonary oedema”. HRCT reveals peripheral ground-glass opacities or consolidation with an upper lobe predominance. Our patient did not have these features and thus CEP can also be excluded. This leaves us with a strong likelihood of TPE.

<< Go to Task 3

**Answer 4**

TPE can be confirmed by significant elevations of filarial antibody titres. In this case, the antifilarial antibody titre was markedly elevated (83 units; normal <10 units). Serological tests for filariasis may sometimes cross-react with antigens of other helminths. An ELISA that detects Og4C3 antigen helps in diagnosing *Wuchereria bancrofti* infections, while detection of antibodies against *Bm-SXP-1* helps in diagnosing *Brugia malayi* infections. Pending the commercial availability of a highly specific and sensitive serological test, there is a well-developed criteria, as discussed later, that is agreed by most to be useful in establishing the diagnosis of TPE.

<< Go to Task 4

Conflict of interest: The authors have nothing to disclose.

**References**

- 1 Meeker DP. Pulmonary infiltrates and eosinophilia revisited. *Cleve Clin J Med* 1989; 56: 199–211.
- 2 Piggott LM, Gill CM, Kent BD. Differential diagnosis of pulmonary eosinophilia. In: Jackson DJ, Wechsler ME, eds. *Eosinophilic Lung Diseases (ERS Monograph)*. Sheffield, European Respiratory Society, 2022; pp. 19–36.
- 3 Hotez PJ, Savioli L, Fenwick A. Neglected tropical diseases of the middle east and north Africa: review of their prevalence, distribution, and opportunities for control. *PLoS Negl Trop Dis* 2012; 6: e1475.
- 4 Boggild AK, Keystone JS, Kain KC. Tropical pulmonary eosinophilia: a case series in a setting of non-endemicity. *Clin Infect Dis* 2004; 39: 1123–1128.
- 5 Yong MK, Marshall CL, Eisen DP. Tropical pulmonary eosinophilia: a rare cause of cough in immigrants to Australia. *Med J Aust* 2007; 187: 416–418.
- 6 Ong RK, Doyle RL. Tropical pulmonary eosinophilia. *Chest* 1998; 113: 1673–1679.
- 7 Mullerpattan JB, Udawadia ZF, Udawadia FE. Tropical pulmonary eosinophilia – a review. *Ind J Med Res* 2013; 138: 295–302.
- 8 Khoo FY, Danaraj TJ. The roentgenographic appearance of eosinophilic lung. *Am J Roentgenol Radium Ther Nucl Med* 1960; 83: 251–259.
- 9 Sandhu M, Mukhopadhyay S, Sharma SK. Tropical pulmonary eosinophilia: a comparative evaluation of plain chest radiography and computed tomography. *Australas Radiol* 1996; 40: 32–37.
- 10 Simmons RP, Dudzinski DM, Shepard JO, et al. Case 16-2019: a 53-year-old man with cough and eosinophilia. *N Engl J Med* 2019; 380: 2052–2059.
- 11 Ottesen EA, Nutman TB. Tropical pulmonary eosinophilia. *Annu Rev Med* 1992; 43: 417–424.
- 12 Madan M, Gupta P, Mittal R, et al. Tropical pulmonary eosinophilia: effect of addition of corticosteroids after failure of diethylcarbamazine therapy. *Adv Respir Med* 2017; 85: 51–54.
- 13 Fordjour FA, Kwarteng A. The filarial and the antibiotics: single or combination therapy using antibiotics for filariasis. *Front Cell Infect Microbiol* 2022; 12: 1044412.
- 14 Kwarteng A, Ahuno ST, Akoto FO. Killing filarial nematode parasites: role of treatment options and host immune response. *Infect Dis Poverty* 2016; 5: 86.
- 15 Debrah AY, Mand S, Marfo-Debrekyei Y, et al. Macrofilaricidal effect of 4 weeks of treatment with doxycycline on *Wuchereria bancrofti*. *Trop Med Int Health* 2007; 12: 1433–1441.