

EUS-guided drainage of pancreatic fluid collection with a Hot AXIOS stent in a patient with pancreatitis following distal pancreatectomy (with video)

Lianyong Li, Sarah Cristofaro¹, Changmin Qu, Shuwen Liang, Xiaoyu Li², Qiang Cai³

Department of Gastroenterology, 306th Hospital of PLA, Beijing, ²Department of Gastroenterology, The Affiliated Hospital of Qingdao University, Qingdao, China; ¹Department of Medicine, Division of Digestive Diseases, Emory University School of Medicine, Atlanta, GA, USA

The Hot AXIOS lumen-apposing stent (Xlumena Inc., Mountain View, CA, USA) is a novel double-flanged or “barbell-shaped,” covered, self-expanding metal stent that can be an efficient tool for the drainage of pancreatic fluid collection (PFC), which is mostly caused by gallstone disease, or alcoholic, idiopathic, or chronic pancreatitis.^[1-5] Herein, we present a case of successful PFC drainage in a patient with pancreatitis following distal pancreatectomy [Video 1].

A 59-year-old woman presented with epigastric pain and nausea. She was diagnosed with pancreatitis 4 months after undergoing a distal pancreatectomy and splenectomy because of pancreatic cancer. An upper ultrasound revealed a normal esophagus. An extrinsic compression was found in the body of the stomach and antrum, along with hypertensive portal gastropathy throughout the stomach. A very careful examination performed with a 7.5 MHz linear echoendoscope revealed a large

oval pseudocyst in the body of the pancreas. The pseudocyst measured 120 mm along the long axis and was anechoic on ultrasound. A small amount of layering debris was observed near the bottom of the cyst. Cystogastrostomy was performed with a 15 mm × 10 mm cautery-enhanced lumen-apposing metal stent. Immediately after stent deployment, a copious amount of dark fluid, approximately 1000 ml, drained from the cyst. The stent remained in an excellent position along the posterior wall of the body of the stomach. No unexpected events occurred. Sixty days later, the metal stent was removed using a snare, without difficulty. The pre- and post-drainage computed tomography images are shown in Figure 1.

The findings of this case indicate that EUS-guided cystogastrostomy with a Hot AXIOS stent is safe and effective in the setting of pancreatitis associated with pancreatic surgery.

Video available on: www.eusjournal.com

Access this article online

Quick Response Code:



Website:

www.eusjournal.com

DOI:

10.4103/eus.eus_55_17

This is an open access journal, and articles are distributed under the terms of the Creative Commons Attribution-NonCommercial-ShareAlike 4.0 License, which allows others to remix, tweak, and build upon the work non-commercially, as long as appropriate credit is given and the new creations are licensed under the identical terms.

For reprints contact: reprints@medknow.com

How to cite this article: Li L, Cristofaro S, Qu C, Liang S, Li X, Cai Q. EUS-guided drainage of pancreatic fluid collection with a Hot AXIOS stent in a patient with pancreatitis following distal pancreatectomy (with video). *Endosc Ultrasound* 2018;7:347-8.

Address for correspondence

Dr. Qiang Cai, Department of Medicine, Division of Digestive Diseases, Emory University School of Medicine, Atlanta, GA, USA.
E-mail: qcai@emory.edu

Received: 2017-02-17; Accepted: 2017-07-03; Published online: 2018-05-28

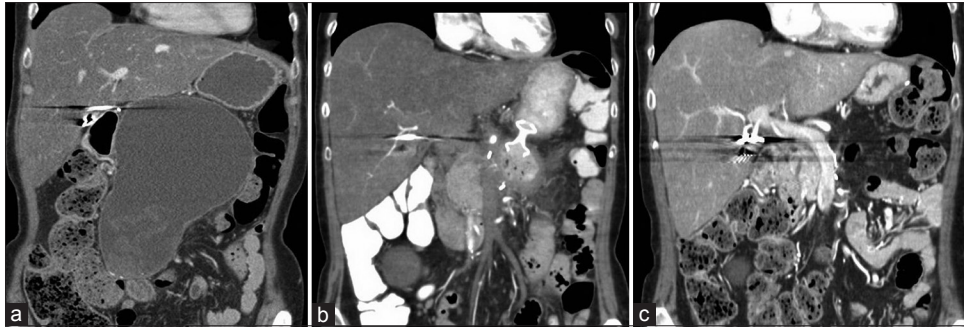


Figure 1. Computed tomography images obtained before and after drainage. (a) Large cyst before cystogastrostomy. (b) Stent is still in place, and the cyst size is decreased. (c) Stent was removed after cyst resolution

Declaration of patient consent

The authors certify that they have obtained all appropriate patient consent forms. In the form, the patient has provided consent for submission of her images and other clinical information required for publication in the journal. The patient understands that her name and initials will not be published and due efforts will be made to conceal her identity but anonymity cannot be guaranteed.

Financial support and sponsorship

None.

Conflicts of interest

There are no conflicts of interest.

REFERENCES

1. Itoi T, Binmoeller KF, Shah J, et al. Clinical evaluation of a novel lumen-apposing metal stent for endosonography-guided pancreatic pseudocyst and gallbladder drainage (with videos). *Gastrointest Endosc* 2012;75:8706.
2. Binmoeller KF, Smith I, Gaidhane M, et al. Akit for EUS-guided access and drainage of pancreatic pseudocysts: Efficacy in a porcine model. *Endosc Ultrasound* 2012;1:13742.
3. Shah RJ, Shah JN, Waxman I, et al. Safety and efficacy of endoscopic ultrasound-guided drainage of pancreatic fluid collections with lumen-apposing covered self-expanding metal stents. *Clin Gastroenterol Hepatol* 2015;13:74752.
4. Rinninella E, Kunda R, Dollhopf M, et al. EUS-guided drainage of pancreatic fluid collections using a novel lumen-apposing metal stent on an electrocautery-enhanced delivery system: A large retrospective study (with video). *Gastrointest Endosc* 2015;82:103946.
5. Patil R, Ona MA, Papafragkakis C, et al. Endoscopic ultrasound-guided placement of AXIOS stent for drainage of pancreatic fluid collections. *Ann Gastroenterol* 2016;29:16873.