



Efficacy and Safety of Porcine Collagen Filler for Nasolabial Fold Correction in Asians: A Prospective Multicenter, 12 Months Follow-up Study

Jung Ho Lee, Yong Sung Choi,
Sue Min Kim, Young Jin Kim,
Jong Won Rhie, and Young Joon Jun

Department of Plastic and Reconstructive Surgery,
The Catholic University of Korea, Seoul, Korea

Received: 6 June 2014
Accepted: 28 July 2014

Address for Correspondence:
Young Joon Jun, MD
Department of Plastic Surgery, The Catholic University of Korea,
Bucheon St. Mary's Hospital, 327 Sosa-ro 327-beon-gil,
Wonmi-gu, Bucheon 420-717, Korea
Tel: +82.32-340-7062, Fax: +82.32-340-7062
E-mail: joony@catholic.ac.kr

Funding: This study was sponsored by SewonCellontech who provided TheraFill® and KOKEN® products.

Recently, injectable dermal fillers have become important alternatives to surgical procedures for the correction of facial wrinkles. Bovine collagen is the first approved material for filler injection, and several studies have shown its efficacy. However, the risk of developing an allergic reaction and xenogenic transmission of bovine spongiform encephalopathy remain among its disadvantages. In this randomized, double-blinded, split-face study, we compared the efficacy and safety of a porcine collagen filler (TheraFill®) with that of a bovine collagen filler (KOKEN®) for nasolabial fold correction. A total of sixty one patients with mild to severe nasolabial fold were randomized to receive TheraFill® and KOKEN® on contralateral sides of the face. During the 12-month follow-up period, improvement in the Wrinkle-Severity Rating Scale score was slightly higher in TheraFill® group than KOKEN® group, although the difference was not statistically significant. No serious adverse reactions were observed and both materials were tolerable in most cases. In conclusion, the long-term effect of TheraFill® on nasolabial fold correction was comparable to that of KOKEN®, and it may be a good alternative to bovine collagen filler.

Keywords: Nasolabial Fold; Bovine Collagen; Porcine Collagen; Filler

INTRODUCTION

With aging, the skin undergoes several changes (1). The collagen production by fibroblasts decreases over time, and this causes thinning of the dermal layer and flattened rete ridges. Dermal elastin and glycosaminoglycans become altered and elasticity diminishes. Subcutaneous tissue diminishes in some areas, especially the face, shins, hands, and feet. As a consequence of these processes facial wrinkles including the nasolabial fold deepens and repetitive movement of facial muscles aggravates these processes.

Because of development of modern medicine, the life expectancy has been extending, and the aged population is increasing. Hence, interest in the reversal of the aging process (anti-aging) has gained more popularity, and the demand on improvement of facial wrinkles is also increasing. In Asia, older people are reluctant to undergo surgery because of their cultural background (2, 3). Furthermore, in Asians, face lifts are often not as effective as in Caucasians because of the thicker skin and wider facial skeleton. Hence, nonsurgical procedures such as thread lifting, subcision, fat grafting and filler injection are preferred (4-7). While fat grafting has the advantage of being less immunogenic, tissue harvesting often prolongs recovery time, and oil cyst or fibrous tissue replacement may occur over time (8-10).

Compared with fat grafting, filler injection requires only several minutes, and immediate return to social life is possible.

Collagen is the most abundant protein in the body and the first approved filler material for general use by the Food and Drug Administration (FDA) (11). The first collagen filler was made from bovine dermal collagen. Although its effectiveness for the correction of the various wrinkles including the glabellar line, forehead line, and nasolabial fold has been demonstrated, skin testing prior to treatment is recommended because of the risk of developing an allergic reaction (12). In addition, although there has never been a report of prion disease transmission with the use of bovine collagen filler, it has been suggested that the risk of transmission of bovine particles and prions must be considered (13). TheraFill® (SewonCellontech, Ltd, Seoul, Korea) is a newly developed porcine collagen filler that was approved by the Korea Food and Drug Administration (KFDA) for the correction of facial wrinkles. In a preclinical study, TheraFill® demonstrated no evidence of serious complications such as cytotoxicity, allergic reaction, or genotoxicity. Moreover, it does not require skin testing.

The aim of the present study was to compare the 12-month efficacy and safety of a porcine collagen filler (TheraFill®) with that of a bovine dermal collagen filler (KOKEN®, Koken Co., Ltd., Tokyo, Japan) for nasolabial fold correction.

MATERIALS AND METHODS

Materials

TheraFill® is a 3% gel suspension of porcine collagen Type I plus 0.3% of lidocaine in phosphate-buffered physiologic saline that was delivered in a disposable 1 mL syringe with 27-gauge needle. It is prepared by a process that includes enzymatic digestion to remove the antigenic portion of the molecule, making it immunologically compatible with humans. KOKEN® is a 3.5% gel suspension of bovine collagen that was delivered in a disposable 1 mL syringe.

Subject selection and study design

This randomized, double blinded (subject and evaluator), split-face non-inferiority study was conducted at 2 hospitals (Seoul St. Mary's Hospital and Bucheon St. Mary's Hospital) in Korea. Adult (> 20 yr) subjects of either sex with mild to severe nasolabial folds based on 5-point Wrinkle Severity Rating Scale (WSRS) (none, 1; mild, 2; moderate, 3; severe, 4; extreme, 5) were included. The exclusion criteria were experience of a nasolabial fold correctional procedure such as botulinum toxin injection, filler injection, laser or chemical peeling, or face-lift within 6 months before this study. Subjects with a history of hypersensitivity to injectable collagen, severe allergic reaction, autoimmune disease, and connective tissue disease, and a current skin disease or inflammation in the nasolabial fold area were also excluded. Two treating investigators, one at each hospital, treated the subjects. Before starting the study, they were trained to ensure the use of the same technique. Firstly, a topical anesthetic cream was applied 30 min before the procedure, after which sterile draping was performed using 75% alcohol. Needle was inserted at the lowest part of the nasolabial fold and advanced along the fold. In the highest part of the fold, the triangular depression was corrected using the fan technique, after which the needle was retreated downward and collagen was injected using the linear technique. The needle stayed within the dermal layer, specifically at the mid-dermal level in the upper fold and at the mid- to upper-dermal level in the lower fold. For over-injected or under-injected areas, massage was performed to evenly distribute the collagen. At initial screening, all eligible subjects received a collagen test injection in the dermis to assess their sensitivity to bovine collagen. Subjects who showed hypersensitivity reaction were excluded from this study. Each subject received TheraFill® in one nasolabial fold and KOKEN® on the contralateral side. Treatments were randomly allocated using a computer-generated code. During injection, the subjects were blinded to the treatment by wearing eye shields or concealing the syringe.

The response to the initial injection of either filler was evaluated after 2 weeks, and if the result was considered suboptimal, one "touch-up" treatment was performed to achieve "optimal cosmetic result" (OCR). Subjects were followed up at 3 month

intervals over a 12-month period after OCR achievement.

The 3 evaluating investigators who were unaware of the treatment allocation assessed the efficacy of each filler by reviewing photographs taken at each follow-up. Investigators assessed the efficacy by using the 5-point WSRS. The degree of overall improvement was determined at each visit by the same investigators and the subjects using the Global Aesthetic Improvement Scale (GAIS) (5, very much improved; 4, much improved; 3, improved; 2, no change; 1, worse). The pretreatment photography served as the reference image at each follow-up visit.

Subjects were surveyed about adverse events. They were asked to describe any subjective discomfort that they felt on the site of injection. Injection sites were examined for evidence of edema, erythema, induration, pain, bruise, nodule, infection, or inflammation at every visit. Adverse reactions were kept in record and followed up for changes. If an inflammatory reaction occurred, laboratory tests including immunoglobulin assay were performed at the investigator's discretion.

Statistical analysis

The primary efficacy endpoint was the WSRS score at 12 month post-baseline. The non-inferiority analysis of the within-subject difference from screening in WSRS was performed by constructing the 90% two-sided confidence interval on the within-subject difference between TheraFill® and KOKEN®. If the lower limit of this interval was greater than -0.5, then TheraFill® was considered non-inferior in efficacy to KOKEN®. The secondary efficacy endpoints included followings: 1) WSRS scores at each visit; 2) investigator- and subject-assessed GAIS at each visit. The paired t-test was used to analyze secondary endpoints and a *P* value less than 0.05 was considered to be statistically significant.

Ethics statement

This study was approved by the institutional review board of the Catholic University of Korea (IRB No.: HC08DIMS0056). All subjects provided written consent to participate the study and were informed of the risks and potential benefits of the study.

RESULTS

Subjects demographics

Of the 61 subjects who were treated, 57 subjects (53 females and 4 males) completed 12 months of follow-up. The causes of withdrawal were consent withdrawal (1) and loss to follow-up (3). The mean age of the subjects was 47.2 yr. Regarding age distribution 24 (42.1%), 16 (28.1%), 11 (19.3%), and 6 (10.5%) were in their forties, fifties, thirties, and sixties, respectively.

Efficacy

The mean volume of the filler did not significantly differ between

the groups: 2.11 ± 0.60 mL in the TheraFill® group and 2.17 ± 0.43 mL in the KOKEN® group. The mean WSRS scores before

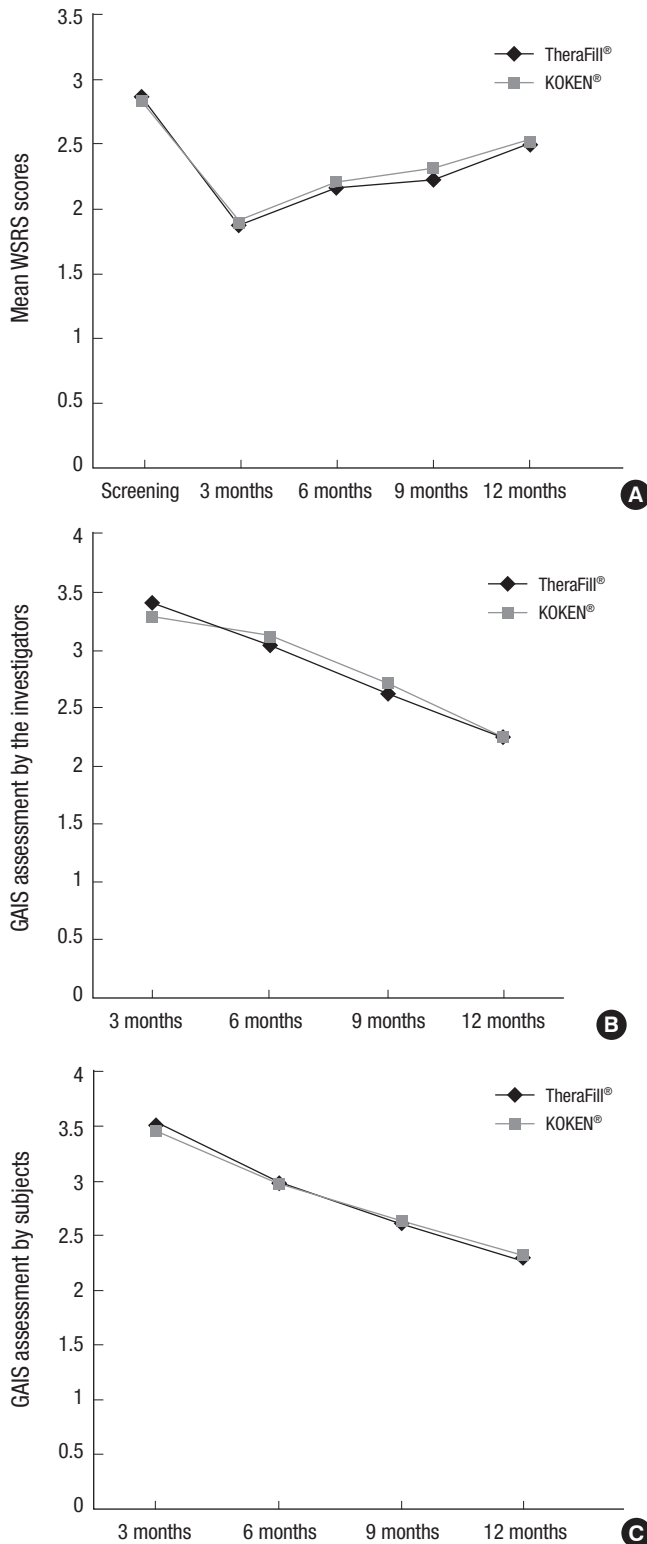


Fig. 1. (A) Wrinkle-Severity Rating Scale (WSRS) scores over a 12-month period after injection. (B) Investigator-assessed Global Aesthetic Improvement Scale (GAIS) scores over a 12-month period after injection. (C) Subject-assessed Global Aesthetic Improvement Scale (GAIS) scores over 12-month period after injection.

treatment were 2.89 ± 0.7 in the TheraFill® group, and 2.84 ± 0.7 in the KOKEN® group ($P = 0.322$). At each follow-up, the mean WSRS scores were 1.88 ± 0.84 (3 months), 2.16 ± 0.7 (6 months), 2.23 ± 0.66 (9 months), and 2.51 ± 0.71 (12 months) in the TheraFill® group. For the KOKEN® group, the score were 1.90 ± 0.97 (3 months), 2.21 ± 0.67 (6 months), 2.32 ± 0.60 (9 months) and 2.52 ± 0.60 (12 months) (Fig. 1A). The lower limit of the two-sided 90% confidence interval was -0.0312 , which was above the predefined margin for non-inferiority (-0.05). This indicates that the efficacy of TheraFill® at 12 month post-baseline was comparable to that of KOKEN®. Although, there was a slightly higher improvement in WSRS scores in the TheraFill® group at each follow up, the difference between both groups was not statistically significant. Regarding the GAIS assessment by the investigators, the mean scores at each follow up were 3.42 ± 0.63 (3 months), 3.05 ± 0.85 (6 months), 2.63 ± 0.82 (9 months), and 2.28 ± 0.82 (12 months) in the TheraFill® group and 3.3 ± 0.76 (3 months), 3.11 ± 0.84 (6 months), 2.72 ± 0.82 (9 months), and 2.26 ± 0.84 (12 months) in the KOKEN® group (Fig. 1B). GAIS assessment by subjects showed that the mean scores were 3.54 ± 0.83 (3 months), 2.98 ± 0.92 (6 months), 2.61 ± 0.88 (9 months), and 2.28 ± 0.67 (12 months) in the TheraFill® group and 3.47 ± 0.95 (3 months), 2.98 ± 0.88 (6 months), 2.65 ± 0.81 (9 months), and 2.33 ± 0.81 (12 months) in the KOKEN® group (Fig. 1C). The mean GAIS score decreased significantly from 6 months in both groups ($P < 0.001$). There was no significant difference between the 2 fillers at any of these time points. Serial photographic images of the nasolabial folds are presented in Fig. 2.

Safety

Both fillers were well tolerated and there were no serious adverse reactions. In the TheraFill® group, swelling at the injection site occurred in 1 subject. In the KOKEN® group, 5 adverse reactions occurred in 3 subjects and swelling ($n = 3$) was the most common local side effect, followed by erythema ($n = 1$), and nodule ($n = 1$). All of the side effects were mild in intensity, and were resolved without sequelae.

DISCUSSION

During a lifetime, structural proteins in the skin undergo changes. With aging, the collagen production by fibroblasts is decreased and the collagen bundles are fragmented. The level of collagenase is increased by ultraviolet radiation and degradation of collagen is fastened. As a consequence of these changes, dermal thickness in aged skin is decreased by 20% (14, 15).

Reversal of the skin aging process by soft tissue augmentation has been of great interest to physicians as well as the general population. In particular, because of the collagen defects in aged skin, several studies on collagen as a dermal filler have been per-

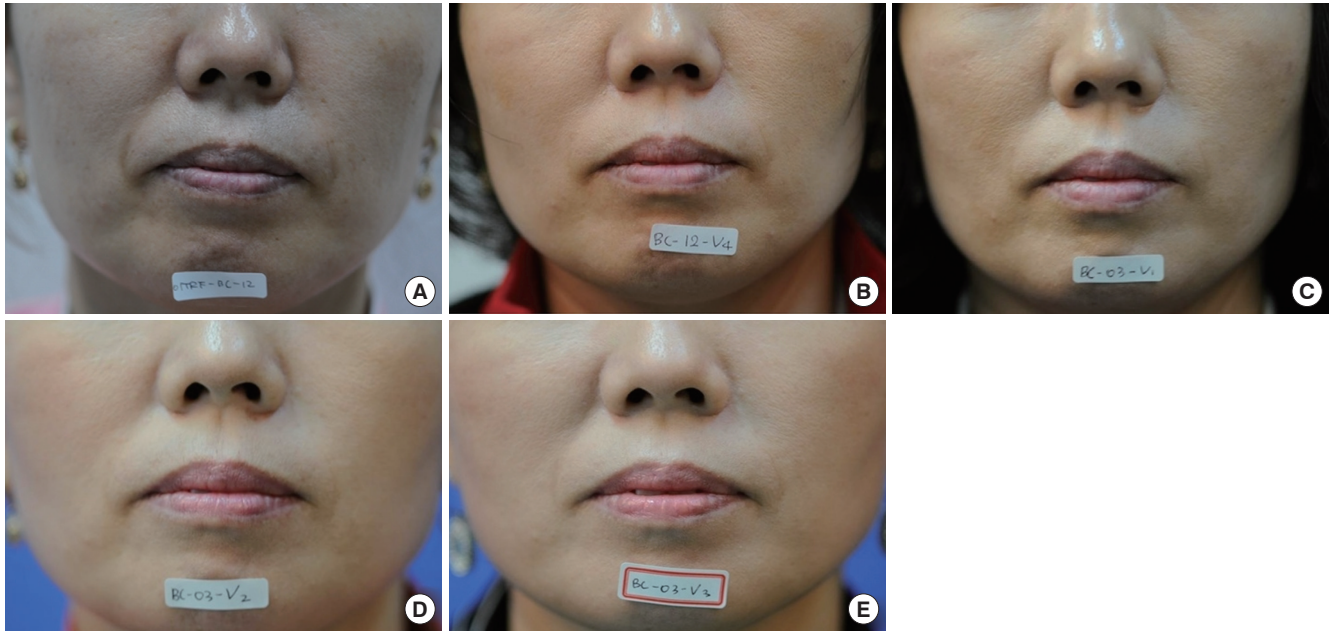


Fig. 2. Photographs of the nasolabial folds of a representative subject. (A) Before treatment; (B) at 3 months after baseline; (C) at 6 months after baseline; (D) at 9 months after baseline; and (E) at 12 months after baseline.

formed (12, 16). Zyderm I® (Allergan, Inc, Irvine, CA, USA) a purified suspension of bovine collagen, was the first dermal filler available for the correction of wrinkles and was approved by the FDA in 1981. It is composed of 3.5% bovine dermal collagen, suspended in physiologic phosphate-buffered sodium chloride solution and 0.3% lidocaine. Since then, Zyderm II® (Allergan, Inc, Irvine, CA), which contains 6.5% bovine dermal collagen, and Zyplast® (Allergan, Inc., Irvine, CA, USA), which contains 3.5% bovine dermal collagen cross linked with 0.0075% glutaraldehyde were approved in 1983 and 1985, respectively. Because collagen fillers are natural and dermal filling with collagen is performed according to the principle of “replace like with like”, bovine collagen came to be regarded as the “gold standard” among injectable fillers (17). However, immunogenicity and potential hypersensitivity reactions have decreased the popularity of bovine collagen fillers. It has been demonstrated that approximately 3%-3.5% of subjects will show sensitivity; therefore, 2 consecutive skin tests are recommended (6 and 2 weeks) prior to treatment (18). In addition, the risk of xenogenic transmission of BSE is not eliminated.

Due to its high biocompatibility with humans, porcine collagen has been used in various clinical fields including abdominal wall surgery, orthopedic surgery, and gynecologic surgery (19-21). Recently, it has been demonstrated that porcine-based dermal collagen filler is effective for the treatment of facial wrinkles including the nasolabial fold and tear-trough deformity (22, 23). In addition, Lorenc et al showed that porcine collagen filler provided a lower extrusion force and yield point compared with hyaluronic acid-based fillers (24). These physical properties of

porcine collagen filler allow clinicians to inject more comfortably and precisely. TheraFill® is a newly developed porcine collagen filler from South Korea. By enzymatic digestion of immunogenic telopeptides, the issues regarding xenogenic allergy are resolved and skin test prior to injection is not needed. Furthermore, patients feel free from xenogenic transmission of BSE. In our study, there were no serious or long-lasting complications including allergic reaction. However, a previous study has reported that Evolence®, a cross-linked porcine-based collagen filler, should not be injected into the lips due to the high incidence of nodule formation (25). For this reason, it seems prudent to investigate the safety of TheraFill® through further studies on other facial areas. Regarding efficacy, the WSRS data of TheraFill® at 12 month post-baseline was comparable to that of KOKEN®. In addition, there was no significant difference in the efficacy of between TheraFill® and KOKEN® during 12 months after the injection. However, regarding durability, GAIS score decreased significantly from 6 month in both groups. This is due to the degradation of natural collagen by in vivo collagenase and is consistent with the results of previous studies, which showed that the majority of subjects require touch-up injections approximately every 3-12 months (26, 27). A previous study has reported that ribose-induced cross linking of porcine collagen prolongs the effect of collagen filler (28). In addition, it has been demonstrated that cross-linked collagen filler has comparable efficacy for treating nasolabial fold to hyaluronic acid based filler (22). Therefore, it seems that further development such as increasing the degree of the cross link or concentration of collagen is needed to improve the current form of TheraFill®.

In conclusion, the long-term effect of TheraFill® on nasolabial fold correction was comparable to that of the bovine collagen filler. Regarding safety, it was tolerable in most cases, and there was no serious adverse reaction. Therefore, TheraFill® may be a good alternative to bovine collagen fillers. Further studies are needed to compare its safety and efficacy with those of widely used hyaluronic acid-based filler.

DISCLOSURE

The authors declare no potential conflicts of interest.

ORCID

Jung Ho Lee <http://orcid.org/0000-0002-3800-5494>

Yong Sung Choi <http://orcid.org/0000-0002-6108-758X>

Sue Min Kim <http://orcid.org/0000-0002-0894-5207>

Young Jin Kim <http://orcid.org/0000-0002-9046-9907>

Jong Won Rhie <http://orcid.org/0000-0002-9398-8059>

Young Joon Jun <http://orcid.org/0000-0002-2678-9092>

REFERENCES

- Fenske NA, Lober CW. Structural and functional changes of normal aging skin. *J Am Acad Dermatol* 1986; 15: 571-85.
- Vidal P, Berner JE, Castillo P, Rochefort G, Loubies R. Descended mouth corner: an ignored but needed feature of facial rejuvenation. *Arch Plast Surg* 2013; 40: 783-6.
- Lee JW, Cho BC, Lee KY. Direct brow lift combined with suspension of the orbicularis oculi muscle. *Arch Plast Surg* 2013; 40: 603-9.
- Lee SY, Sung KY. Subcision using a spinal needle cannula and a thread for prominent nasolabial fold correction. *Arch Plast Surg* 2013; 40: 256-8.
- Lee SK, Kim DW, Dhong ES, Park SH, Yoon ES. Facial soft tissue augmentation using autologous fat mixed with stromal vascular fraction. *Arch Plast Surg* 2012; 39: 534-9.
- Salibian AA, Widgerow AD, Abrouk M, Evans GR. Stem cells in plastic surgery: a review of current clinical and translational applications. *Arch Plast Surg* 2013; 40: 666-75.
- Shin KC, Bae TH, Kim WS, Kim HK. Usefulness of gold thread implantation for crow's feet. *Arch Plast Surg* 2012; 39: 42-5.
- Kanchwala SK, Holloway L, Bucky LP. Reliable soft tissue augmentation: a clinical comparison of injectable soft-tissue fillers for facial-volume augmentation. *Ann Plast Surg* 2005; 55: 30-5; discussion 5.
- Kaufman MR, Miller TA, Huang C, Roostaeian J, Wasson KL, Ashley RK, Bradley JP. Autologous fat transfer for facial recontouring: is there science behind the art? *Plast Reconstr Surg* 2007; 119: 2287-96.
- Murray CA, Zloty D, Warshawski L. The evolution of soft tissue fillers in clinical practice. *Dermatol Clin* 2005; 23: 343-63.
- Watson W, Kaye RL, Klein A, Stegman S. Injectable collagen: a clinical overview. *Cutis* 1983; 31: 543-6.
- Baumann L, Kaufman J, Saghari S. Collagen fillers. *Dermatol Ther* 2006; 19: 134-40.
- Andre P, Lowe NJ, Parc A, Clerici TH, Zimmermann U. Adverse reactions to dermal fillers: a review of European experiences. *J Cosmet Laser Ther* 2005; 7: 171-6.
- Lavker RM. Structural alterations in exposed and unexposed aged skin. *J Invest Dermatol* 1979; 73: 59-66.
- Griffiths CE, Russman AN, Majmudar G, Singer RS, Hamilton TA, Voorhees JJ. Restoration of collagen formation in photodamaged human skin by tretinoin (retinoic acid). *N Engl J Med* 1993; 329: 530-5.
- Cockerham K, Hsu VJ. Collagen-based dermal fillers: past, present, future. *Facial Plast Surg* 2009; 25: 106-13.
- Klein AW, Elson ML. The history of substances for soft tissue augmentation. *Dermatol Surg* 2000; 26: 1096-105.
- Downie J, Mao Z, Rachel Lo TW, Barry S, Bock M, Siebert JP, Bowman A, Ayoub A. A double-blind, clinical evaluation of facial augmentation treatments: a comparison of PRI 1, PRI 2, Zyplast and Perlane. *J Plast Reconstr Aesthet Surg* 2009; 62: 1636-43.
- Patel KM, Nahabedian MY, Gatti M, Bhanot P. Indications and outcomes following complex abdominal reconstruction with component separation combined with porcine acellular dermal matrix reinforcement. *Ann Plast Surg* 2012; 69: 394-8.
- Alperin M. Collagen scaffold: a treatment for large mesh exposure following vaginal prolapse repair. *Int Urogynecol J* 2014.
- Giannotti S, Ghilardi M, Dell'osso G, Magistrelli L, Bugelli G, Di Rollo F, Ricci G, Calabrese R, Siciliano G, Guido G. Study of the porcine dermal collagen repair patch in morpho-functional recovery of the rotator cuff after minimum follow-up of 2.5 Years. *Surg Technol Int* 2014; 24: 348-52.
- Narins RS, Brandt FS, Lorenc ZP, Maas CS, Monheit GD, Smith SR. Twelve-month persistency of a novel ribose-cross-linked collagen dermal filler. *Dermatol Surg* 2008; 34: S31-9.
- Goldberg DJ. Correction of tear trough deformity with novel porcine collagen dermal filler (Dermicol-P35). *Aesthet Surg J* 2009; 29: S9-S11.
- Lorenc ZP, Nir E, Azachi M. Characterization of physical properties and histologic evaluation of injectable Dermicol-p35 porcine-collagen dermal filler. *Plast Reconstr Surg* 2010; 125: 1805-13.
- Braun M, Braun S. Nodule formation following lip augmentation using porcine collagen-derived filler. *J Drugs Dermatol* 2008; 7: 579-81.
- Klein AW. Skin filling: Collagen and other injectables of the skin. *Dermatol Clin* 2001; 19: 491-508, ix.
- Narins RS, Brandt F, Leyden J, Lorenc ZP, Rubin M, Smith S. A randomized, double-blind, multicenter comparison of the efficacy and tolerability of Restylane versus Zyplast for the correction of nasolabial folds. *Dermatol Surg* 2003; 29: 588-95.
- Monstrey SJ, Pitaru S, Hamdi M, Van Landuyt K, Blondeel P, Shiri J, Goldlust A, Shoshani D. A two-stage phase I trial of Evolence30 collagen for soft-tissue contour correction. *Plast Reconstr Surg* 2007; 120: 303-11.