

Available online at www.sciencedirect.com

ScienceDirect

journal homepage: www.elsevier.com/locate/radcr

Case report

The radiological presentation of Rasmussen aneurysm secondary to pulmonary tuberculosis and COVID-19: A case report [☆]

Adnan Arif, MBBS^{a,#}, Khurram Khaliq Bhinder, MBBS^{a,#}, Azza Sarfraz, MBBS^{b,^}, Zouina Sarfraz, MBBS^{c,^,*}, Miguel Felix, MD^{d,e}, Ivan Chérrez-Ojeda, MD, MsC^{d,e}

^a Shifa International Hospital, Islamabad, Pakistan

^b Aga Khan University, Karachi, Pakistan

^c Fatima Jinnah Medical University, Lahore, Pakistan

^d Universidad Espíritu Santo, Samborondón, Ecuador

^e Respiralab Research Center, Guayaquil, Ecuador

ARTICLE INFO

Article history:

Received 16 July 2021

Revised 29 July 2021

Accepted 31 July 2021

Available online 6 August 2021

Keywords:

Rasmussen aneurysm

Tuberculosis

COVID-19

Co-infection

Hemoptysis

Interventional radiology

Management

ABSTRACT

Rasmussen aneurysm is rare diagnosis occurring in patients with long-standing tuberculosis. TB-COVID-19 co-infection in the context of Rasmussen aneurysm is a rare occurrence, yet new cases are emerging. An elderly male was recently diagnosed with TB-COVID-19 co-infection and presented with sudden onset massive hemoptysis. The patient was diagnosed with Rasmussen aneurysm after being evaluated by computed tomography pulmonary angiogram due to a suggestive clinical presentation. Interventional radiologists planned for embolization of pulmonary artery, with an unidentifiable source. It was suspected that the patient's source of bleeding was hampered due to local tamponade effect or thrombosis of the aneurysm. The patient remained stable after 24 hours on computed tomography pulmonary angiogram. Our case emphasizes the importance of Rasmussen aneurysm as a differential diagnosis when presented with a TB-COVID-19 co-infection and sudden onset of hemoptysis symptomatically and radiologically. The timely diagnosis and management are key to improve mortality.

© 2021 The Authors. Published by Elsevier Inc. on behalf of University of Washington.

This is an open access article under the CC BY-NC-ND license

(<http://creativecommons.org/licenses/by-nc-nd/4.0/>)

[☆] Competing Interests: All authors declare no conflict of interest.

* Corresponding author.

E-mail address: zouinasarfraz@gmail.com (Z. Sarfraz).

Adnan Arif, MBBS and Khurram Khaliq Bhinder, MBBS have contributed equally as co-first authors.

^ Azza Sarfraz, MBBS and Zouina Sarfraz, MBBS have contributed equally as co-second authors.

<https://doi.org/10.1016/j.radcr.2021.07.088>

1930-0433/© 2021 The Authors. Published by Elsevier Inc. on behalf of University of Washington. This is an open access article under the CC BY-NC-ND license (<http://creativecommons.org/licenses/by-nc-nd/4.0/>)

Background

Rasmussen aneurysm describes an aneurysm occurring in the branch of a peripheral pulmonary artery in patients with tuberculous cavities [1]. The pathologic process thought to cause this condition involves the infiltration of granulation tissue into the adventitia and media, which is later replaced by fibrin, leading to thinning of the vessel wall with subsequent aneurysm formation [2]. In the clinical context, Rasmussen aneurysms can be a cause for massive hemoptysis among patients with tuberculosis, which has an associated mortality ranging from 5% to 25% [3]. Careful evaluation of pre- and postcontrast computed tomography (CT) scans of the lung will demonstrate focal enhancement within the pulmonary aneurysm, which may be one of the first clues in diagnosis [4].

Our aim with this case report is describe a case of Rasmussen aneurysm in a male patient with a history of tuberculosis, COVID-19 pneumonia, and discussing the main implications related to the radiographic evaluation and management.

Case presentation

An 81-year-old-male patient presented on May 16, 2021 with a 3-day history of sudden onset, excessive dry cough. He had a history of smoking, diabetes mellitus, hypertension, and end-stage renal disease requiring hemodialysis. The patient also had a 5-month history (ie, since late December 2020) of tuberculosis-like symptoms of lung which remained undiagnosed, potentially spreading the disease. The elderly male patient was confirmed with COVID-19 in early December 2020 using PCR and HRCT testing. We found that the patient was under a high index of suspicion for latent TB given the high prevalence in Pakistan, hence suggesting latent TB as a possible cause. The patient was finally diagnosed with TB in March 2021 using TB-PCR testing of sputum which showed MTB DNA. The patient was commenced on an anti-tuberculous drug regimen comprising 2 months of isoniazid, rifampin, pyrazinamide, and ethambutol followed by a continuation phase of 4 months of isoniazid and rifampin. During current admission, on subsequent days, the patient developed excessive coughing along with massive hemoptysis at home (roughly 400 mL/day), dizziness and chest pain. The patient was rushed to the emergency department with a Glasgow coma scale (GCS) of 8 of 15 where he had one massive episode of hemoptysis. The initial assessment showed a hemoglobin (HB) of 9 g/dL.

A chest x-ray was performed which showed a cavitating lesion involving the midzone of the right lung, towards the periphery (Fig. 1A). In addition, the patient had a confirmed occurrence of COVID-19 pneumonia, hence, a provisional diagnosis of pulmonary embolism with subsequent infarct was suspected. The patient underwent a CT pulmonary angiogram, which showed a thick-walled pulmonary cavity along the major fissure measuring 2.4 × 2.8 cm (AP X TR), with associated focal dilatation involving the sub-segmental division of the right lower lobe pulmonary artery (Fig. 1B). The lesion was located within the posteromedial aspect of the

thick-walled cavity, suggesting a potential Rasmussen aneurysm. No active contrast extravasation was seen. Additionally, the CT angiogram was consistent with a pulmonary embolism, seen as an eccentric filling defect in the right main pulmonary artery extending into the segmental branches of the right upper lobe (Fig. 1C). A deep venous thrombosis involving the right common femoral vein was also found (Fig. 1D).

A team of interventional radiologists was consulted, and the patient was taken to the angiography suite for embolization of the pulmonary artery to halt the source of bleed. The left common femoral vein approach was used in combination with a pigtail catheter and Glidewire access, into the pulmonary trunk and subsequently to the right pulmonary artery (Fig. 1E). Multiple hand injection runs were done constituting 16.25 mL of total contrast. Selective angiogram in AP and LAO projections did not show any source of bleeding (Fig. 1E). It was assumed that source of bleeding was hampered due to a local tamponade effect or thrombosis of the aneurysm. Embolization was therefore not performed. The patient had a follow-up CT pulmonary angiogram after 24 hours which revealed regression of the Rasmussen aneurysm (Fig. 1F). During this time, no episodes of hemoptysis occurred.

Discussion

Pulmonary TB presents with a variety of symptoms, which are usually insidious in onset and progression. TB-related hemoptysis may occur due to bronchiectasis of the bronchial artery, or rarely due to a Rasmussen aneurysm of a pulmonary artery, as originally described by Fritz Waldemar Rasmussen in 1868 [5]. Pulmonary artery aneurysms are often associated with high mortality and may lead to significant hemoptysis. Infections such as tuberculosis or syphilis are a leading cause of acquired pulmonary artery aneurysms. Rasmussen aneurysms are also caused by local invasion secondary to the tuberculous cavity, which weakens the vessel wall and can develop into a pseudoaneurysm that has an increased risk of rupture. The imaging method of choice to evaluate this condition is a CT pulmonary angiography, where the focal dilatation of the pulmonary artery branches can be visualized using intravenous contrast. However, due to the low incidence, the suspicion of Rasmussen aneurysm is often overlooked by radiologists.

Progressive primary TB involves 4 stages: (1) liquefaction of caseous necrosis, (2) formation of cavities, (3) progressive fibrosis and lung destruction, and (4) bronchogenic spread [6]. Rasmussen aneurysm is an uncommon complication that occurs with chronic cavitary TB. Majority of individuals who contract TB infection are latent carriers (90%-95%) [6]. In our patient, latent TB infection is possible given its burden in Pakistan, ranked 5th highest. Latent TB presents with cavitary lesions as the most common manifestation. While not diagnosed earlier, latent TB is strongly suspected given the recent diagnosis of Rasmussen aneurysm.

Its management is frequently challenging, as the condition of the patients may deteriorate despite appropriate interventions. Typically, the preferred therapeutic option is an endovascular embolization using gelfoam, coils, or plugs [7].

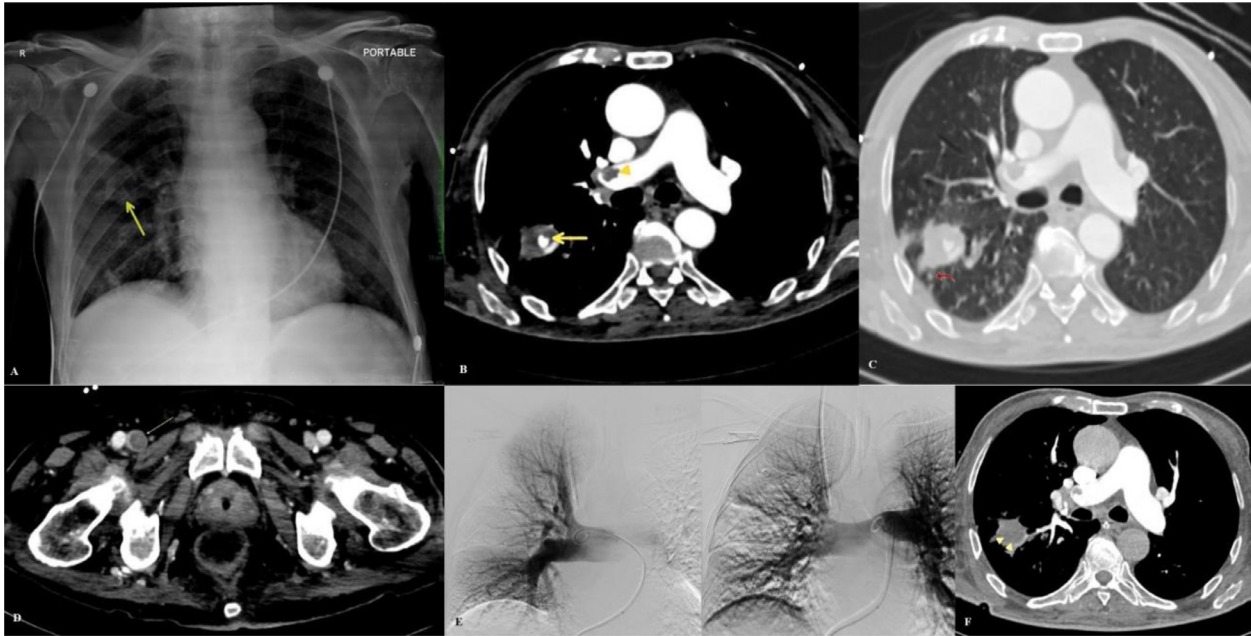


Fig. 1 – An illustration of the radiological findings of the patient during hospitalization.

(A) CXR shows a heterogeneous airspace opacity in the right lung, at the midzone, peripheral location (arrow).

(B) CT Pulmonary angiogram shows a thick walled pulmonary cavity measuring 2.4 × 2.8 cm (AP × TR), containing focally dilated sub-segmental division of the right lower lob pulmonary artery representing Rasmussen aneurysm (arrow). The small filling defect in the right main pulmonary artery represents pulmonary thromboembolism (arrowhead).

(C) Tuberculous infiltrates are seen in the vicinity of the pulmonary cavity (curved arrow).

(D) A filling defect in the right common femoral vein causing its focal distention represents deep venous thrombosis (thin arrow).

(E) Selective angiogram in LAO (right) and AP projection (left) shows adequate contrast opacification of pulmonary arteries without any evidence of contrast pooling or source of bleeding.

(F) CT Pulmonary angiogram after 24 hours (during which, there were no episodes of hemoptysis noted) did not reveal the previously seen focal aneurysmal dilation of the pulmonary artery suggesting spontaneous regression or thrombosis of Rasmussen aneurysm (arrowhead).

The occlusion of the pulmonary aneurysm followed by coiling and embolization is an emergency intervention to prevent mortality as seen in our case. It is important to note that our patient was stabilized and did not deteriorate clinically under observation. Our findings emphasize the importance of including Rasmussen aneurysm as a differential diagnosis when presented with a TB-COVID-19 co-infection and sudden onset of hemoptysis symptomatically and radiologically [5,8]. While the early initiation of anti-TB medications has led to a decreased risk of hypercoagulable state [9], our patient had an advanced age, and risk factors for thromboembolism like decreased mobility, immunocompromised state, and recent COVID-19 infection. In a meta-analysis, COVID-19 was found to directly or indirectly predispose patients to DVT or pulmonary embolism; groups such as the elderly, obese and hospitalized are more likely to contract severe infection along with higher VTE incidences [10]. The timely diagnosis and management is key to reduce the high risk of mortality [7].

To our knowledge, we have reported an exceedingly rare case of Rasmussen aneurysm associated with a recent TB history and with a background of COVID-19. A case report of a 74-year-old male with COVID-19 pneumonitis presents

an upper left lobe pulmonary artery pseudoaneurysm followed by life-threatening hemoptysis; the case was successfully treated with emergency endovascular embolization [11]. We believe that this rare finding is worth noting in TB endemic regions, and we must focus on managing coexisting pulmonary pathologies secondary to COVID-19. Radiologists must recognize that Rasmussen aneurysm may be a rare yet possible complication of TB and COVID-19 and aim to diagnose and intervene early. We recommend an individualized approach with anti-TB and anti-thrombotic treatment, with careful consideration of underlying risks due to pulmonary artery aneurysms.

Conclusion

We described the case of an elderly male with a recent history of TB-COVID-19 co-infection who developed a Rasmussen aneurysm, and was successfully managed. It is pertinent that both clinicians and radiologists consider this clinical disorder with reference to COVID-19 as the co-infection may be aggra-

vating due to the underlying thrombotic state induced by the virus.

Patient consent statement

The patient signed an informed consent form, as per the ethical guidelines of the hospital board.

REFERENCES

- [1] Remy J, Smith M, Lemaitre L, Marache P, Fournier E. Treatment of massive hemoptysis by occlusion of a Rasmussen aneurysm. *AJR Am J Roentgenol* 1980;135(3):605–6 PMID: 6773385. doi:[10.2214/ajr.135.3.605](https://doi.org/10.2214/ajr.135.3.605).
- [2] Syed M, Irby J. Airway management of ruptured pulmonary artery "Rasmussen" aneurysm and massive hemoptysis. *BMC Res Notes* 2015;8:346 PMID: 26264527; PMCID: PMC4534049. doi:[10.1186/s13104-015-1313-7](https://doi.org/10.1186/s13104-015-1313-7).
- [3] Yoon W, Kim JK, Kim YH, Chung TW, Kang HK. Bronchial and nonbronchial systemic artery embolization for life-threatening hemoptysis: a comprehensive review. *Radiographics* 2002;22(6):1395–409 Nov-Dec PMID: 12432111. doi:[10.1148/rg.226015180](https://doi.org/10.1148/rg.226015180).
- [4] Basille D, Andréjak C, Gosset M, Renard C, Jounieaux V. Hémoptysie massive sur anévrisme de Rasmussen [Severe haemoptysis revealing a Rasmussen aneurysm]. *Rev Mal Respir* 2010;27(1):63–6 French Epub 2009 Dec 14. PMID: 20146953. doi:[10.1016/j.rmr.2009.11.009](https://doi.org/10.1016/j.rmr.2009.11.009).
- [5] Giraldo-Montoya AM, Rodríguez-Morales AJ, Hernández-Hurtado JD, López-Salazar Á, Lagos-Grisales GJ, Ruiz-Granada VH. Rasmussen aneurysm: a rare but not gone complication of tuberculosis. *Int J Infect Dis* 2018;69:8–10 Epub 2018 Feb 2. PMID: 29410220. doi:[10.1016/j.ijid.2018.01.023](https://doi.org/10.1016/j.ijid.2018.01.023).
- [6] Shih SY, Tsai IC, Chang YT, Tsan YT, Hu SY. Fatal haemoptysis caused by a ruptured Rasmussen's aneurysm. *Thorax* 2011;66(6):553–4 Epub 2010 Aug 30. PMID: 20805157. doi:[10.1136/thx.2010.135616](https://doi.org/10.1136/thx.2010.135616).
- [7] Khurram R, Karia P, Naidu V, Quddus A, Woo WL, Davies N. Pulmonary artery pseudoaneurysm secondary to COVID-19 treated with endovascular embolisation. *Eur J Radiol Open* 2021;8:100346 Epub 2021 Apr 18. PMID: 33898655; PMCID: PMC8053241. doi:[10.1016/j.ejro.2021.100346](https://doi.org/10.1016/j.ejro.2021.100346).
- [8] Sapra R, Sharma G, Minz AK. Rasmussen's aneurysm: a rare and forgotten cause of hemoptysis. *Indian Heart J* 2015;67(Suppl 3):S53–6 Suppl 3 Epub 2015 Aug 29. PMID: 26995433; PMCID: PMC4798981. doi:[10.1016/j.ihj.2015.07.009](https://doi.org/10.1016/j.ihj.2015.07.009).
- [9] Sapra R, Sharma G, Minz AK. Rasmussen's aneurysm: a rare and forgotten cause of hemoptysis. *Indian Heart J* 2015 Dec;67(Suppl 3):S53–S56 Suppl 3 Epub 2015 Aug 29. PMID: 26995433; PMCID: PMC4798981. doi:[10.1016/j.ihj.2015.07.009](https://doi.org/10.1016/j.ihj.2015.07.009).
- [10] Sarfraz A, Sarfraz Z, Razzack AA, Patel G, Sarfraz M. Venous thromboembolism, corticosteroids and COVID-19: a systematic review and meta-analysis. *Clin Appl Thromb Hemost* 2021;27 1076029621993573 PMID: 33571009; PMCID: PMC7883150. doi:[10.1177/1076029621993573](https://doi.org/10.1177/1076029621993573).
- [11] Khurram R, Karia P, Naidu V, Quddus A, Woo WL, Davies N. Pulmonary artery pseudoaneurysm secondary to COVID-19 treated with endovascular embolisation. *Eur J Radiol Open* 2021;8:100346 Epub 2021 Apr 18. PMID: 33898655; PMCID: PMC8053241. doi:[10.1016/j.ejro.2021.100346](https://doi.org/10.1016/j.ejro.2021.100346).